

MRI Demonstration of Kernohan's Notch

Harjinder Singh Bhatoe M Ch, K K Sen M D* Prakash Singh M Ch, J D Mukherji D M**

Departments of Neurosurgery, *Radiodiagnosis and **Neurology
Army Hospital (R & R), Delhi Cantt 110010

Abstract: Kernohan's notch is one of the commonly described false localizing signs in clinical neurology. The lesion has been clearly demonstrated by MRI and is shown as hyperintense lesion of the cerebral peduncle on T2-weighted images. The lesion is best demonstrated on coronal imaging. We describe the lesion in a 56-year-old male with chronic subdural hematoma. The neurological signs disappeared after evacuation of the SDH.

Keywords: brainstem, cerebral peduncle, head injury, Kernohan's notch, transtentorial herniation

INTRODUCTION

Tentorial herniation is the most common form of brain herniation in supratentorial mass lesions, most notably the traumatic intracranial hematomas. The temporal profile of the herniation syndrome is too well known. However, on rare occasions, there is ipsilateral hemiparesis due to compression of the contralateral cerebral peduncle (Kernohan's notch¹). This syndrome described initially 1929 in a patient with cerebral tumor, has been correlated pathologically by MRI. We describe one such case with traumatic subdural hematoma who presented with ipsilateral hemiparesis. Relevant literature is briefly reviewed.

CASE REPORT

A 56-year-old male was admitted with history of alteration of sensorium, aphasia and inability to move his left upper and lower limbs. Onset of the symptoms was following head injury due to fall from a bicycle two weeks earlier. Clinical evaluation revealed a well built and nourished normotensive individual with Glasgow Coma score of 11/15. He had grade 1/5 power in left upper limb with upper motor neuron type of facial palsy, and grade 3/5 power in left lower limb. Left plantar response was extensor. CT of brain showed large subdural hematoma on the left frontoparietal region causing midline shift. The hematoma was evacuated by a posterior parietal burr hole. MRI done in the postoperative period showed T2-hyperintensity of the right cerebral peduncle (Fig 1), indicative of Kernohan's notch. He showed gradual recovery in motor power over the next three months.

Address for correspondence: Harjinder S Bhatoe M S, M Ch
Department of Neurosurgery, Army Hospital (R & R), Delhi Cantt
110010, Tel: 91-11-25668095, 25668096, Fax: 91-11-25681893
E-mail: hsbhatoe @indiatimes.com

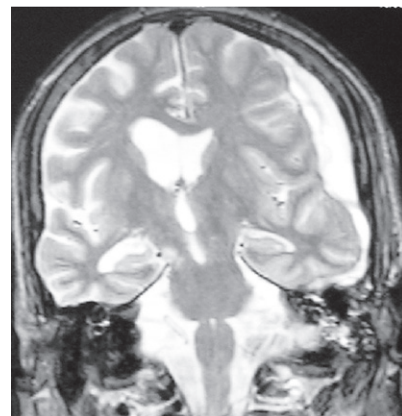


FIGURE 1. Coronal MRI (T2-weighted image) showing hyperintensity in the region of right crus cerebri opposite the tentorial edge, and left sided SDH

DISCUSSION

In tentorial herniation caused by supratentorial lesions, the uncus and the parahippocampal gyri herniated downward through the incisura. These herniations cause direct effects from neural compression and indirect effects from vascular compromise, obstructive hydrocephalus, and herniation of strangulated tissue. The typical clinical profile is that of a ipsilateral dilated pupil and contralateral hemiparesis. The Kernohan-Woltman notch phenomenon is a rare but well described condition whereby the cerebral peduncle opposite to the side of supratentorial mass lesion is forced against the edge of the tentorium, leading to hemiparesis ipsilateral to the side of the supratentorial mass.

The rigid edge of the tentorium may cut into the cerebral peduncle, particularly the fibres that project to the leg. The lesion can occur in the absence of uncal herniation, probably due to rapid acceleration-deceleration force that causes contre-coup injury to the cerebral peduncle². Binder

et al³ studied in left sided motor evoked potentials in a patient with subdural hematoma with ipsilateral hemiparesis; MEPs revealed an increase in voltage threshold and a suppression of waveform complexity on the hemiparetic side.

MRI documentation of Kernohan's notch has been described only eight times so far (Table 1). Typically, there is hyperintensity in the cerebral peduncle on T2-weighted images, best seen on coronal images; 3D MRI clearly demonstrates the notching of the cerebral peduncle⁴.

Table 1: MRI demonstration of Kernohan's notch in head injury

Author	Age/gender	Injury	Right/Left	Other lesion(s)
Binder et al ³	21/M	Depressed#	L	-
Yamasaki et al ⁴	43/M	Chronic SDH	L	-
Jones et al ⁵	25/M	Acute SDH	R	-
Iwama et al ⁶	39/M	Acute SDH	L	-
Itoyama et al ⁷	69/M	Chronic SDH	L	Left ACA aneurysm
Hamada et al ⁸	52/M	Acute SDH	L	
Kole & Hysell ⁹	29/M	Acute SDH	R	
Cohen & Wilson ¹⁰	19/M	Acute SDH	L	Oculomotor palsy
Present case	56/M	Chronic SDH	L	

Abbreviations: ACA – anterior cerebral artery, SDH – subdural hematoma

CONCLUSION

Kernohan's notch phenomenon is one of the frequently discussed but rarely demonstrated false localizing signs in

clinical neurology. Coronal MRI (T2-weighted image) of the brainstem and incisura demonstrates the pathology.

REFERENCES

1. Kernohan JW, Woltman HW. Incisura of the crus due to contralateral brain tumor. *Arch Neurol Psychiat* 1929; 21:274-87.
2. Marion . comment to 3.
3. Binder DK, Lyon R, Manley GT. Transcranial motor evoked potential recording in a case of Kernohan's notch syndrome: Case report. *Neurosurgery* 2004; 54:999-1003.
4. Yamasaki F, Kodama Y, Hotta T, Yuki K, Taniguchi E, Hanshizume A. Magnetic resonance imaging of Kernohan's notch in chronic subdural hematoma. *No To Shinkei* 1997; 49:563-6.
5. Jones KM, Seeger JF, Yoshino MT. Ipsilateral motor deficit resulting from a subdural hematoma and Kernohan's notch. *AJNR* 1991; 12:1238-9.
6. Iwama T, Kuroda T, Sugimoto S, Miwa Y. MRI demonstration of Kernohan's notch: Case report. *Neuroradiology* 1992; 34:225-6.
7. Itoyama Y, Fujioka S, Ushio Y. Kernohan's notch in chronic subdural hematoma: Findings on magnetic resonance imaging. *J Neurosurg* 1995; 82:645-6.
8. Hamada H, Kuwayama N, Endo S, Takaku A. Detection of Kernohan's notch on magnetic resonance imaging in a patient with acute subdural hematoma. *Br J Neurosurg* 2000; 14:498-9.
9. Kole MK, Hysell SE. MRI correlate of Kernohan's notch. *Neurology* 2000; 55:1751.
10. Cohen AR, Wilson J. Magnetic resonance imaging of Kernohan's notch. *Neurosurgery* 1990; 27:205-7.