



Comparison of porcine and human acellular dermal matrix outcomes in wound healing: a deep dive into the evidence

Erin Cihat Saricilar¹, Sarah Huang²

¹Department of Vascular Surgery, Liverpool Hospital, Sydney; ²Department of Plastic Surgery, Royal North Shore Hospital, Sydney, Australia

Acellular dermal matrices (ADM) are a novel graft. The goal of this systematic review is to evaluate the evidence behind differences in human and porcine ADM, irrelevant of manufacturing method, and to determine if there is enough of an evidence base to change clinical practice. An extensive literature search was performed through MEDLINE and Embase with search terms defining a population, intervention and outcome. Title and abstract exclusion were performed with other exclusion criteria. In 191 articles were found after exclusion of duplicates, with only 29 remaining following exclusions. Ten studies were found to have level I and II evidence (I = 3, II = 8), of which two were histopathological, one was an animal model, one was a systematic review, and six were clinical. The remaining studies were reviewed and considered for discussion, but did not hold high enough standards for medical evidence. Strong clinical evidence already exists for the use of human ADM, but questions of access, cost, and ethics require consideration of a xenograft. Histopathologically, evidence suggests minimal long-term differences between human and porcine ADM, although there is a short acute immune response with porcine ADM. Clinically, there is limited difference in outcomes, with a small range in effect of different ADM preparations. Considering the effectiveness of ADM in wound healing, more high-level research with appropriate statistical analysis to facilitate a future meta-analysis is recommended to justify a transition from human to porcine ADM.

Keywords Acellular dermis / Allograft / Xenograft

Received: November 26, 2020 • Revised: February 27, 2021 • Accepted: April 28, 2021
pISSN: 2234-6163 • eISSN: 2234-6171 • <https://doi.org/10.5999/aps.2020.02306> • Arch Plast Surg 2021;48:433-439

INTRODUCTION

While acellular dermal matrices (ADM) can be considered a fairly novel tool in the belt of a plastic and reconstructive surgeon, its impact on the approach to complex clinical situations cannot be understated. Finding a foothold in areas such as head and neck, specifically gingival, breast, abdominal wall and various other areas including burn injuries [1,2], ADM has ingratiated itself as a promising development in a field whose chief goal

is to reshape disfigured, aesthetically unsavory or damaged parts of the body. Even though synthetic products have been seen as beneficial, ADM is superior in it being a biological product, thus reducing the risk of rejection in ongoing recovery and beyond [2]. The key feature of ADM compared to prior biological technologies is that it is an allograft or xenograft from processed skin, devoid of cellular components.

The strategy is that the lack of these leads to reduced inflammation since they are the aspect in the immune response to lead

Correspondence: Erin Cihat Saricilar
Department of Vascular Surgery,
Liverpool Hospital, Elizabeth Street,
Liverpool, NSW 2170, Sydney,
Australia
Tel: +61-2-9926-7111
Fax: +61-2-8425-3970
E-mail: erin.c.saricilar@gmail.com

to donor rejection [3]. The ultimate goal is for the ADM to be identified as host tissue, and thus should have a minimalist footprint: collagen and extracellular matrix components critical in wound healing. While products have a unique preparation method, AlloDerm being the first commercially described ADM, set the groundwork for its development. Typical steps include decellularization, dehydration, sterilization and incorporation [1].

In this report, a literature review was performed on a multitude of studies that strove to compare human and porcine (allograft and xenograft respectively) preparations of an ADM. There was a gross lack of such comparison studies, yet the importance in determining the difference in efficacy is 2-fold: (1) financial benefit of a xenograft and (2) spiritual and personal desires of patients to avoid allografts.

A systematic review is an essential tool in evidence-based medicine, in order to coalesce existing evidence spread throughout various literature, with a goal to remove conflict and streamline understanding of a medical or clinical problem. A key aspect of this method is reproducibility and thus reliability, particularly in a field with such a limited scope of research.

MATERIALS/PATIENTS AND METHODS

Searches were carried out across MEDLINE and Ovid, with a period of search of Ovid MEDLINE(R) 1946 and Embase Classic+Embase 1947, to January 30, 2019. A list of search terms is given in Table 1. The search was divided into population, intervention and outcomes. Following an extensive exclusion based on title, an abstract scrape was performed. Another exclusion was done by looking at the full text based on whether it is a review or abstract only.

Relevant sources were included based on their study type as well as relevance to the research topic through a bibliographic search and basic searching. There was categorical exclusion from data analysis based on the irrelevance due to lack of comparison of human and porcine models.

RESULTS

A broad search strategy was employed in order to prevent the exclusion of critical papers, particularly due to the lack of a cohesive naming structure in a novel and innovative medical technology. Exclusion by title was used primarily to exclude research that was not of relevance.

The literature search identified 278 studies which were then imported into the software Endnote X8 (Thomson Reuters, Toronto, ON, Canada) for purposes of reference management.

Of these, 101 duplicates were removed and 14 additional studies were added through manual searches. A title search was performed to exclude irrelevant studies, resulting in exclusion of 91 studies. Of the remaining 191 studies, abstract review led to the exclusion of 49 resulting in a final 51 studies.

A PRISMA (Preferred Reporting Items for Systematic Reviews and Meta-Analyses) study was performed which can be seen in Fig. 1. Studies were assessed for quality through reading through the entire text and evaluating the methodologies based on criteria devised by the EQUATOR (Enhancing the QUALity and Transparency Of health Research) network [4]. This left 29 primary studies to allow for the evaluation of the differences between human and porcine ADM where a table of "Description of included studies" was performed as shown in Table 1 where only level I and II evidence is included based on the Oxford CEBM levels of evidence [5].

DISCUSSION

The systematic review identified a small collection of studies from a broad range of domains with variable overlap. Distinctly, there was a pertinent lack in evidence surrounding the research question of this review. While Salzberg et al. (2013) [6] defined a comparison between Strattice and human ADM, a potential conflict of interest, and narrow scope (specifically for the use of porcine ADM in immediate breast reconstruction) suggests a limited level of relevance. It is however a good defining point for future studies that can compare porcine and human ADM more generally. Complications and outcomes were investigated with an average follow-up period of 3.5 years. It was found that there was nearly a 2-fold increase in the rates of complications (8.6% vs. 3.9%) which presented with a P-value of 0.07, suggesting a lack of statistical significance [6,7]. The exact nature of these calculations is not known to this author, and hence the relevance of the increase in complications should not be understated. Additionally, it is noted that there is 3-fold increase in the rate of implant loss, which was additionally not statistically significant ($P = 0.09$) [6]. It is noted that as porcine ADM is a xenograft as opposed to an allograft, there is the specific risk of graft rejection, even though all relevant epitopes that cause rejection have been removed in manufacture. Some cases were described as having erythema around the graft, even though there was no histological evidence of graft rejection [6]. The graft did however did not have a homogeneous cellular infiltration and revascularization though there does not seem to be a clinical relevance to this [6,8]. Needless to say, this does require further follow-up to better evaluate.

Table 1. Description of included studies with level 1 and 2 evidence-based on the Oxford 2011 Levels of Evidence

Author (year)	LOE ^{a)}	Field of research	Study design	Total sample size	Clinical question	Outcomes assessed	Results and recommendations
Baldursson et al. (2015) [9]	1	Clinical	Double-blind randomized	162 Full-thickness 4 mm wounds on 81 volunteers	Comparison of fish skin ADM and porcine ADM	Healing rate. Autoimmune safety	Autoimmune reactivity tests performed with ELISA showed autoimmune safety equivalence and healed faster with fish skin ADM (P=0.041).
Campbell et al. (2011) [10]	1	Animal	Randomized	72 Guinea pigs	Human vs. non-cross-linked porcine acellular dermal matrix used for ventral hernia repair	<i>In vivo</i> fibrovascular remodeling and mechanical repair strength	Human ADM had better cellular and vascular infiltration (P < 0.0001, week 4) and better mean cellular infiltration (P < 0.006, week 2).
Ge et al. (2009) [11]	2	Histopathology	Laboratory	NA	Human ADM and porcine ADM	Histological structure and biocompatibility	No significant difference between biocompatibility (P < 0.05). Homogeneity between proteins.
Gowda et al. (2016) [12]	2	Clinical	Individual cohort	11 Cases	Porcine ADM	Vascularization	Histological analysis 3 months postoperatively showed neovascularization and collagen remodeling with minimal inflammatory response. Nil statistical analysis.
Guo et al. (2016) [13]	2	Clinical	Non-randomized controlled trial	60 Adults > 50% total body area burns	Porcine ADM	Length of stay in extensive deep dermal burns	Early dermabrasion combined with porcine ADM coverage improves wound healing time (P < 0.01), reduces the length of hospital stay (P < 0.05), and improves aesthetic and functional results in extensive deep dermal burns with burn size over 50% total body surface area. No difference in mortality rate (P > 0.05).
Jansen et al. (2013) [14]	1	Review	Systematic review	311 Articles	ADM AlloDerm	Evidence	AlloDerm has many clinical uses with promising results. No meta-analysis performed.
Jiong et al. (2010) [15]	2	Clinical	Long-term follow up	152 Deep burn or trauma	Porcine ADM combined with autokin grafting	Clinical application and long-term follow-up	No significant differences between the contracture rates at 3, 6, and 12 months and 1 month after the second surgery (P > 0.05), though significant contracture rate at 1 month post initial surgery (P < 0.05).
Lotan et al. (2018) [16]	2	Histopathology	Laboratory	SurgiMend (n = 23); AlloDerm (n = 20)	Meshed vs. solid sheet ADM	Histopathology	Meshed ADMs tended to increase inflammation (P = 0.074) and promoted giant cell reactions (P = 0.053).
Muangman et al. (2017) [17]	2	Clinical	Individual cohort study	8 Extensive burns with 9 burn areas	Porcine ADM	Extensive burn scars	Porcine ADM had improved scars based on Vancouver scar scales at 3, 6 and 12 months (P < 0.05).
Salzberg et al. (2013) [6]	2	Clinical	Individual cohort study	105 Breast reconstructions on 54 patients	Porcine ADM	Long-term outcomes and complications	No significant difference between complications (P = 0.07), implant loss (P = 0.09), skin breakdown (P = 0.17), hematoma/seroma (P = 0.62), capsular contracture (P = 1.00) and skin delayed healing (P = 0.18). Significant improvement in infection rate (P = 0.005).

LOE, level of evidence; ADM, acellular dermal matrix; ELISA, enzyme-linked immunosorbent assay; NA, not available.

^{a)}Based on the Oxford 2011 Levels of Evidence [5].

Histology

While outcomes and clinical relevance of porcine and human ADM are important, a histopathological understanding of the underlying mechanisms can give a new level of understand and evaluation to the comparison. There is not much viable research in the comparison [11,16], however, there is variable evidence in different preparation methods. Specifically, Lotan et al. (2018) noted that meshed ADM models promoted integration better than solid models. Consequently, a more in-depth study was initiated in order to evaluate the relevance of these findings on immediate, implant-based breast reconstruction. The key

histological finding was that in a mesh, the underlying cells were better able to populate the matrix itself. Relevant research in the field supports the safety of this preparation as well [11,16,18].

Since the ambition of ADM is to improve wound healing, an understanding of the underlying healing mechanisms of the skin is relevant. Wound healing can be broken into inflammation, proliferation and maturation, with significant overlap between each of these stages. Type III collagen is the first to collect in inflammation, with amounts of it dropping 0, being replaced by type I collagen through proliferation and into maturation. Fibronectin follows a similar but broader trend to type III colla-

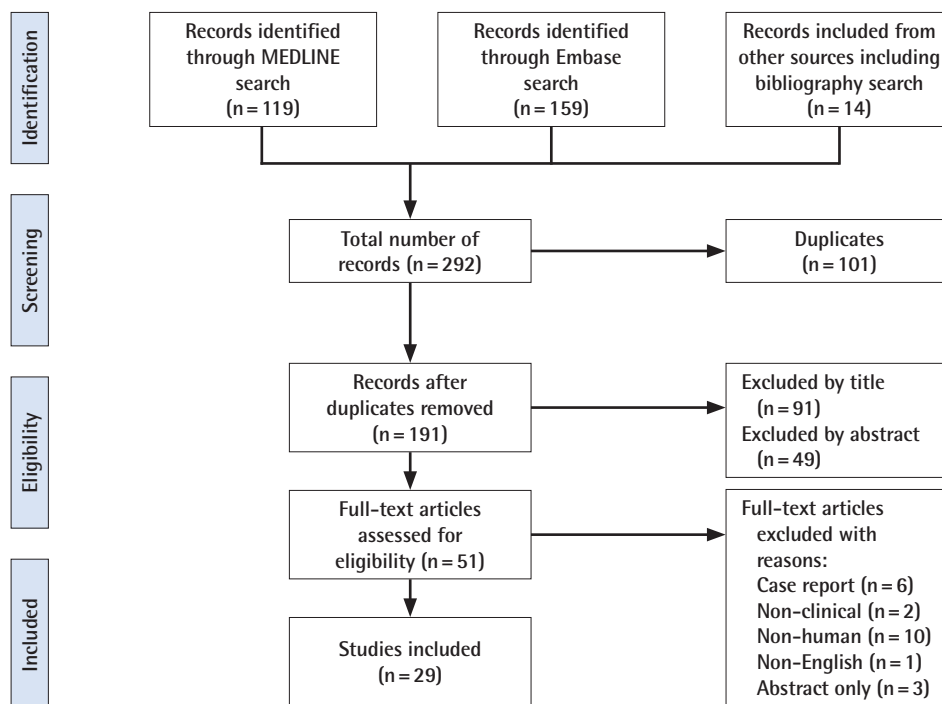


Fig. 1. PRISMA diagram. Literature search using principles of the EQUATOR network [4]. PRISMA, Preferred Reporting Items for Systematic Reviews and Meta-Analyses; EQUATOR, Enhancing the QUALity and Transparency Of health Research.

gen, reaching completely loss about 9 days following wound creation. Initially various inflammatory mediators control the recovery of the wound, with fibroblasts becoming the main cell of function in proliferation [2,19,20].

Histologically, the goal of ADM is to promote rapid healing with a minimal scar. Previous attempts at using synthetic meshes were unable to provide wound healing units such as the required fibronectin to speed this process up. Due to the acellular nature of the products, there is reduced risk of rejection, but the consistent presence of a foreign body does lead them to infection and extrusion in certain scenarios. It has been noted that in non-crosslinked ADM products, there is faster degradation due to the effects of collagenases, while if there is excessive crosslinking, it may prevent suitable integration (meshed vs. solid ADM preparations) [2,16,21,22].

Uses of ADM

The general application of ADM for wound healing is very broad and varied. Unfortunately, there is limited prospective randomized data comparing the use of ADM to the gold standard of each of the procedures that it is replacing. There are consistently primary studies presenting innovative uses for ADM in surgery, but evidence base for these is too weak for suitable discussion. Common uses include: burns and wounds; abdominal wall procedures; reconstructive breast procedures; cosmetic breast pro-

cedures; and head and neck procedures [2].

In the case of burns, the value of an ADM is the ability to provide a matrix for integration of regenerating tissue, particularly in full-thickness wounds, where this natural matrix has been lost. AlloDerm has been shown to have good evidence for use, with some evidence for improved healing efficacy [2,17,23]. The cost of the product has been suggested as a limitation for widespread use, which supports the need to use xenografts [2]. Additionally, there is suitable evidence suggesting that the use of porcine ADM allows for suitable wound healing, reducing hospital stay, and has aesthetic benefits in extensive deep dermal burns over more than 50% total body area. Additionally, it has functional benefits [13]. It was noted that due to the properties of porcine ADM, it is able to support tissue regeneration, fibroblast activity, angiogenesis, and native tissue to regenerate. This study however performed early dermabrasion followed by porcine ADM application for wound closure, with the aim of accelerating wound healing. The benefit of the dermabrasion is to remove potentially devitalized tissue and any layers of dermis that may be colonized by pathogens [13,24].

In a surgery that involves the abdomen, the use of porcine ADM has been compared to human ADM for ventral hernia repair, although only performed on guinea pigs (hence not being a true measure of an allograft against a xenograft as it is effectively two xenografts) [10]. The goal of the study was to determine the

early outcomes of the use of these materials with mechanical testing as well as immunohistologic analyses of the cellular and vascular levels. It was noted that both preparations had good host cell infiltration, but this was more significant in human ADM. It has become clear that more research is required in this area. Though there is evidence of effective vascularization following xenograft application in hernia repairs [12].

It has been noted however that allografts have a weaker tensile strength than porcine ADM in hernia repair [2,25,26]. It is apparent that the mesh should act as support for the wound rather than the actual bridge that links wound borders [2,27]. It is critical for surgeons using ADM regardless of manufacture to consider positioning of the ADM.

There is more extensive study in the field of ADM use in breast procedures. First described in 2001, the area has grown significantly for reconstructive as well as cosmetic breast procedures [1]. Specifically, in these cases, the role of the ADM is to act as an internal support to cover the implant permitting single stage reconstruction, with the placement of the final implant at the initial reconstruction [2,28,29]. It has been noted with relatively strong evidence that the use of a porcine ADM (Strattice) provides complication rates and outcomes similar to human ADM. As previously noted however, the complication rates are increased relative to human ADM with the use of porcine ADM, although this did not reach a level of statistical significance (but the relevance of the increase should not be neglected and should be studied further with higher powered studies) [7]. In the field of cosmetic breast procedures, it has been noted that ADM placement has strong natural contours, without major irregularities [2]. A unique application of porcine ADM has been in repair of Fournier's gangrene. It has been noted that it promotes granulation tissue formation with permits the retention of function and morphology in the perineum and penis [30]. Clearly, there is significant room for investigation in more novel applications of ADM, with the role of porcine ADM not being understated.

Risks

Naturally the risks of usage of porcine ADM overlap with those of human ADM. These typically include infection and rejection risks, as well as failure or dehiscence of the wound. Other risks include delayed healing of the skin and skin breakdown or necrosis. While these are natural risks in human ADM, it has been seen to be slightly yet not statistically significantly increased in breast reconstructions [7]. Interestingly, it was seen that the use of fish ADM was more successful in increased healing rates than porcine ADM, though this is topic of another discussion [9].

As a unique approach to a risk of using ADM, Vedak et al. (2015)

[31] noted that a delayed type IV hypersensitivity reaction in porcine ADM use can present as what appears as an infection. It was believed that there would not be a major host inflammatory response to a natural decellularized tissue such as human or porcine ADM, but this case shows that the potential for a hypersensitivity reaction should be considered as a potential diagnosis in postoperative infection cases. In this situation, the patient had to tolerate multiple debridements.

Benefits

The general benefits of ADM for wound healing are well documented and apparent. A natural method to promoting collagen I and III deposition as well as fibronectin, while promoting fibroblast infiltration into a matrix is clear [2,16]. When using porcine ADM as opposed to human ADM, the main benefit is cost-effectiveness. It is noted that for breast reconstructions or cosmetic surgery, the use of human ADM is a major deterrent due to the cost being footed by the patient. Additionally, a multitude of studies note that human ADM is realistically not cost-effective, and concurrently porcine ADM is much more appropriate for an already overburdened healthcare system all around the world [1,2,6,32]. Naturally it is imperative to ascertain if there is any risk associated with the use of porcine ADM, which preliminarily seems to be clear.

Future recommendations

Porcine ADM as opposed to human ADM has not been studied extensively when it comes to outcomes and complications. It would be essential to perform more high-level research to formulate an evidence base for its more routine use. This research should present justifiable, reliable and replicable statistical analysis in order to provide opportunity for a meta-analysis to be performed in the future.

Further study could also be performed on more unique variants of ADM such as fish-based ADM which has shown some promising results [9].

CONCLUSIONS

ADM are a novel and highly successful tool for improving wound healing by creating a natural and biological base for wound generation through fibroblast invasion and appropriate component deposition. While there is a strong evidence base for human ADM, there is limited research in the comparison with xenografts such as porcine ADM. The benefit in using this would mainly be cost-effectiveness, with human ADM costs being a major deterrent for many patients and healthcare providers. Although there is not enough high-level evidence, preliminarily it

is apparent that both an allograft and xenograft ADM can be used interchangeably, with the surgeon not needing to be worried of poorer outcomes or increased complications (although this needs more research). Robust statistical analysis is required in order to facilitate a strong meta-analysis in the future. Further studies would certainly improve patient care and outcomes for patients requiring improved wound repair and regeneration.

NOTES

Conflict of interest

No potential conflict of interest relevant to this article was reported.

Author contribution

Conceptualization, data curation, formal analysis: EC Saricilar. Methodology, project administration, visualization: EC Saricilar. Writing - original draft: EC Saricilar. Writing - review & editing: EC Saricilar, S Huang.

ORCID

Erin Cihat Saricilar <https://orcid.org/0000-0002-8125-8577>

Sarah Huang <https://orcid.org/0000-0001-5238-0576>

REFERENCES

- Macadam SA, Lennox PA. Acellular dermal matrices: use in reconstructive and aesthetic breast surgery. *Can J Plast Surg* 2012;20:75-89.
- Fosnot J, Kovach SJ 3rd, Serletti JM. Acellular dermal matrix: general principles for the plastic surgeon. *Aesthet Surg J* 2011;31(7 Suppl):S5-S12S.
- Hoyama E, Schellini SA, Pellizon CH, et al. Porcine acellular dermal graft with and without impermeable dressing to treat extensive wounds. *An Bras Dermatol* 2005;80:369-74.
- Moher D, Liberati A, Tetzlaff J, et al. Preferred reporting items for systematic reviews and meta-analyses: the PRISMA statement. *J Clin Epidemiol* 2009;62:1006-12.
- Group OCEBM Levels of Evidence. The Oxford 2011 Levels of Evidence [Internet]. Oxford, Centre for Evidence-Based Medicine; c2019 [cited 2019 Feb 19]. Available from: <https://www.cebm.net/home/>.
- Salzberg CA, Dunavant C, Nocera N. Immediate breast reconstruction using porcine acellular dermal matrix (Strattice™): long-term outcomes and complications. *J Plast Reconstr Aesthet Surg* 2013;66:323-8.
- Salzberg CA, Ashikari AY, Koch RM, et al. An 8-year experience of direct-to-implant immediate breast reconstruction using human acellular dermal matrix (AlloDerm). *Plast Reconstr Surg* 2011;127:514-24.
- Katerinaki E, Zanetto U, Sterne GD. Histological appearance of Strattice tissue matrix used in breast reconstruction. *J Plast Reconstr Aesthet Surg* 2010;63:e840-1.
- Baldursson BT, Kjartansson H, Konradsdottir F, et al. Healing rate and autoimmune safety of full-thickness wounds treated with fish skin acellular dermal matrix versus porcine small-intestine submucosa: a noninferiority study. *Int J Low Extrem Wounds* 2015;14:37-43.
- Campbell KT, Burns NK, Rios CN, et al. Human versus non-cross-linked porcine acellular dermal matrix used for ventral hernia repair: comparison of in vivo fibrovascular remodeling and mechanical repair strength. *Plast Reconstr Surg* 2011;127:2321-32.
- Ge L, Zheng S, Wei H. Comparison of histological structure and biocompatibility between human acellular dermal matrix (ADM) and porcine ADM. *Burns* 2009;35:46-50.
- Gowda AU, Chang SM, Chopra K, et al. Porcine acellular dermal matrix (PADM) vascularises after exposure in open necrotic wounds seen after complex hernia repair. *Int Wound J* 2016;13:972-6.
- Guo ZQ, Qiu L, Gao Y, et al. Use of porcine acellular dermal matrix following early dermabrasion reduces length of stay in extensive deep dermal burns. *Burns* 2016;42:598-604.
- Jansen LA, De Caigny P, Guay NA, et al. The evidence base for the acellular dermal matrix AlloDerm: a systematic review. *Ann Plast Surg* 2013;70:587-94.
- Jiong C, Jiake C, Chunmao H, et al. Clinical application and long-term follow-up study of porcine acellular dermal matrix combined with autoskin grafting. *J Burn Care Res* 2010;31:280-5.
- Lotan AM, Cohen D, Nahmany G, et al. Histopathological study of meshed versus solid sheet acellular dermal matrices in a porcine model. *Ann Plast Surg* 2018;81:609-14.
- Muangman P, Wetwittayanugoon C, Chinaronchai K, et al. Outcomes of porcine acellular dermal matrix in patients with extensive burn scars. *J Med Assoc Thai* 2017;100(Suppl 3):S150-6.
- Palaia DA, Arthur KS, Cahan AC, et al. Incidence of seromas and infections using fenestrated versus nonfenestrated acellular dermal matrix in breast reconstructions. *Plast Reconstr Surg Glob Open* 2015;3:e569.
- Velnar T, Bailey T, Smrkolj V. The wound healing process: an overview of the cellular and molecular mechanisms. *J Int Med Res* 2009;37:1528-42.
- Teller P, White TK. The physiology of wound healing: injury through maturation. *Surg Clin North Am* 2009;89:599-

- 610.
21. de Castro Bras LE, Proffitt JL, Bloor S, et al. Effect of cross-linking on the performance of a collagen-derived biomaterial as an implant for soft tissue repair: a rodent model. *J Biomed Mater Res B Appl Biomater* 2010;95:239-49.
 22. Kang NH, Yun YM, Woo JS, et al. Effects of cross-linking agents on the stability of human acellular dermal matrix. *J Korean Soc Plast Reconstr Surg* 2008;35:248-54.
 23. Winters CL, Brigido SA, Liden BA, et al. A multicenter study involving the use of a human acellular dermal regenerative tissue matrix for the treatment of diabetic lower extremity wounds. *Adv Skin Wound Care* 2008;21:375-81.
 24. Amani H, Dougherty WR, Blome-Eberwein S. Use of Transcyte and dermabrasion to treat burns reduces length of stay in burns of all size and etiology. *Burns* 2006;32:828-32.
 25. Bluebond-Langner R, Keifa ES, Mithani S, et al. Recurrent abdominal laxity following interpositional human acellular dermal matrix. *Ann Plast Surg* 2008;60:76-80.
 26. Burns NK, Jaffari MV, Rios CN, et al. Non-cross-linked porcine acellular dermal matrices for abdominal wall reconstruction. *Plast Reconstr Surg* 2010;125:167-76.
 27. Blatnik J, Jin J, Rosen M. Abdominal hernia repair with bridging acellular dermal matrix: an expensive hernia sac. *Am J Surg* 2008;196:47-50.
 28. Namnoum JD. Expander/implant reconstruction with AlloDerm: recent experience. *Plast Reconstr Surg* 2009;124:387-94.
 29. Topol BM, Dalton EF, Ponn T, et al. Immediate single-stage breast reconstruction using implants and human acellular dermal tissue matrix with adjustment of the lower pole of the breast to reduce unwanted lift. *Ann Plast Surg* 2008;61:494-9.
 30. Zhang Z, Lv L, Mamat M, et al. Xenogenic (porcine) acellular dermal matrix promotes growth of granulation tissues in the wound healing of Fournier gangrene. *Am Surg* 2015;81:92-5.
 31. Vedak P, St John J, Watson A, et al. Delayed type IV hypersensitivity reaction to porcine acellular dermal matrix masquerading as infection resulting in multiple debridements. *Hernia* 2017;21:489-92.
 32. Kirsner RS, Bohn G, Driver VR, et al. Human acellular dermal wound matrix: evidence and experience. *Int Wound J* 2015;12:646-54.