

Extremity/Lymphedema**Image**

Two-team approach in lymphovenous anastomosis and omental lymph node flap harvest for upper limb lymphedema

Joseph Kyu-hyung Park, Yujin Myung

Department of Plastic and Reconstructive Surgery, Seoul National University Bundang Hospital, Seoul National University College of Medicine, Seongnam, Korea

Correspondence: Yujin Myung

Department of Plastic and Reconstructive Surgery, Seoul National University Bundang Hospital, 82 Gumi-ro 173beon-gil, Bundang-gu, Seongnam 13620, Korea

Tel: +82-31-787-2568, Fax: +82-31-787-4055, E-mail: surgene@snu.ac.kr

Received: June 23, 2020 • Revised: October 13, 2020 •

Accepted: October 14, 2020

pISSN: 2234-6163 • eISSN: 2234-6171

<https://doi.org/10.5999/aps.2020.01291>

Arch Plast Surg 2021;48:131-132

Copyright © 2021 The Korean Society of Plastic and Reconstructive Surgeons

This is an Open Access article distributed under the terms of the Creative Commons Attribution Non-Commercial License (<https://creativecommons.org/licenses/by-nc/4.0/>) which permits unrestricted non-commercial use, distribution, and reproduction in any medium, provided the original work is properly cited.

Vascularized lymph node transfer (VLNT) and lymphovenous anastomosis (LVA) can be performed simultaneously or independently, depending on the patient's lymphedema stage [1]. A 54-year-old woman underwent bilateral total mastectomy in 2016, with sentinel lymph node biopsy for the right breast and axillary lymph node dissection for the left breast, followed by chemoradiotherapy. The patient developed progressive lymphedema (indocyanine green dermal stage IV–V), and LVA and VLNT were simultaneously performed (Fig. 1).

The patient was laid supine and draped as illustrated in Fig. 2. First, the recipient vessels (thoracodorsal artery and vein) were prepared and complete scar tissue excision of the axilla and lateral chest was performed. A general surgeon then laparoscopically harvested an omental flap while a plastic surgeon performed LVA. With well-positioned monitors and microscope (Fig. 3), both the harvest and LVA were performed without interfering with each other's operative field (Fig. 4). The upper part of the flap, with gastroepiploic lymph nodes, was inset in the

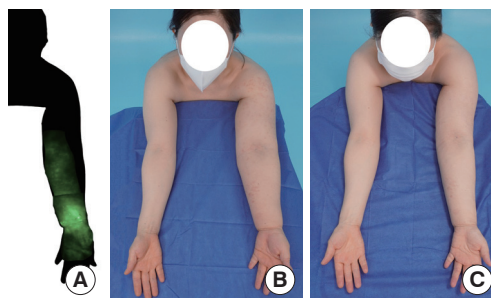


Fig. 1. Indocyanine green lymphography (A), preoperative (B) versus postoperative 85-day (C) medical photographs.

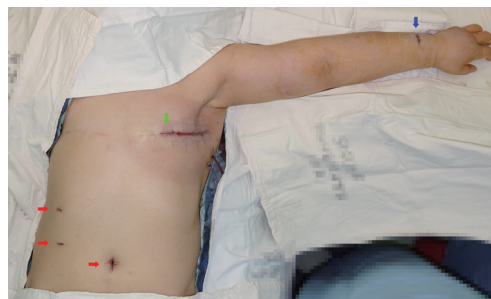

Fig. 2. Immediate postoperative image, illustrating draping and incision sites for lymphovenous anastomosis (blue arrow), vascularized lymph node transfer (green arrow), and laparoscopic omental harvest (red arrows).

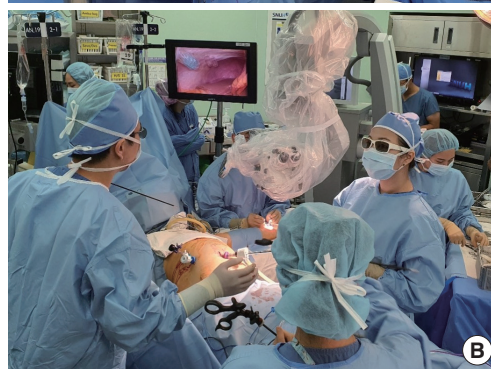
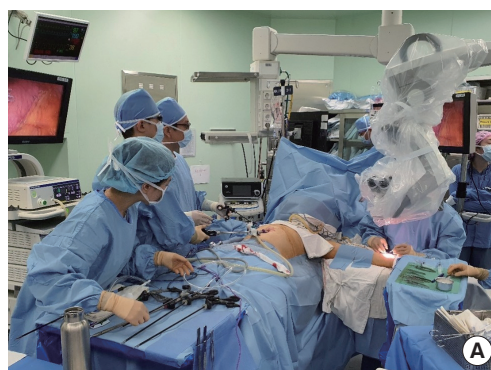
Fig. 3. (A, B) View of the operating room. With well-positioned displays and microscope, both plastic surgery and general surgery teams were able to operate without interfering with each other.

axilla, and the remnant omental tissue was inset in the lateral chest.

The advantages of the omental flap are minimal donor-site morbidity (e.g., iatrogenic lymphedema), the large diameter of the gastroepiploic vessels, and the potential for omental tissue to absorb lymphatic fluid [2]. Additionally, with the two-team approach, the overall operative time can be reduced by 1–3 hours compared to when other donor sites, such as

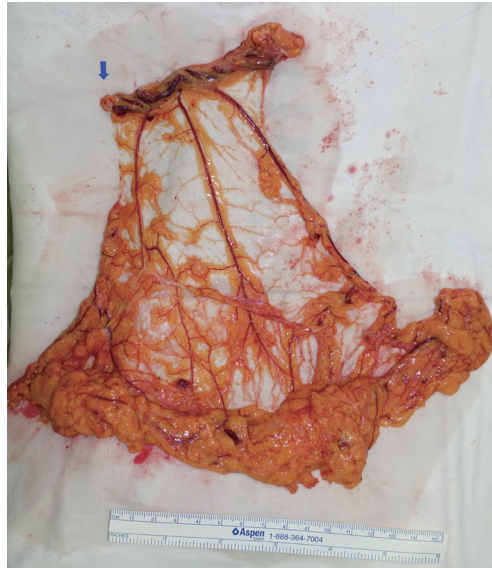

Fig. 4. Harvested omental flap. Right gastroepiploic artery and vein (blue arrow).

the groin or submental space, are used. The patient reported improvement in swelling 2–3 days postoperatively and demonstrated fewer episodes of cellulitis and pruritis, along with a reduction in limb volume by approximately 20%, at 85 days postoperatively (Fig. 1).

Notes

Conflicts of interest

No potential conflict of interest relevant to this article was reported.

Ethical approval

The study was approved by the Institutional Review Board of Seoul National University Bundang Hospital (IRB No. B-2009/637-702) and performed in accordance with the principles of the Declaration of Helsinki. Written informed consent was obtained.

Patient consent

The patients provided written informed consent for the publication and the use of her images.

Author contribution

Conceptualization: JK Park, Y Myung. Writing - original draft: JK Park. Writing - review & editing: Y Myung.

ORCID

Joseph Kyu-hyung Park

<https://orcid.org/0000-0002-0812-6228>

Yujin Myung <https://orcid.org/0000-0001-5051-2440>

References

- Schaverien MV, Coroneos CJ. Surgical treatment of lymphedema. *Plast Reconstr Surg* 2019;144:738-58.
- Ciudad P, Kiranantawat K, Sapountzis S, et al. Right gastroepiploic lymph node flap. *Microsurgery* 2015;35:496-7.