

IMAGE

Refinement of intraoral reverse temporalis transfer for facial palsy using a mandibular periosteum flap

Jin Woo Han, Hook Sun

Department of Plastic and Reconstructive Surgery, Busan Paik Hospital, Inje University School of Medicine, Busan, Korea

Correspondence: Hook Sun

Department of Plastic and Reconstructive Surgery, Busan Paik Hospital, Inje University School of Medicine, 75 Bokji-ro, Busanjin-gu, Busan 47392, Korea
Tel: +82-51-890-6136, Fax: +82-51-894-7976, E-mail: sun443@naver.com

Received: April 30, 2019 • Revised: September 9, 2019 •

Accepted: September 10, 2019

pISSN: 2234-6163 • eISSN: 2234-6171

<https://doi.org/10.5999/aps.2019.00563>

Arch Plast Surg 2020;47:198-199

Copyright © 2020 The Korean Society of Plastic and Reconstructive Surgeons
This is an Open Access article distributed under the terms of the Creative Commons Attribution Non-Commercial License (<https://creativecommons.org/licenses/by-nc/4.0/>) which permits unrestricted non-commercial use, distribution, and reproduction in any medium, provided the original work is properly cited.

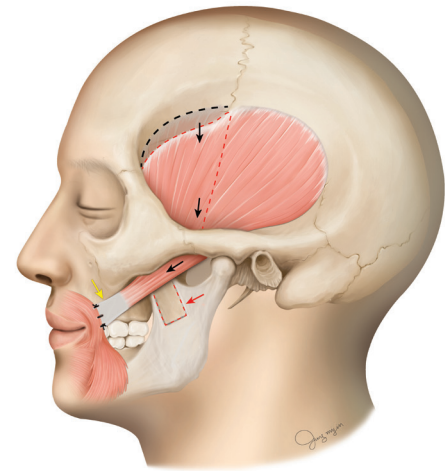


Fig. 1.

Schematic illustration of the surgical technique. The anterior third of the temporalis was gliding downward (black arrows) and the periosteum was dissected from the mandible (red arrow) and anchored to the muscle of the nasolabial fold (yellow arrow).

Temporalis muscle transfer is an example of regional muscle transfer [1,2]. There are also ways to use a fascia lata graft to adjust the traction vector during muscle transfer [3]. This report describes temporalis muscle transfer using the mandibular periosteum and partial temporalis detachment without a fascia lata graft to perform reconstruction in a patient with incomplete facial nerve palsy. First, the temporalis muscle was exposed through a temporal incision and the anterior third of the temporalis was detached from the temporal bone. Next, an intraoral incision was made to create an exposure from the mandibular coronoid process to the mandibular body. The periosteum was dissected from the mandibular body to the coronoid process connecting with the temporalis fascia. A saw was used to cut the coronoid process. The piece of the coronoid process connected to the temporalis was pulled to test whether the detached temporalis glided in the pulling direction. Maintaining the optimal shape of the nasolabial fold, the distal end of the periosteum was anchored to the muscle of the nasolabial fold through subcutaneous tunneling (Figs. 1, 2). The outcomes measured were preoperative and postoperative patient photographs (Fig. 3). The mouth corner showed improved symmetry in the resting state. Temporal area hollowness was not observed. The traditional temporalis muscle transfer technique uses a fascia lata

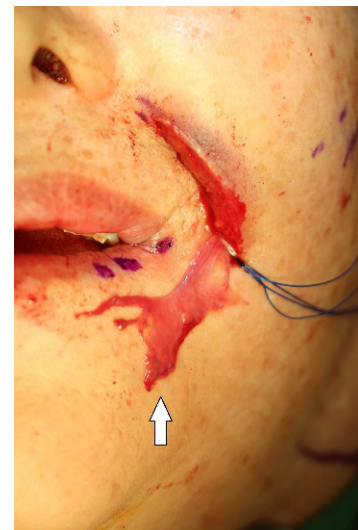


Fig. 2.

Intraoperative photograph. Distal end of the periosteum harvested from the mandible (white arrow); the proximal side was connected to the temporalis muscle.

graft to adjust the magnitude of the vector that exerts traction on the mouth corner. The technique introduced in this report enables adjustment of the magnitude of the vector applied to the mouth corner through partial temporalis detachment and by connecting the mandibular periosteum to the temporalis fascia. This technique produces satisfying cosmetic outcomes without the need for an additional donor site for fascia lata harvest.

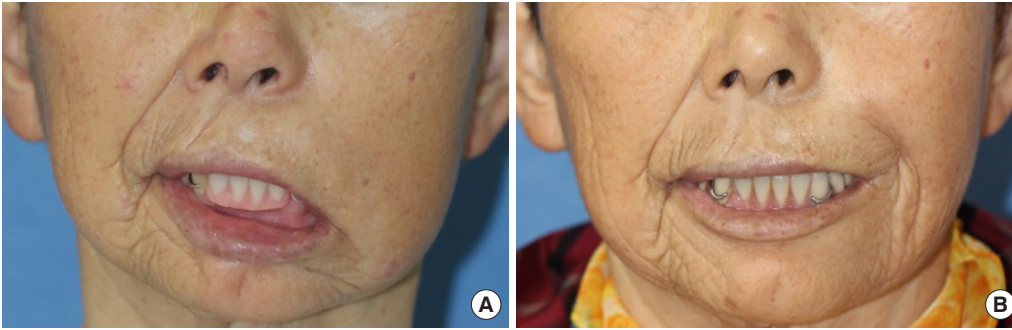


Fig. 3. A 68-year-old woman with congenital incomplete left facial nerve palsy. (A) Preoperative resting state photograph. (B) Two months after the operation, in a resting state.

Notes

Conflict of interest

No potential conflict of interest relevant to this article was reported.

Ethical approval

The study was performed in accordance with the principles of the Declaration of Helsinki. Written informed consent was obtained.

Patient consent

The patient provided written informed consent for the publication and the use of her images.

Author contribution

Conceptualization: Sun H. Formal analysis: Han JW. Methodology: Han JW. Project administration: Han JW. Visualization: Han JW. Writing - original draft: Han JW. Writing - review & editing: Sun H.

ORCID

Jin Woo Han

<https://orcid.org/0000-0002-2672-9954>

Hook Sun <https://orcid.org/0000-0003-0104-2598>

References

1. Croxson GR, Quinn MJ, Coulson SE. Temporalis muscle transfer for facial paralysis: a further refinement. *Facial Plast Surg* 2000;16:351-6.
2. Dhirawani RB, Balaji SM, Singha S, et al. Temporalis muscle transfer with fascia lata sling: a novel technique for facial reanimation. *Ann Maxillofac Surg* 2018;8:307-10.
3. Aum JH, Kang DH, Oh SA, et al. Orthodromic transfer of the temporalis muscle in incomplete facial nerve palsy. *Arch Plast Surg* 2013;40:348-52.