



## Flap thinning: Defatting after conventional elevation

Bo Young Park

*Department of Plastic and Reconstructive Surgery, Ewha Womans University School of Medicine, Seoul, Korea*

Perforator flaps become a reliable option for coverage of various defects and the interest is change from survival of perforator flaps to make thin flaps for better aesthetic and functional outcomes. Multiple flap thinning methods have been demonstrated but it has not been widely attempted because of concerns about compromising circulation of flap thinning. This article will demonstrate the feasibility and benefits of flap thinning technique: defatting after conventional flap elevation.

**Keywords** Flap thinning / Thin flap / Perforator flap

**Correspondence:** Bo Young Park  
Department of Plastic and Reconstructive Surgery, Ewha Womans University School of Medicine, 1071 Anyangcheon-ro, Yangcheon-gu, Seoul 07985, Korea  
Tel: +82-2-2650-5149  
Fax: +82-2-3410-0036  
E-mail: byps@icloud.com

This article contains Supplemental Video S1.

Received: 9 Jul 2018 • Revised: 11 Jul 2018 • Accepted: 11 Jul 2018

pISSN: 2234-6163 • eISSN: 2234-6171 • <https://doi.org/10.5999/aps.2018.00787> • Arch Plast Surg 2018;45:314-318

### INTRODUCTION

Perforator flaps have enjoyed widespread popularity in various kinds of reconstructive procedures because they have the advantages of low donor morbidity and a rapid recovery. They are thinner than conventional flaps, which is advantageous both functionally and aesthetically.

With technical advancements in perforator flaps, interest is shifting from flap survival to making the aesthetic flaps. Recently, the manipulation of thinned flaps has been attempted because bulky flaps are aesthetically unacceptable and result in poor function.

Multiple approaches have been developed for flap thinning, which refers to removing excess adipose tissue from the flap while preserving adequate circulation: defatting after flap elevation (i.e., the removal of specific fat components after conventional flap elevation), thin elevation (elevation of a flap mostly composed of the membranous layer of the superficial fascia), and secondary defatting, which is regarded as the conventional

method [1,2].

While the concept of flap thinning has a long history, it has not been widely used due to concerns that thinned flaps may have disadvantages for survival due to compromised perfusion. Against this background, this article intends to present the theoretical grounds and benefits of primary flap thinning, as well as important precautions to be taken when performing primary flap thinning during surgery, based on actual cases. This study presents the concept of primary defatting after flap elevation for harvesting a thin perforator flap.

### WHY A “THIN” FLAP?

Many previous studies have investigated the topic of flap thinning and concluded that flap thinning is not recommended, given its possible impact on circulation. Nonetheless, one of the biggest advantages of primary thinning is that it enables tissue economy to be achieved by “elevation of appropriately sized flap to fit the requirements of the defect [3].”

If a bulky flap is placed on a defect, it is likely not to expand to the necessary dimension. For this reason, flaps are often elevated to be larger than the size of the defects they are intended to cover, which can increase donor morbidity [3]. In contrast, removal of the deep layer of subcutaneous fat, the superficial fascia system, and part of the superficial layer of the subcutaneous layer improves flap flexibility, enabling easy molding and expansion and eliminating the need to elevate larger flaps. This results in reduced morbidity of both the donor and recipient sites thanks to improved tissue economy [3]. This is particularly beneficial for the contouring of concave defects. Especially when designing flaps for concave areas such as the dorsal or anterior tibial areas, a thick flap not only must be much larger than the defect area, but may also be less flexible, causing difficulty in inseting. A thinner flap, however, can yield better aesthetic outcomes, improve patient satisfaction, and result in a faster recovery.

## HOW TO MAKE IT?

As previously mentioned, the techniques for harvesting thin flaps include modification of the dissection plane, primary thinning after dissection, and secondary thinning after the initial procedure. Ensuring safety is critical when harvesting thin flaps in order to prevent any adverse effects on the perfusion of the flap. I fully adopted Dr. Mun's thinning technique, although I could not make extremely thin flaps due to my limited experience [3,4].

I performed conventional flap elevation at the suprafascial plane, which is easier for elevation regardless of the kind of perforator flaps, and I designed the flap to be the exact same size as the defect because it became pliable after completion of flap thinning. All the procedures were performed after microanastomosis to observe the circulation.

Primary flap defatting is performed with scissors in what is known as the lobule-by-lobule technique, according to the re-

quired thickness of the defect [4]. This procedure is carried out based on a consideration of the circulation status of the flap, while maintaining perfusion, removing loose areolar deep fat, and parts of the superficial fascia and superficial fat with the scissor defatting (lobule-by-lobule) technique under a loupe magnification (Supplemental Video S1).

The course of the perforator should also be considered, and safe removal of fat tissue under microscopic guidance may be preferable if there are concerns about circulation. It is ideal to perform defatting depending on the thickness and flexibility of the flap while performing inseting in the intended area.

## CASE REPORTS

### Case 1

A 39-year-old woman presented with a complaint of non-healing wounds on the left leg. The patient was diagnosed with chronic osteomyelitis of the left tibia, which had been fractured when she was 7 years old. After complete debridement of the bone and soft tissue, an anterolateral thigh perforator flap measuring 16 × 8 cm, with a maximal thickness of 3 cm, was elevated using the conventional suprafascial plane. After anastomosis to the posterior tibial artery (end-to-side anastomosis), primary thinning using the lobule-by-lobule technique with scissors was performed up to 3 cm from the location of the perforator (Fig. 1).

### Case 2

A 41-year-old man presented with diabetic foot ulceration on the posterior aspect of the left heel that had lasted for 6 months. After debridement and infection control, a thoracodorsal artery perforator flap was elevated in the conventional plane. End-to-side anastomosis to the posterior tibial artery was performed, followed by two vein anastomoses. Primary defatting was performed with scissors using the lobule-by-lobule technique. Satisfactory functional and aesthetic results were obtained (Fig. 2).

Fig. 1. Case 1

A 39-year-old woman with chronic osteomyelitis. An anterolateral thigh perforator flap with a maximal thickness of 3 cm (A), primary defatting after conventional elevation (B), photos of postoperative 3 months (C).

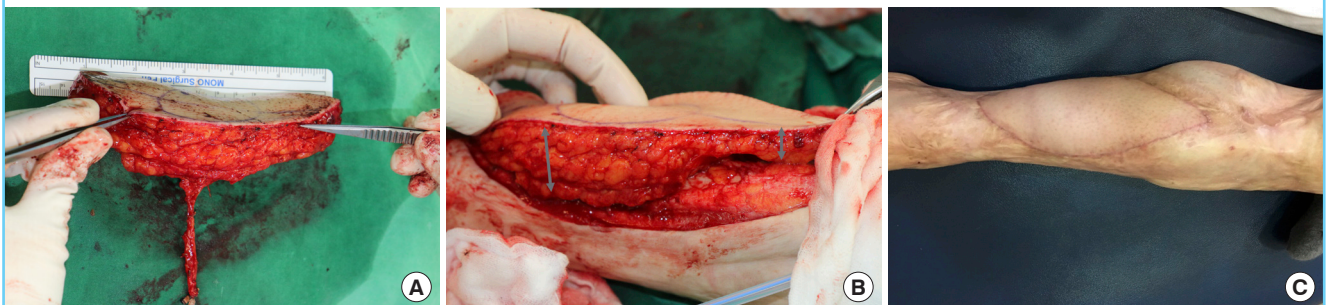
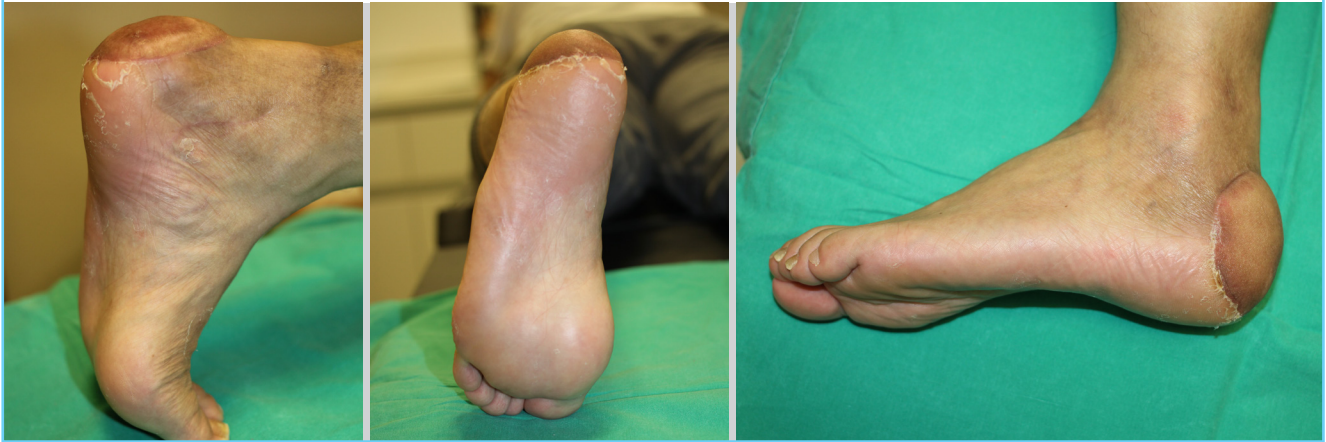

Fig. 2. Case 2

A 41-year-old man with diabetic foot ulceration on the posterior foot. Primary defatting after conventional elevation of thoracodorsal artery perforator flap. Photos of postoperative 6 months.



## SUMMARY

With significant advancements in flap survival rates, microsurgions are shifting their interest from survival of flap to make thin flaps for better aesthetic and functional outcomes. However, concerns related to flap thinning include the possibility of compromised flap perfusion. Nojima et al. [5] reported that the skin-surface vascular territory in thinned flaps decreased to roughly 83.3% and the whole-flap vascular territory decreased to 81.8%. Agostini et al. [6] likewise reported that vascular-related complications were more common in thinner flaps. Although various studies have explored this issue, it is not yet known exactly how to perform “safe flap-thinning procedures.”

Interestingly, most reports were from studies in Japan, and it is thought that the use of thinned perforator flaps is safe based on experiences in Asian patients. In contrast, primary thinning is still inadvisable in Western patients because of the concerns to keep the linking vessels. Therefore, Sharabi et al. [7] recommended secondary defatting by liposuction or re-elevation to obtain a satisfactory contour in their review article.

According to the review of Kim et al. [8], 29 articles have been published regarding flap thinning, and the thinning technique can be classified into three main approaches: defatting after flap elevation ( $n=20$ ), thin elevation with modification of the plane ( $n=7$ ), and a combined method ( $n=2$ ). In particular, recent articles, including the study of Hong et al. [9] on modifying the flap elevation plane, have been attracting more surgeons to start performing flap thinning techniques.

The current consensus in these literatures seems to be that removal of fat from the deep fat layer does not harm flap circulation. Also, it has been found that “a super-thin flap,” which does

not include the prefascial plexus, can be sufficiently nourished by the subdermal plexus and/or the indirect linking vascular system if the flap is small.

Two points of interest when performing a thinning procedure might be the size of the flaps for which a defatting procedure can be performed and the extent needed to ensure safety. The safe dimensions of a thin flap have been reported to be up to approximately 17 to 18 cm in various clinical studies [10].

Another challenging question for surgeons is how we can close to the pedicle when performing a defatting procedure, but unfortunately, no clear answer has yet been established [11-13]. Kimura and Satoh [14] reported that adipose tissue with a diameter of approximately 3 cm around the perforator was sufficient to protect the intra-adiposal branches of the perforator. Furthermore, in a review regarding flap thinning of anterolateral thigh flaps, nine articles suggested that the minimum amount of deep fascia that should be preserved around the perforator was 1 to 3 cm. In 13 articles, it was reported that a flap could be harvested with preservation of only the adipose tissue (without the deep fascia around the pedicle), with a distance of 0.5 to 3 cm from the pedicle [6]. Finally, Nojima et al. [5] identified a 3.5-cm safety zone around the perforator that should be maintained.

Flap thinning methods and their theoretical background have been studied for a long time. The focus of this study was to present the benefits of the technique in which defatting is performed following conventional flap elevation. These benefits range from obtaining the desired thickness through manipulation of the superficial fat layer, a difficult goal to achieve with the thin elevation technique, to its suitability for cases with different intra-flap thickness.

Recently, a new technique known as modification of the eleva-

tion plane has been in the spotlight. However, it is important to map perforators according to computed tomography angiography as a prerequisite for elevation of a flap with a modified plane. Identifying the perforators might also be technically demanding, because the superficial facial system could be less evident in some anatomic areas [8] and the perforators are more evident when a flap is elevated at the modification plane.

Kim et al. [8] established an anatomical basis for thinning procedures of perforator flaps. They demonstrated that the proportion of the superficial fat layer was higher than that of the deep fat layer from the donor site of some perforator flaps. Controlling the superficial fat layer thickness may be essential for obtaining adequate target flap thickness. Therefore, defatting after conventional flap elevation would be advantageous for manipulating the superficial fat layer. Also, Lee et al. [4] presented cases where the superficial layer was thicker than the deep fat layer in areas such as the lower abdomen and groin, which are common donor sites for deep inferior epigastric perforator flaps and superficial circumflex iliac artery perforator flaps. Their results showed that effective thinning of the flap may not be possible without manipulation of the superficial fat layer of the donor site in some patients in whom the superficial layer is thicker than the deep fat layer.

This implies that the defatting technique described in this study enables customized thinning of the superficial fat layer and is excellent for obtaining the required flap thickness, regardless of the specific characteristics of the donor site. Another benefit of this technique is that flap thinning is performed after microanastomosis, while monitoring the circulation of the flap. Doing so helps to secure flap circulation. The risk of injuring the perforator during primary defatting could be greatly reduced by piecemeal excision of fat lobules in a lobule-by-lobule manner and by minimizing defatting around the point of entry of the perforator after anastomosis [4]. While a certain level of experience is crucial for harvesting extremely thin flaps, the plane used for elevating the flap is not only relatively precise for eccentrically positioned perforators and easier to elevate than the plane used for thin elevation, but is also better for safe flap perfusion.

Flap thinning should not only involve reducing the thickness of the flap, but also changing the shape, tension, and pliability; consequently, it has become an essential process for enhancing aesthetic and functional outcome. Although the choice of technique depends on the surgeon's preferences, defatting after conventional flap elevation might be advantageous for manipulating superficial fat layer and could eventually be used to achieve customized flap thickness according to the patient's needs.

## NOTES

### Conflict of interest

No potential conflict of interest relevant to this article was reported.

### Patient consent

The patients provided written informed consent for the publication and the use of their images.

## REFERENCES

1. Kim JT, Koo BS, Kim SK. The thin latissimus dorsi perforator-based free flap for resurfacing. *Plast Reconstr Surg* 2001; 107:374-82.
2. Kim KN, Hong JP, Park CR, et al. Modification of the elevation plane and defatting technique to create a thin thoracodorsal artery perforator flap. *J Reconstr Microsurg* 2016; 32:142-6.
3. Jeon BJ, Lee KT, Lim SY, et al. Plantar reconstruction with free thoracodorsal artery perforator flaps. *J Plast Reconstr Aesthet Surg* 2013;66:406-13.
4. Lee KT, Park BY, Kim EJ, et al. Superthin SCIP flap for reconstruction of subungual melanoma: aesthetic functional surgery. *Plast Reconstr Surg* 2017;140:1278-89.
5. Nojima K, Brown SA, Acikel C, et al. Defining vascular supply and territory of thinned perforator flaps: part I. Anterolateral thigh perforator flap. *Plast Reconstr Surg* 2005;116: 182-93.
6. Agostini T, Lazzeri D, Spinelli G. Anterolateral thigh flap thinning: techniques and complications. *Ann Plast Surg* 2014;72:246-52.
7. Sharabi SE, Hatef DA, Koshy JC, et al. Is primary thinning of the anterolateral thigh flap recommended? *Ann Plast Surg* 2010;65:555-9.
8. Kim SY, Lee YJ, Mun GH. Anatomical understanding of target subcutaneous tissue layer for thinning procedures in TDAP, SCIP and ALT perforator flaps. *Plast Reconstr Surg* 2018 May 22 [Epub]. <https://doi.org/10.1097/PRS.0000000000004619>.
9. Hong JP, Choi DH, Suh H, et al. A new plane of elevation: the superficial fascial plane for perforator flap elevation. *J Reconstr Microsurg* 2014;30:491-6.
10. Koshima I, Fukuda H, Yamamoto H, et al. Free anterolateral thigh flaps for reconstruction of head and neck defects. *Plast Reconstr Surg* 1993;92:421-8.
11. Kimata Y, Uchiyama K, Ebihara S, et al. Anatomic variations and technical problems of the anterolateral thigh flap: a report of 74 cases. *Plast Reconstr Surg* 1998;102:1517-23.

12. Luo S, Raffoul W, Luo J, et al. Anterolateral thigh flap: a review of 168 cases. *Microsurgery* 1999;19:232-8.
13. Ross GL, Dunn R, Kirkpatrick J, et al. To thin or not to thin: the use of the anterolateral thigh flap in the reconstruction of intraoral defects. *Br J Plast Surg* 2003;56:409-13.
14. Kimura N, Satoh K. Consideration of a thin flap as an entity and clinical applications of the thin anterolateral thigh flap. *Plast Reconstr Surg* 1996;97:985-92.

**Supplemental Video S1.** Primary defatting after conventional elevation of anterolateral thigh free flap. Excision of fat lobule (lobule-by-lobule manner).

**Supplemental data can be found at: <https://doi.org/10.5999/aps.2018.00787.v001>**