



The efficacy of elongated axillary incision on extended latissimus dorsi flap for immediate breast reconstruction

Tae Seo Park¹, Su Bong Nam¹, Jae Yeon Choi¹, Sung Hwan Bae², Jae Woo Lee¹, Hyun Yul Kim³

¹Department of Plastic and Reconstructive Surgery, Pusan National University Yangsan Hospital, Pusan National University School of Medicine, Yangsan; ²Department of Plastic and Reconstructive Surgery, Pusan National University Hospital, Pusan National University School of Medicine, Busan; ³Department of Surgery, Pusan National University Yangsan Hospital, Pusan National University School of Medicine, Yangsan, Korea

Background In performing extended latissimus dorsi (ELD) flap procedures, a skin paddle design on the bra line helps reduce visible scarring. This improves the patient's satisfaction with the outcome. However, such a design leads to a longer operation time and increased fatigue of the surgeon due to the narrow operative field. In this study, the authors propose a method that elongates the axillary incision line posteriorly by 1.5 cm from the lateral border of the latissimus dorsi muscle. We examined whether this method could shorten the operation time and compared the incidence of complications between patients who underwent this novel procedure and patients who underwent the traditional procedure.

Methods In this study of patients who underwent ELD flap procedures for immediate breast reconstruction, 89 underwent surgery with the elongated axillary incision and 45 underwent surgery without the elongated incision. The total operation time and complications were retrospectively examined based on the patients' medical records, and we examined whether there was any statistically significant difference in the total operation time.

Results In the experimental group with the elongated axillary incision, the operation time ranged from 125 to 255 minutes (median, 175 minutes). In contrast, in the control group without the elongated axillary incision, the operation time ranged from 142 and 340 minutes (median, 205 minutes). The operation time was statistically significantly different between the two groups, and no significant complications were observed in the experimental group.

Conclusions Elongation of the axillary incision alone may shorten the operation time of the ELD flap procedure without causing additional complications.

Keywords Mammoplasty / Surgical flaps / Superficial back muscles

Correspondence: Su Bong Nam
Department of Plastic and Reconstructive Surgery, Pusan National University Yangsan Hospital, Pusan National University School of Medicine, 20 Geumo-ro, Mulgeum-eup, Yangsan 50612, Korea
Tel: +82-55-360-1670
Fax: +82-55-360-2158
E-mail: subong71@hanmail.net

This work was supported by a clinical research grant from Pusan National University Yangsan Hospital 2016.

Received: 14 Nov 2017 • Revised: 14 May 2018 • Accepted: 27 May 2018
pISSN: 2234-6163 • eISSN: 2234-6171 • <https://doi.org/10.5999/aps.2017.01683> • Arch Plast Surg 2018;45:340-344

INTRODUCTION

The latissimus dorsi (LD) flap procedure is a widely used autol-

ogous breast reconstruction method [1,2]. The size and location of the skin paddle of the LD flap necessary for reconstruction vary by the extent and location of the incision: inner

oblique, outer oblique, or transverse designs are available. In 1983, Hokin [3] introduced an extended latissimus dorsi (ELD) flap procedure, which collects a large quantity of tissue. In performing this procedure, an oblique design is used that is parallel to the posterior axillary line—the commonly used method for the donor site. This offers the advantage of easy flap collection. However, this also leaves a severe postoperative scar and is highly likely to lead to donor site deformation (Fig. 1) [4]. Therefore, in recent years, a transverse incision on the bra line has been the preferred method, as it leaves a less visible scar (Fig. 2).

However, a transverse skin paddle design narrows the operative field. This causes flap dissection and makes transferring the pedicle flap challenging, subsequently leading to longer operation times. Furthermore, in cases where a defect is located in the inferior medial quadrant, transferring the skin paddle for reconstruction becomes more difficult.

Axillary lymph-node dissection procedures by general surgeons are commonly performed while the patient is in a supine position. Usually, the incision is made horizontally up to the lateral border of the pectoralis major, which is rather short. Therefore, there are many challenges in isolating the pedicle of the LD and dissecting and transferring the flap, which is necessary for the surgical reconstruction performed by plastic surgeons.

To address the abovementioned issues, the authors elongated the axillary incision that was made by general surgeons previously for lymph-node dissection from the lateral position for immediate breast reconstruction after a mastectomy. We aimed to examine the effectiveness of this innovation by investigating the operation time (in particular, whether it was shortened) and the incidence of scar-related complications.

METHODS

The present study was approved by the Institutional Review Board of Pusan National University Yangsan Hospital (IRB No. 05-2018-047).

The subjects' medical records were retrospectively analyzed, and consent for the use of medical records was received from the patients. We used an elongated axillary incision for 89 patients who underwent immediate breast reconstruction with an ELD musculocutaneous flap from July 2014 to December 2016. The incision was placed on the axillary fold in the lateral position and was elongated by 1.5 cm posteriorly to the lateral border of the LD (Fig. 3). We used a horizontal oval-shaped skin paddle along the bra line that had been marked prior to surgery while the patient was in a sitting position.

Fig. 1. Long scar on the donor site

A patient who was operated on without an elongated axillary incision line.

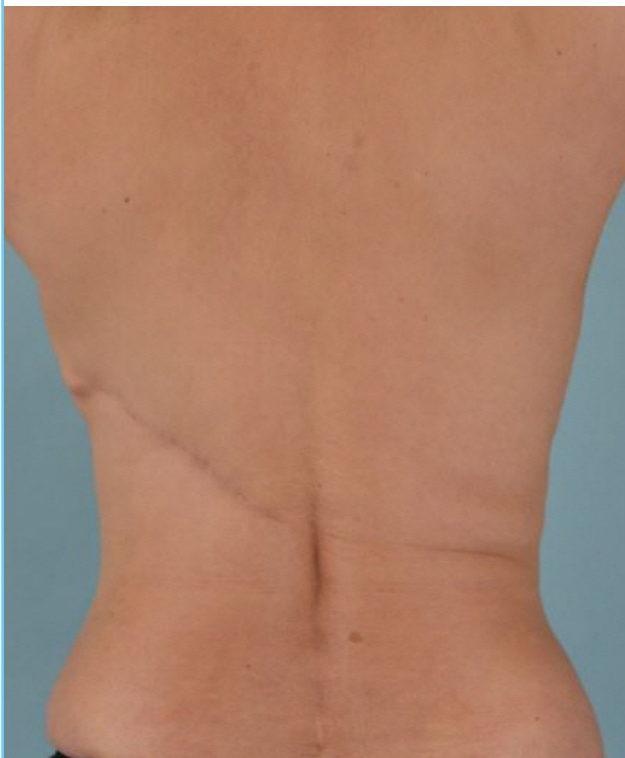

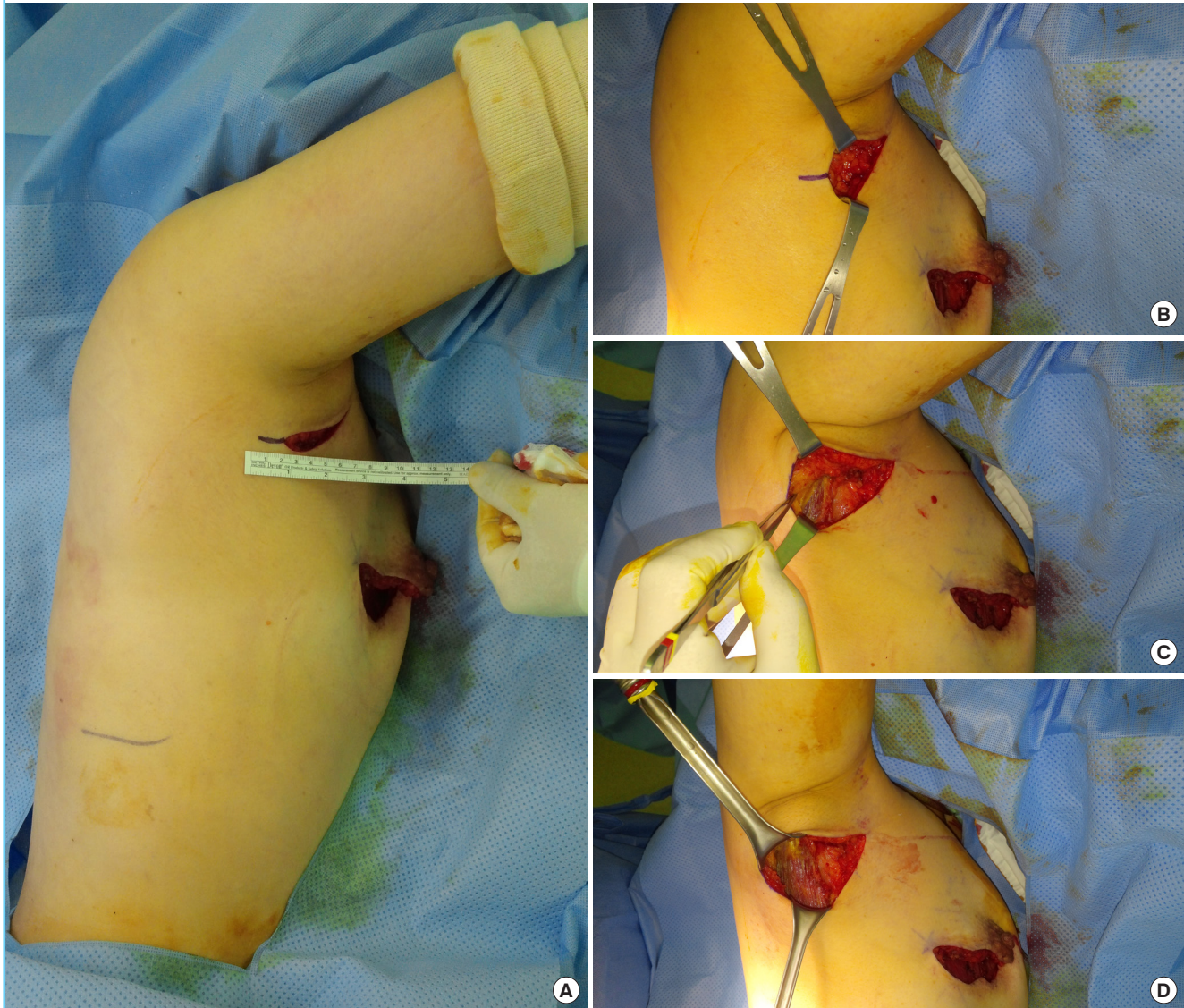
Fig. 2. Less visible scar on the donor site

A patient who was reconstructed using an extended latissimus dorsi flap with an elongated axillary incision line.

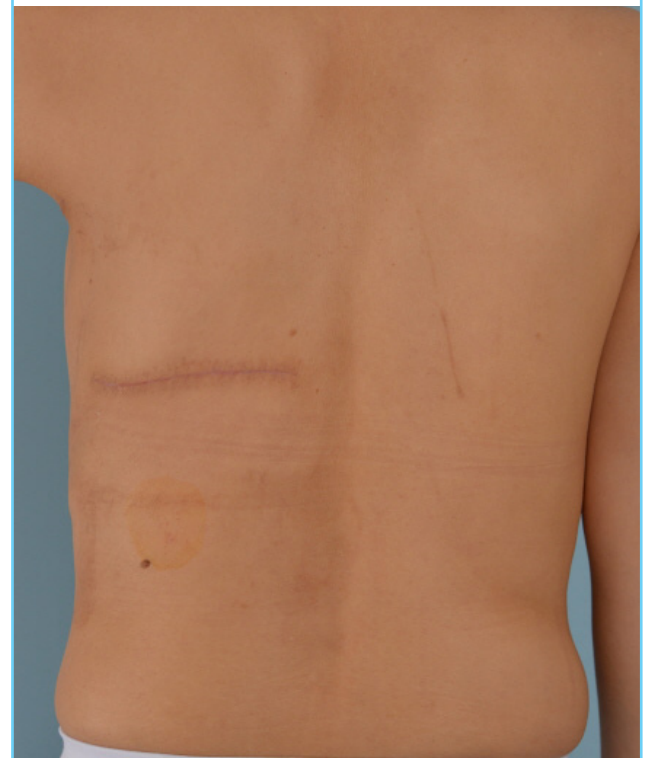

Fig. 3. Efficacy of the elongated axillary incision line

(A-D) The incision was elongated by 1.5 cm posteriorly to the lateral border of the latissimus dorsi.



Through the elongated axillary incision, the LD was detached sufficiently from the adipose layer to the inferior angle of the scapula. The upper border of the LD was separated from the teres major. Additionally, through the elongated axillary incision, we secured ample space for the detachment and isolation of the LD flap pedicle.

Forty-five patients who underwent immediate breast reconstruction with the ELD flap without the elongated axillary incision from January 2012 to June 2014 were used as a control group.

Based on the medical records of the two patient groups, we examined whether there was any statistically significant difference in operation times between the two groups, as defined by the time the incision was made to the time the operation ended.

Moreover, we conducted a statistical analysis to identify whether patients' body mass index (BMI) or the weight of the removed breast tissue affected the operation time. We also compared the length of the scar between the two patient groups. All of the procedures were conducted by a surgeon in the plastic and reconstructive surgery department of this hospital. Mann-Whitney tests were used to statistically analyze the data. We considered a P-value of < 0.05 to indicate statistical significance. All statistical analyses for this study were conducted with MedCalc version 22.0 (MedCalc Software bvba, Ostend, Belgium).

RESULTS

In the experimental group with elongated axillary incision, the

operation time ranged from 125 to 255 minutes (median, 175 minutes) and the length of the incision ranged from 5 to 10 cm (median, 7.5 cm). In contrast, for the control group that did not undergo elongated axillary incision, the operation time took between 142 and 340 minutes (median, 205 minutes) and the length of the incision was between 5 and 8 cm (median, 6 cm). There was a statistically significant difference between the two groups ($P < 0.05$) (Table 1).

The BMI of the patients and the weight of the removed breast tissue did not correlate with the operation time ($P > 0.05$).

There were no significant complications involving scarring in the axillary region after the elongated incision. No cases required scar revision. Moreover, the scars were not visible while in the upright standing position (shoulder adduction) and were therefore well accepted by the patients. Moreover, no complaints about scar contracture were reported.

DISCUSSION

For reconstruction of a medium-sized or smaller breast using autologous tissue after total mastectomy, a transverse rectus abdominis myocutaneous flap or a deep inferior epigastric perforator flap is used with an ELD flap. After partial mastectomy, an ELD flap should be the primary choice, regardless of breast size [5-8]. Several factors should be considered when an ELD flap is

used, including the scar or deformation that will remain on the donor site and the extension of the operation time due to changes in position during surgery.

The skin paddle designs of the ELD flap are diverse. The part of the breast that needs reconstruction and the patient's preferences regarding the location of the incision scar may determine the choice in design [9,10]. Because the horizontal skin paddle design leaves a scar along the bra line, patients' satisfaction with this design is high, and it recently has become an increasingly popular choice.

The volume of the ELD flap is larger than that of the conventional LD flap. Therefore, ample subcutaneous tunneling and pedicle isolation are necessary to allow for flap rotation and transfer. However, in cases where a transverse skin paddle design is used, the operative field is narrow and dissection from the scapular tip to the axillary region is challenging. This leads to longer operation times and increased fatigue of the surgeon.

Moreover, the axillary incision made during lymph node dissection by general surgeons is performed in the supine position: the length of the incision is short, and the incision is made to the anterior chest, toward the pectoralis major. Therefore, the operative field is narrow for harvesting the flap and isolating the pedicle through the axillary incision from the lateral position, which in turn increases the likelihood that it will be necessary to make the skin paddle close to the axillary incision line or to place it in an oblique position.

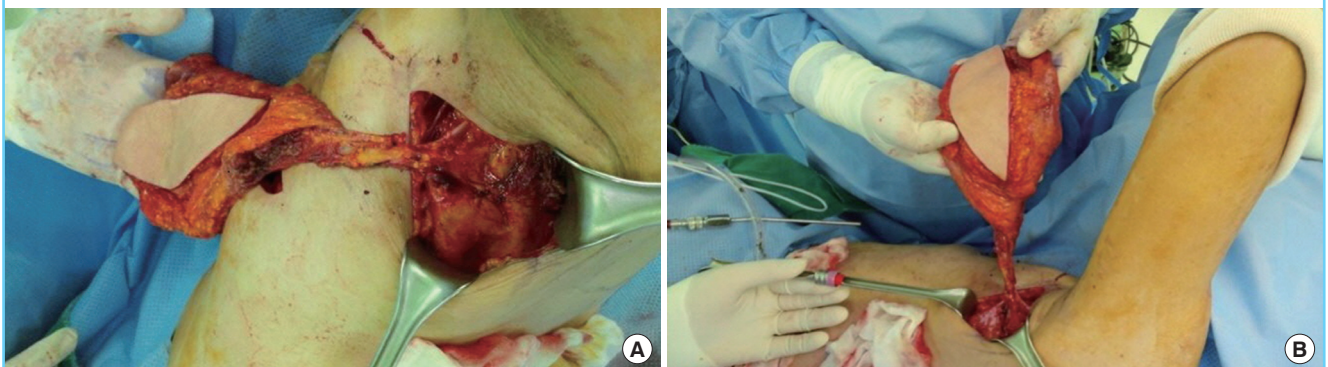
When the axillary incision performed by general surgeons is elongated to the lateral border of the LD muscle by 1.5 cm posteriorly in the lateral position and parallel to the axillary fold, dissecting the proximal part of the LD (between the inferior angle of the scapula and the axillary region) becomes easier, even when using a skin paddle parallel to the bra line, as previously mentioned. Moreover, as ample room for pedicle isolation is created, the operative field is broadened. The teres major muscle

	Elongated incision (n = 89)	No elongated incision (n = 45)	P-value ^{a)}
Total operation time (min)	175 (125–255)	205 (142–340)	<0.001
Length of incision (cm)	7.5 (5–10)	6 (5–8)	<0.001

Values are presented as median (range).
^{a)}Mann-Whitney test.

Fig. 4. LD separation and pedicle isolation

(A, B) When the latissimus dorsi (LD) is made thinner by sculpting its proximal part and sufficiently dissecting the tissues surrounding the pedicle, the bulging deformity can be minimized and the breast can be reconstructed satisfactorily, including the inner lower part.



and the upper border of the LD can be easily detached, and separating the LD and dissecting or shaping the muscle component may be easier; this also prevents bulging deformities in the anterior axillary fold (Fig. 4). Furthermore, isolating a pedicle of 10 cm or longer becomes possible. This makes the inseting of a flap far easier, regardless of the skin paddle direction.

As the authors gained more experience with this surgical technique, we were able to make the skin paddle incision along the bra line even smaller; eventually, we left a relatively short and even scar on the donor site, using only a horizontal, oval-shaped skin paddle ≤ 3 cm wide and ≤ 12 cm long. Through the elongated axillary incision, a tunnel connecting to the detached area was easily made. Additionally, sufficient space was secured to transfer ELD flaps that weighed 300 g or more. Moreover, we were able to minimize damage to the flap that could have occurred with the unnecessary use of a retractor, thereby helping to prevent scar contracture on donor site. Overall, we shortened the operation time from making the incision to end of operation by approximately 30 minutes.

The scar near the axilla was unnoticeable in shoulder adduction. There were no complications such as contracture deformities. Moreover, no hypertrophic deformities were found in the incision scar in the breast or in the axilla, which is partially deemed to be an effect of radiation therapy. Patients with breast cancer are less likely than aesthetic plastic surgery patients to report complaints about scarring, as long as there is no discomfort or severe deformity, even if the scar is rather long.

A shortcoming of this technique is that an additional procedure is needed to elongate the axillary incision. Moreover, handling the pedicle of the LD is easy through the elongated incision, but there is a risk of damage, making careful and attentive detachment necessary.

In conclusion, when performing breast reconstruction using the ELD flap, elongation of the axillary incision, which secured a sufficient operative field, made it easier to harvest and transfer the flap, and led to an even and horizontal scar on the donor site and a shorter operation time.

NOTES

Conflict of interest

No potential conflict of interest relevant to this article was reported.

Ethical approval

The study was approved by the Institutional Review Board of Pusan National University Yangsan Hospital (IRB No. 05-2018-047) and performed in accordance with the principles of the Declaration of Helsinki. Written informed consents were obtained.

Patient consent

The patients provided written informed consent for the publication and the use of their images.

REFERENCES

1. Heitmann C, Pelzer M, Kuentscher M, et al. The extended latissimus dorsi flap revisited. *Plast Reconstr Surg* 2003;111:1697-701.
2. Lee JW, Chang TW. Extended latissimus dorsi musculocutaneous flap for breast reconstruction: experience in Oriental patients. *Br J Plast Surg* 1999;52:365-72.
3. Hokin JA. Mastectomy reconstruction without a prosthetic implant. *Plast Reconstr Surg* 1983;72:810-18.
4. Menke H, Erkens M, Olbrisch RR. Evolving concepts in breast reconstruction with latissimus dorsi flaps: results and follow-up of 121 consecutive patients. *Ann Plast Surg* 2001;47:107-14.
5. McCraw JB, Papp C, Edwards A, et al. The autogenous latissimus breast reconstruction. *Clin Plast Surg* 1994;21:279-88.
6. Papp C, McCraw JB. Autogenous latissimus breast reconstruction. *Clin Plast Surg* 1998;25:261-6.
7. Germann G, Steinau HU. Breast reconstruction with the extended latissimus dorsi flap. *Plast Reconstr Surg* 1996;97:519-26.
8. Chang DW, Youssef A, Cha S, et al. Autologous breast reconstruction with the extended latissimus dorsi flap. *Plast Reconstr Surg* 2002;110:751-9.
9. Moore TS, Farrell LD. Latissimus dorsi myocutaneous flap for breast reconstruction: long-term results. *Plast Reconstr Surg* 1992;89:666-72.
10. Maxwell GP. Latissimus dorsi breast reconstruction: an aesthetic assessment. *Clin Plast Surg* 1981;8:373-87.