

vessel for microanastomosis, non-microsurgical methods are suggested, such as a composite graft, retroauricular pocket, or a temporoparietal fascia flap. A few reports of large composite grafts to the ear have been published. The survival rate of composite grafts is lower than that of replantation with microvascular anastomosis. The vessel status of amputees who have sustained a human bite injury is often not suitable for anastomosis. Moreover, the risk of wound infection is often increased, as in our case. A variety of adjunctive treatments, such as the administration of heparin, prostaglandin, leeches, and HBOT, have been introduced for patients who undergo a composite graft. However, these treatment options have not yet been established.

In our case, after a composite graft, we performed HBOT. This approach has 2 advantages with respect to wound healing. First, it is known to promote healing by increasing reperfusion [2]. In cases of a composite graft without microvascular anastomosis, it is crucial for adequate blood circulation to be supplied during wound healing. This increases angiogenesis and stimulates fibroblast proliferation [2]. Thus, the survival of compromised skin grafts and flaps can be increased by oxygen therapy [3]. Oxygen therapy has also been proven to have a bactericidal effect [4]. In cases of human bite injury, there is a higher risk of infection than in injuries due to other causes because of the vast array of bacterial species in the mouth [5].

A few case reports have described employing HBOT as an adjunctive method for composite grafts. However, in order to implement HBOT, equipment such as a high-pressure oxygen hood or a chamber is necessary. Such equipment is not available in many hospitals. We performed adjunctive HBOT by connecting oxygen to a plastic bag around the wound at the patient's bedside. In our case, HBOT was employed and was effective for improving composite graft survival. Compared to conventional methods of administration using a chamber or a hood, this method can be more easily applied to patients if it is possible to supply pure oxygen at the bedside. Therefore, if a chamber or a hood for HBOT is not available, our method can be used as a treatment strategy.

### Conflict of Interest

No potential conflict of interest relevant to this article was reported.

### Patient Consent

The patient provided written informed consent for the publication and the use of their images.

### References

1. Lin PY, Chiang YC, Hsieh CH, et al. Microsurgical replantation and salvage procedures in traumatic ear amputation. *J Trauma* 2010;69:E15-9.
2. Kimmel HM, Grant A, Ditata J. The presence of oxygen in wound healing. *Wounds* 2016;28:264-70.
3. Faydaci G, Ugur K, Osman C, et al. Amputation of glans penis: a rare circumcision complication and successful management with primary anastomosis and hyperbaric oxygen therapy. *Korean J Urol* 2011;52:147-9.
4. Andrade SM, Santos IC. Hyperbaric oxygen therapy for wound care. *Rev Gaucha Enferm* 2016;37:e59257.
5. Patil PD, Panchabhai TS, Galwankar SC. Managing human bites. *J Emerg Trauma Shock* 2009;2:186-90.

## Irritated Subtype of Seborrheic Keratosis in the External Auditory Canal

June Kyu Park<sup>1</sup>, Kyung Sik Kim<sup>1</sup>, Seung Hong Kim<sup>1</sup>, Jun Choi<sup>1</sup>, Jeong Yeol Yang<sup>1</sup>, Jeong Ju Lee<sup>2</sup>

Departments of <sup>1</sup>Plastic and Reconstructive Surgery and <sup>2</sup>Pathology, Myong-Ji Hospital, Goyang, Korea

**Correspondence:** Kyung Sik Kim  
Department of Plastic and Reconstructive Surgery, Myong-Ji Hospital,  
55 Hwasu-ro 14beon-gil, Deogyang-gu, Goyang 10475, Korea  
Tel: +82-31-810-6830, Fax: +82-31-810-6837, E-mail: kskimps@mjh.or.kr

Received: 27 Jun 2017 • Revised: 24 Aug 2017 • Accepted: 5 Sep 2017  
pISSN: 2234-6163 • eISSN: 2234-6171  
<https://doi.org/10.5999/aps.2017.01081>  
*Arch Plast Surg* 2017;44:570-572



Copyright © 2017 The Korean Society of Plastic and Reconstructive Surgeons  
This is an Open Access article distributed under the terms of the Creative Commons Attribution Non-Commercial License (<http://creativecommons.org/licenses/by-nc/4.0/>) which permits unrestricted non-commercial use, distribution, and reproduction in any medium, provided the original work is properly cited.

Seborrheic keratosis (SK) is commonly observed throughout the body, except the palms and soles [1]. However, SK in the external auditory canal (EAC) is rare [2,3]. In this report, we describe a case of SK in the EAC.

A 56-year-old man presented to our outpatient plastic surgery clinic with a 1-year history of a slow-

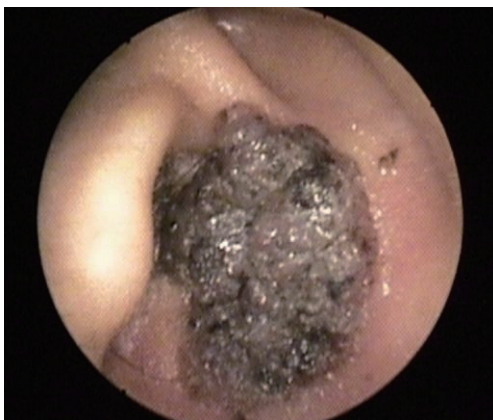growing, painless mass in his left auricle. In the physical examination, we observed a 2.5- × 2.0-cm blackish papillomatous lesion within the left cavum concha, extending into the EAC (Fig. 1). There was no palpable enlargement of the regional lymph nodes. An incisional biopsy was performed to rule out a malignant skin tumor, and the histopathological examination revealed SK. Subsequently, an excisional biopsy was performed (Fig. 2A). The EAC and cavum concha were reconstructed with a full-thickness skin graft taken from the retroauricular region (Fig. 2B). The second histopathological examination confirmed the final diagnosis of the irritated subtype of SK, without evidence of malignancy (Fig. 3). At a 6-month follow-up visit, no recurrence was noted (Fig. 4).

Histopathologically, SKs are classified into 7 histological subtypes: acanthotic, hyperkeratotic, adenoid, clonal, bowenoid, irritated, and melanoacanthoma [1]. The acanthotic subtype is the most common [1]. However, in our patient, the histopathological examination confirmed the irritated subtype of SK, which rarely arises in the EAC [2]. To our knowledge, only 4 cases of the irritated subtype of SK in the ear have been presented in the English-language literature.

The clinical differential diagnosis of SK is very important because the disorder can be confused with a malignant skin tumor [1,2]. Therefore, a biopsy should always be performed to exclude malignancy.

### Patient Consent

The patient provided written informed consent for



**Fig. 1.** Otoscopy reveals a blackish papillomatous lesion within the left cavum concha, extending into the external auditory meatus.

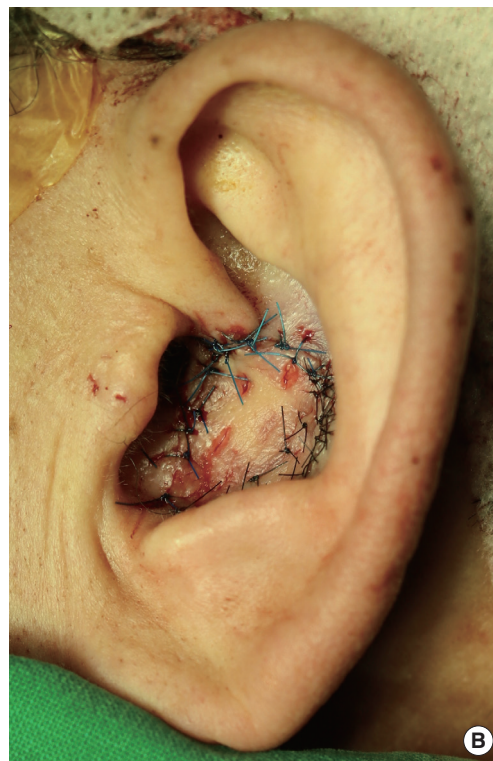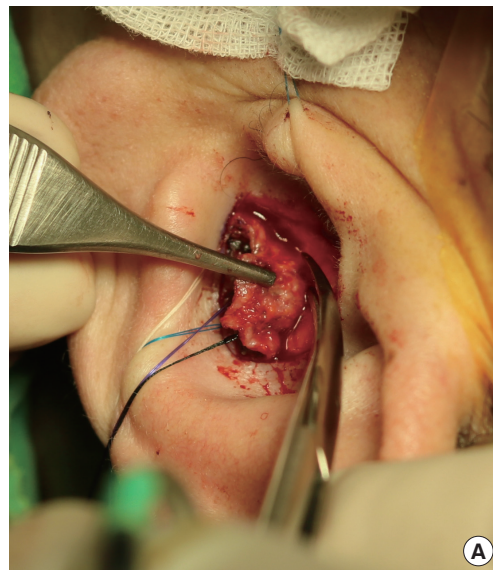
the publication and the use of their images.

### Conflict of Interest

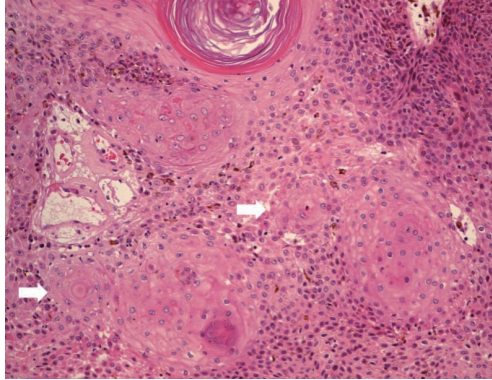
No potential conflict of interest relevant to this article was reported.

### ORCID

Kyung Sik Kim <https://orcid.org/0000-0002-2101-9654>

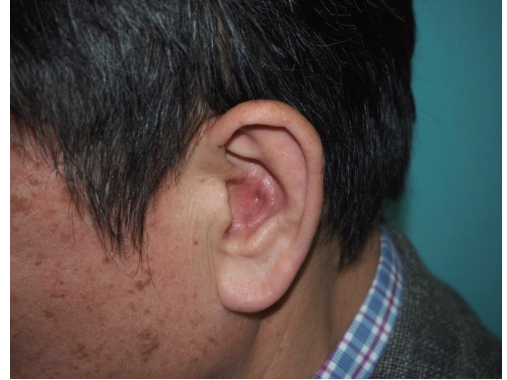

**Fig. 2.** (A) Intraoperative photograph; the seborrheic keratosis within the left cavum concha, extending into the external auditory meatus, was completely excised. (B) Postoperative photograph after excision, showing the defect site reconstructed with a full-thickness skin graft.



**Fig. 3.**

The characteristics of the irritated subtype are as follows: (1) onion-skin-like aggregations of eosinophilic squamous epithelial cells (squamous eddies); (2) inflammatory cell infiltrates with a partly lichenoid appearance in the dermis; and (3) possible appearance of acantholysis, dyskeratosis, spongiosis, and apoptotic basal cells. The photograph shows squamous metaplasia with abundant eosinophilic cytoplasm and whorled squamous eddies (white arrows) in the resected tissue (H&E,  $\times 200$ ).



**Fig. 4.**

Six-month postoperative photograph showing good cosmetic results without recurrence.

## References

1. Hafner C, Vogt T. Seborrheic keratosis. *J Dtsch Dermatol Ges* 2008;6:664-77.
2. Konishi E, Nakashima Y, Manabe T, et al. Irritated seborrheic keratosis of the external ear canal. *Pathol Int* 2003;53:622-6.
3. Izquierdo Velasquez JC, Campos Mahecha AM, Duarte Silva JP. Seborrheic keratosis of the external auditory canal. *Otol Neurotol* 2012;33:e61-2.