

IMAGE

Giant extraskelatal chondroma of the hand: A rare case

Raphael Wenny^{1,2}, Michael S. Pollhammer^{1,2}, Dominik Duscher^{1,2,3}, Matthias M. Aitzetmueller³, David J. Haslhofer¹, Georg M. Huemer^{1,2}, Manfred Schmidt^{1,2}

¹Section of Plastic and Reconstructive Surgery, Kepler University Hospital, Linz; ²MAZ–Microsurgical Training and Research Center, Linz, Austria; ³Department of Plastic and Hand Surgery, Technical University Munich, Munich, Germany

Correspondence: Manfred Schmidt
Section of Plastic and Reconstructive Surgery, Kepler University Hospital, Krankenhausstrasse 9, A-4020 Linz, Austria
Tel: +43-732-7806-73005, Fax: +43-732-7806-3190
E-mail: manfred.schmidt@akh.linz.at

Received: 15 Jun 2017 • Revised: 26 Jan 2018 • Accepted: 3 Feb 2018
pISSN: 2234-6163 • eISSN: 2234-6171
<https://doi.org/10.5999/aps.2017.01053>
Arch Plast Surg 2018;45:388-389



Copyright © 2018 The Korean Society of Plastic and Reconstructive Surgeons
This is an Open Access article distributed under the terms of the Creative Commons Attribution Non-Commercial License (<http://creativecommons.org/licenses/by-nc/4.0/>) which permits unrestricted non-commercial use, distribution, and reproduction in any medium, provided the original work is properly cited.

Extraskelatal soft tissue chondroma (ESTC) is an extremely rare benign hyaline cartilaginous tumor that almost exclusively occurs in the soft tissue of the hands and feet. To correctly diagnose cases of chondroma, clinical, radiological, and cytological investigations are essential [1,2]. An X-ray should be performed as first imaging step, in order to plan surgery precisely. To eliminate bone involvement, magnetic resonance imaging (MRI) is obligatory, and to confirm the diagnosis of ESTC, histological staining should be performed [3].

With the patient's approval, we report the case of a 54-year old man with symptoms of ulnar nerve compression due to a giant ESTC of the left hand (Fig. 1). A physical examination, plain radiographs, and MRI revealed a 4 × 7 cm soft tissue tumor with hyperintense T2 (Fig. 2) and moderately hypointense T1 MRI signaling located at the hypothenar area with no bone involvement. After verification by histology, excisional biopsy and ulnar nerve decompression were performed (Fig. 3). Pathological examination confirmed the suspected diagnosis of ESTC. The patient's postoperative recovery was unremarkable and no sign of neurological deficit, pain, or recurrence was observed at follow-up (Fig. 4).

ESTC is a particularly infrequent soft-tissue tumor

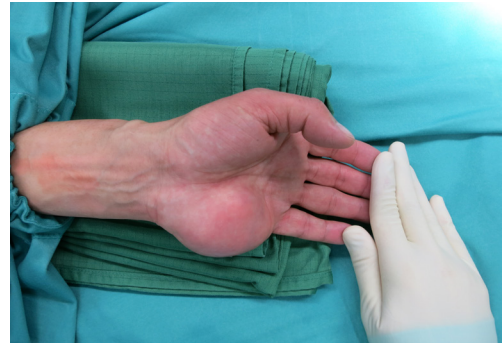

Fig. 1. Preoperative image of the large tumor in the left palm.

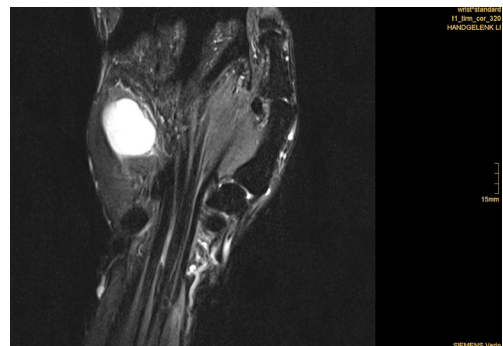


Fig. 2. Soft tissue tumor with a hyperintense T2 magnetic resonance imaging signal.

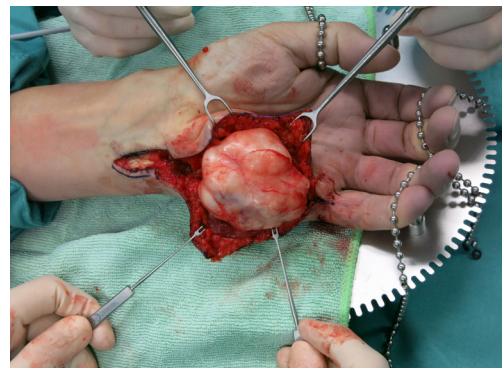


Fig. 3. Tumor removal was achieved by longitudinal splitting of the expanded hypothenar muscle fibers.

of the hand. After the diagnosis of ESTC, the first-line therapy is excisional biopsy [4]. The reported local recurrence rates of chondromas are relatively high, so total resection including the capsule should be performed for prophylactic reasons [5]. Since extraskelatal chondromas are often located in close proximity to vulnerable anatomical structures in the hand, it is important to balance radical excision with

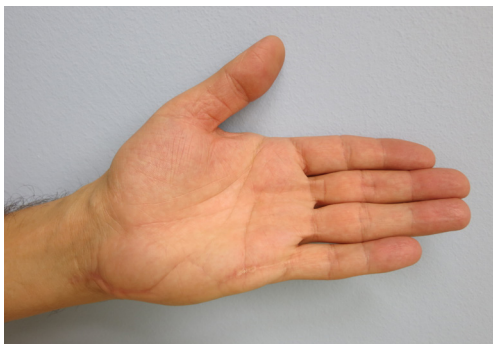


Fig. 4.

Clinical results at a 9-month follow-up with inconspicuous scars and a restored hypothenar contour. The functional outcomes were excellent, with unimpaired ulnar nerve motor function and normal sensitivity.

the preservation of functional structures in this region. Profound hand surgical expertise is needed for the removal of large ESTCs to allow for full functional recovery after tumor resection.

Notes

Conflict of interest

No potential conflict of interest relevant to this article was reported.

Ethical approval

The study was performed in accordance with the principles of the Declaration of Helsinki. Written informed consents were obtained.

Patient consent

The patient provided written informed consent for the publication and the use of his images.

References

1. Bahnassy M, Abdul-Khalik H. Soft tissue chondroma: a case report and literature review. *Oman Med J* 2009;24:296-9.
2. Chung EB, Enzinger FM. Chondroma of soft parts. *Cancer* 1978;41:1414-24.
3. Zlatkin MB, Lander PH, Begin LR, et al. Soft-tissue chondromas. *AJR Am J Roentgenol* 1985;144:1263-7.
4. Suganuma S, Tada K, Tsuchiya H. Giant extraskeletal chondroma of the index finger: a case report. *J Plast Reconstr Aesthet Surg* 2011;64:1377-9.
5. Ikeda K, Osamura N, Kasashima S. A large extraskeletal chondroma in the hand of an elderly patient: a case report. *Hand Surg* 2013;18:111-4.