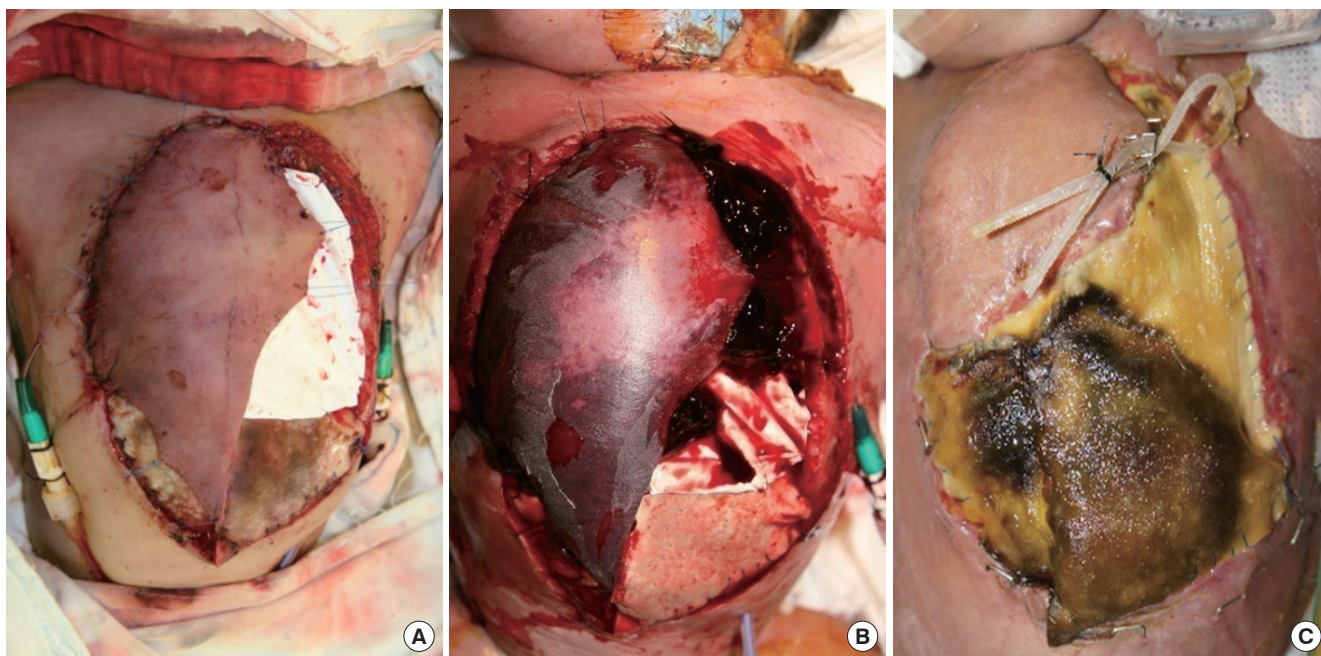

**Fig. 3.**

The thoracoabdominal wall could not be totally covered with the latissimus dorsi myocutaneous free flap; therefore, Permacol was applied to the remaining defect measuring about 12 cm × 7 cm. (A) Immediately after flap transfer, generalized congestion was noted. (B) On postoperative day 2, the peripheral of the flap started to necrotize. (C) After debridement of the devitalized part, two-thirds of the flap survived and functioned as the covering of the heart on postoperative day 42.

## References

1. Spencer R. Conjoined twins: developmental malformations and clinical implications. Baltimore, MD: Johns Hopkins University Press; 2003.
2. Lehr HB, Berggren RB, Lotke PA, et al. Permanent survival of preserved skin autografts. *Surgery* 1964;56:742-6.
3. Jackson OA, Low DW, Larossa D. Conjoined twin separation: lessons learned. *Plast Reconstr Surg* 2012;129:956-63.
4. Zuker RM, Filler RM, Lalla R. Intra-abdominal tissue expansion: an adjunct in the separation of conjoined twins. *J Pediatr Surg* 1986;21:1198-200.
5. Van Landuyt K, Hamdi M, Blondeel P, et al. Free perforator flaps in children. *Plast Reconstr Surg* 2005;116:159-69.

## Transient Exotropia after Open Reduction of a Naso-Ethmoidal-Orbital Fracture

Su Han Park, Woo Young Choi, Kyung Min Son, Ji Seon Cheon, Jeong Yeol Yang

*Department of Plastic and Reconstructive Surgery, Chosun University School of Medicine, Gwangju, Korea*

**Correspondence:** Kyung Min Son  
Department of Plastic and Reconstructive Surgery, Chosun University School of Medicine, 365 Pilmun-daero, Dong-gu, Gwangju 61453, Korea  
Tel: +82-62-220-3180, Fax: +82-62-225-0996  
E-mail: 8love17@hanmail.net

No potential conflict of interest relevant to this article was reported.

Received: 17 Jul 2015 • Revised: 12 Oct 2015 • Accepted: 4 Nov 2015  
pISSN: 2234-6163 • eISSN: 2234-6171  
<http://dx.doi.org/10.5999/aps.2016.43.1.99>  
*Arch Plast Surg* 2016;43:99-102

Copyright © 2016 The Korean Society of Plastic and Reconstructive Surgeons  
This is an Open Access article distributed under the terms of the Creative Commons Attribution Non-Commercial License (<http://creativecommons.org/licenses/by-nc/3.0/>) which permits unrestricted non-commercial use, distribution, and reproduction in any medium, provided the original work is properly cited.

Exotropia is a form of strabismus in which the eyes turn outward, and can involve various etiologies, durations, and degrees of deviation [1]. Exotropia is caused by the dysfunction of ocular movement resulting from brain damage, nerve injury, or muscle

injury. In particular, acquired exotropia is caused by facial trauma, especially blow-out fractures [2]. Generally, cases of acquired exotropia are related to mechanical entrapment of the medial rectus muscle or soft tissue, as confirmed by physical examination and computed tomography (CT). The mechanical entrapment is relieved by surgery [3]. However, some cases are asymptomatic, involving unchecked dysfunction of the ocular muscles caused by a nerve injury and resulting in retraction of the muscle. In this report, we describe a case of transient exotropia after the open reduction of a naso-ethmoidal-orbital fracture without mechanical entrapment.

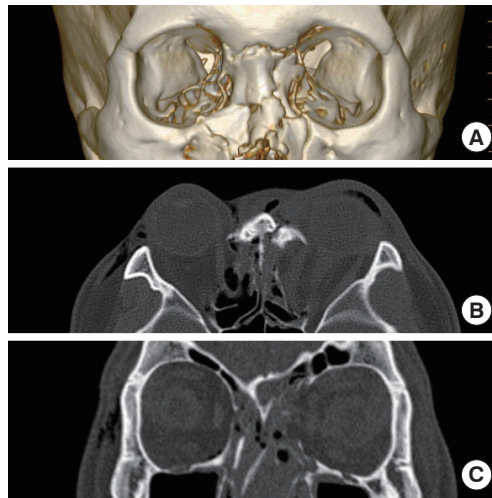
A 39-year-old male visited the emergency room of our hospital after a motor vehicle accident. A type II bilateral naso-ethmoidal-orbital fracture without medial rectus muscle entrapment (Fig. 1) was diagnosed on a CT scan. On physical examination, diplopia and exotropia were absent, cardinal ocular movement was not limited, and all ocular functions,

including intraocular pressure (IOP) and eyesight, were normal.

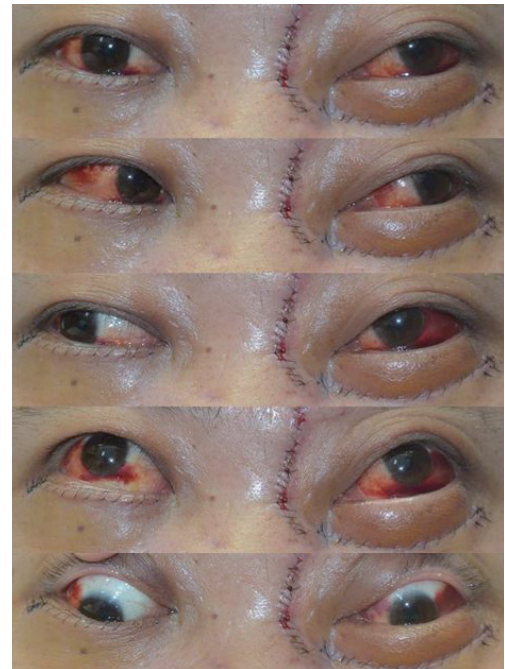
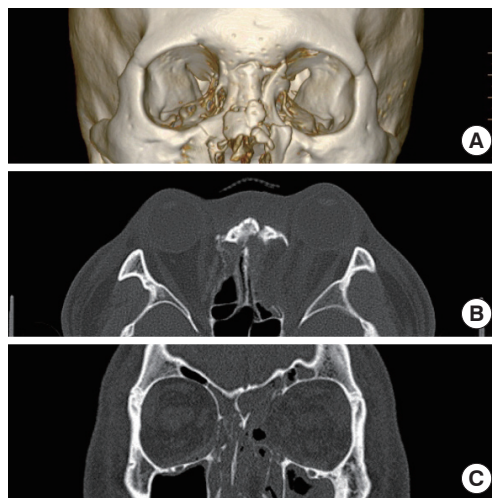
After monitoring the edema around the patient's eyes for eight days, we performed open reduction and internal fixation of the frontal bone via direct incision and orbit wall reconstruction with bio-resorbable copolymers (Inion, Weston, FL, USA; 1.5-mm mesh) via subciliary skin muscle flap incision were performed under general anesthesia. The intraoperative forced duction test and the medial rectus muscle were normal, with no signs of entrapment.

On the first postoperative day, serious edema and pain during ocular movement appeared in the left eye. In addition, diplopia and limitation of ocular movement were noted (Fig. 2). Every day until the third postoperative day, in conjunction with the department of ophthalmology, the exotropia in the patient's left eye was evaluated, and the IOP, light reflexes, and fundoscopic findings were normal. Hertel's exophthalmometer confirmed and quantified the extent of exophthalmia of the left eye, with protrusion of 13 mm in the right eye and 16 mm in the left eye. Examination of the ocular movement associated with strabismus confirmed 70 prism diopters of exotropia and 25 prism diopters of hypertropia in the left eye. These symptoms lasted

**Fig. 1.** Preoperative computed tomography view of a type II bilateral naso-ethmoidal-orbital fracture. (A) Three-dimensional view. (B) Two-dimensional axial view. (C) Two-dimensional coronal view.



**Fig. 2.** Computed tomography imaging performed on the eighth postoperative day. The inserted plate was non-specific and no muscle entrapment was observed. (A) Three-dimensional view. (B) Two-dimensional axial view. (C) Two-dimensional coronal view.



**Fig. 3.** Postoperative day two. The patient complained of diplopia, mild exotropia, and limitation of ocular movement, especially in the downward and medial gazes.

until the eighth postoperative day, with non-specific CT findings (Fig. 3). We therefore planned surgical exploration.

When propofol (Anefol) and rocuronium bromide (Esmeron) were administered for general anesthesia, the normal axis of the left globe in the front-facing gaze appeared to recover, and the forced duction test was in the normal range. Nonetheless, exotropia and limitation of ocular movement in the left eye were still present in an ocular examination performed immediately after the operation (Fig. 4).

Steroid injection therapy (5 mg of dexamethasone, 1 ampule intravenously, three times per day) and a muscle relaxant (Mulex, 1 tablet orally, two times per day) were administered to the patient for five days. No dramatic effect occurred, as when the patient was under general anesthesia, but the exotropia and limitation of ocular movement improved gradually, as well as the patient's discomfort.

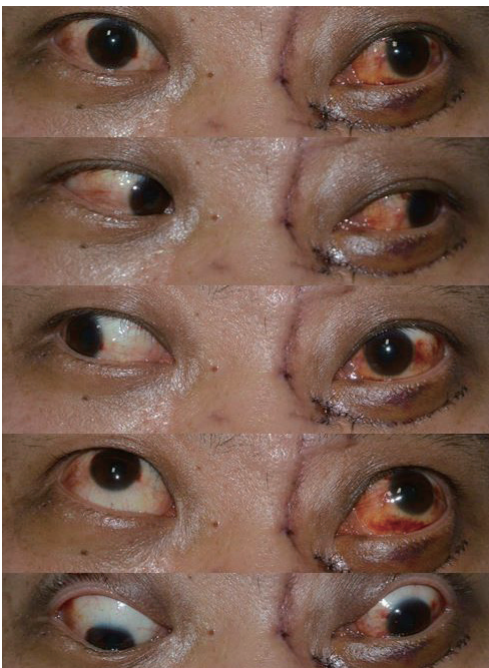
The patient was discharged from the hospital seven days after exploration and 15 days after the first operation. The patient's symptoms were evaluated one week, two weeks, one month, and four months after surgery. The patient had normal ocular movement and function, with no complications observed over nine months of monitoring (Fig. 5).

Ocular movement is regulated by the interaction of the four rectus muscles and two oblique muscles

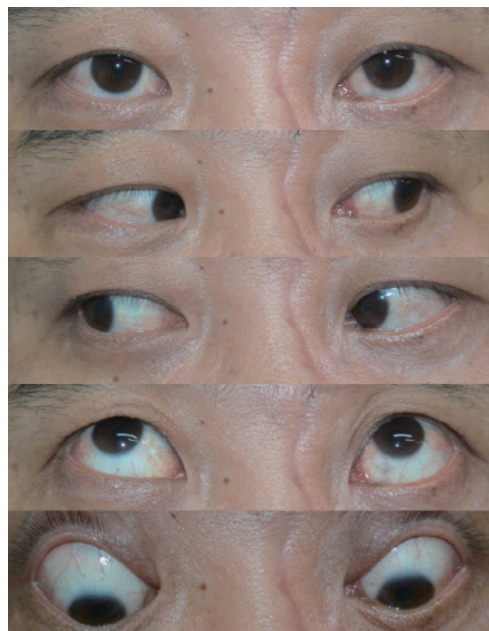
that act jointly or separately, depending on whether the nerves innervating the muscles are intact and functioning. Damage to one or more of these muscles or nerves leads to a disruption of the interaction among the ocular muscles, which may cause symptoms such as diplopia or limitation of ocular movement [4]. Mechanical entrapment of the medial rectus muscle or the soft tissue is the most common cause of exotropia. In our case, mechanical entrapment was absent and the exotropia improved briefly in response to a muscle relaxing agent (Esmeron) alone, without the application of external force. The Mulex used postsurgically had no additional effect, but the patient's symptoms then resolved spontaneously.

Intraoperatively, none of the ocular muscles were found to be trapped and the implant was located in the correct position. It is likely that our patient suffered from dysfunction of the medial rectus and superior oblique muscles due to intraoperative retraction and the resulting external force generated by the eyeball. The exotropia was possibly caused by an imbalance in muscle tonus that led to the appearance of normal function of the superior and lateral rectus muscle when the medial rectus and superior oblique muscle had functionally deteriorated.

We experienced a case of transient exotropia with spontaneous recovery after the open reduction of a naso-ethmoidal-orbital fracture without mechanical entrapment.



**Fig. 4.** Postoperative view two hours after surgical exploration. The left eye symptoms were still present.



**Fig. 5.** Postoperative view at nine months. The exotropia and limitation of ocular movement in the left eye had completely recovered.

## References

1. Mohnhey BG, Huffaker RK. Common forms of childhood exotropia. *Ophthalmology* 2003;110:2093-6.
2. Duane TD, Schatz NJ, Caputo AR. Pseudo-Duane's retraction syndrome. *Trans Am Ophthalmol Soc* 1976;74:122-32.
3. Gittinger JW Jr, Hughes JP, Suran EL. Medial orbital wall blow-out fracture producing an acquired retraction syndrome. *J Clin Neuroophthalmol* 1986;6:153-6.
4. Gao Z, Guo H, Chen W. Initial tension of the human extraocular muscles in the primary eye position. *J Theor Biol* 2014;353:78-83.

## Excision of a Lower Eyelid Inflammatory Pseudotumor Combined with Lower Blepharoplasty

Min-Suk Kang<sup>1,2</sup>, Eui-Cheol Jeong<sup>1</sup>

<sup>1</sup>Department of Plastic Surgery, SNU-SMG Boramae Medical Center, Seoul; <sup>2</sup>Department of Plastic Surgery, Seoul National University Hospital, Seoul National University College of Medicine, Seoul, Korea

**Correspondence:** Eui-Cheol Jeong  
Department of Plastic and Reconstructive Surgery, SMG-SNU Boramae Medical Center, Seoul National University College of Medicine, 20 Boramae-ro 5-gil, Dongjak-gu, Seoul 07061, Korea  
Tel: +82-2-870-2331, Fax: +82-2-831-2826  
E-mail: ejeong.md@gmail.com

This article was presented as a poster at the 2014 International 72nd Congress of the Korean Society of Plastic and Reconstructive Surgeons on November 7-9, 2014 in Seoul, Korea.

No potential conflict of interest relevant to this article was reported.

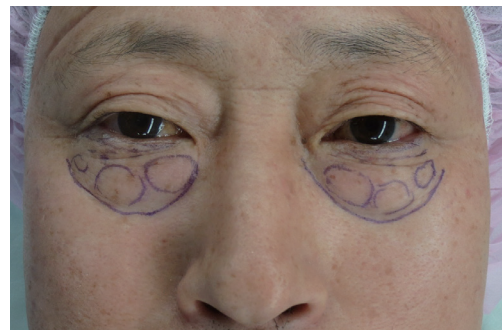Received: 9 Feb 2015 • Revised: 4 Mar 2015 • Accepted: 17 Mar 2015  
pISSN: 2234-6163 • eISSN: 2234-6171  
<http://dx.doi.org/10.5999/aps.2016.43.1.102>  
*Arch Plast Surg* 2016;43:102-104



Copyright © 2016 The Korean Society of Plastic and Reconstructive Surgeons  
This is an Open Access article distributed under the terms of the Creative Commons Attribution Non-Commercial License (<http://creativecommons.org/licenses/by-nc/3.0/>) which permits unrestricted non-commercial use, distribution, and reproduction in any medium, provided the original work is properly cited.

Inflammatory pseudotumor (IPT)—known as the “great mimicker”—is a rare, benign condition mimicking other benign or malignant tumors. It may be found in almost any organ system. Confirmation of a diagnosis of IPT involves a process of exclusion because IPT mimics other malignant or benign tumors. The mainstay treatment of IPT is corticosteroids. However, in cases of orbital

pseudotumor presenting with an eyelid mass, excision of the mass with combined lower or upper blepharoplasty is an aesthetically favorable and appropriate diagnostic option. In the present report, we describe a case of lower eyelid IPT excision combined with lower blepharoplasty. A 57-year-old man presented to our outpatient clinic with mass-like lesions in the right lower eyelid area (Fig. 1). He first noticed the mass 4 months before his outpatient visit. The mass was non-tender and highly movable. Our first clinical impression was that the lesion was an epidermal cyst; however, following ultrasonography, a highly vascularized mass with no definite fluid or abscess pocket formation and nonspecific soft tissue inflammation was detected (Fig. 2). Because the patient also complained of baggy lower eyelids, surgical exploration and excision of the mass in combination with lower blepharoplasty was planned. Through a subciliary approach, two tiny masses were identified in the medial fat pad of the right lower eyelid (Fig. 3). The masses were excised, and biopsy specimens were obtained (Fig. 4A). Openings were made at the orbital septum, and fat was partially removed for the correction of the bulging of the lower eyelid. Lower blepharoplasty was then performed for the opposite side in a similar manner (Fig. 5). The patient was discharged 1 day after surgery. The patient seemed very satisfied with the results, and the stitches were removed on postoperative day 6. Biopsy results showed chronic sclerosing inflammation with fibrosis, plasma cell infiltration, and lymphoid aggregates with multinucleated giant cells and several



**Fig. 1.** A 57-year-old man presented to the outpatient center with a palpable mass around the right lower eyelid. Because he complained of baggy lower eyelids, we decided to confirm our diagnosis with an excisional biopsy combined with lower blepharoplasty of both lower eyelids. For the preoperative design, three segments of orbital fat were marked.