

Semicircular Horizontal Approach in Breast Reduction: Clinical Experience in 38 Cases

Hee Su Shin, Yong Hae Lee, Sung Gyun Jung, Doo Hyung Lee, Young Roe, Jong Hyun Cha

Department of Plastic and Reconstructive Surgery, Konyang University College of Medicine, Daejeon, Korea

Original Article

Background Various techniques are used for performing breast reduction. Wise-pattern and vertical scar techniques are the most commonly employed approaches. However, a vertical scar in the mid-lower breast is prominent and aesthetically less pleasant. In contrast, a semicircular horizontal approach does not leave a vertical scar in the mid breast and transverse scars can be hidden in the inframammary fold. In this paper, we describe the experiences and results of semicircular horizontal breast reductions performed by a single surgeon.

Methods Between September 1996 and October 2013, our senior author used this technique in 38 cases in the US and at our institution. We used a superiorly based semicircular incision, where the upper skin paddle was pulled down to the inframammary fold with the nipple-areola complex pulled through the keyhole.

Results The average total reduction per breast was 584 g, ranging from 286 to 794 g. The inferior longitudinal pedicle was used in all the cases. The average reduction of the distance from the sternal notch to the nipple was 13 cm (range, 11–15 cm). The mean decrease in the bra cup size was 1.7 cup sizes (range, a decrease of 1 to 3). We obtained very satisfactory results with a less noticeable scar, no complication such as necrosis of the nipple or the skin flap, wound infection, aseptic necrosis of the breast tissue, or wound dehiscence. One patient had a small hematoma that resolved spontaneously.

Conclusions This technique is straightforward and easy to learn, and offers a safe, effective, and predictable way for treating mammary hypertrophy.

Keywords Breast / Nipples / Mammoplasty

Correspondence: Yong Hae Lee
Department of Plastic and Reconstructive Surgery, Konyang University College of Medicine, 158 Gwanjeodong-ro, Seo-gu, Daejeon 302-718, Korea
Tel: +82-42-600-9210
Fax: +82-42-600-9251
E-mail: yonghlee2001@yahoo.com

This article was presented at the 71st Congress of the Korean Society of Plastic and Reconstructive Surgeons on November 1–3, 2013, in Seoul, Korea.

No potential conflict of interest relevant to this article was reported.

Received: 13 Dec 2014 • Revised: 7 Mar 2015 • Accepted: 18 Apr 2015

pISSN: 2234-6163 • eISSN: 2234-6171 • <http://dx.doi.org/10.5999/aps.2015.42.4.446> • Arch Plast Surg 2015;42:446-452

INTRODUCTION

Reduction mammoplasty is a common procedure in plastic surgery and its use is increasing because of weight gain and aging. Reducing breast volume improves shoulder and back pain, chest discomfort, contact dermatitis, and unpleasant appearance of the body contour [1].

Because breasts are nourished by abundant blood circulation from several directions, various surgical techniques have been

used for breast reduction. Many approaches, including inverted T shape, periareolar incision, snowball shape incision, and vertical incision, were utilized. Further, traditional inferior and central pedicle inverted T-shaped scar methods are very popular [2]. However, most procedures leave a prominent scar in the mid-lower breast, which is aesthetically unpleasant.

In the case of large pendulous breasts in which the nipples are located more than 40 cm from the sternal notch, transposition of the nipples and the mound of the breast with pedicles is con-

strained using conventional techniques. Amputation of the breast with a free graft of the nipple was traditionally recommended in the case of large pendulous breasts [3]. However, grafted nipples ended up flat and discolored and had partial necrosis, making them aesthetically unpleasant [4].

In 1925, Passot [5] described the transposition of the nipple-areolar complex into a buttonhole incision more cephalically on the breast mound, which results in no vertical scar on the reduced breast. In 2003, Lalonde et al. [6] described the no-vertical-scar breast reduction that allows removal of the vertical scar portion of the inferior pedicle-wise pattern T scar. We referred to the Passot and Lalonde technique. We used a superiorly based semicircular flap whose upper skin paddle was pulled down to the inframammary fold and the nipple-areola complex was pulled out through the keyhole at the proper position. This approach does not leave a vertical scar in the mid breast and only one transverse scar, which is hidden within the inframammary fold. Another benefit of this procedure is that the nipples can be easily transposed to the proper position and the mound of the breast contour [6,7]. This article describes the reported series of horizontal breast reduction performed by a single surgeon. The authors discuss their experience here.

METHODS

Between September 1996 and October 2013, our senior author used this technique in 38 cases (76 breasts) in the US and at our institution. Patient characteristics were then analyzed, including, age, body mass index, ethnicity, significant weight gain, preoperative and postoperative brassiere size, preoperative and postoperative distance from the sternal notch to the nipple, several preoperative and postoperative macromastia-related symptoms (back, neck, or shoulder pain; chest discomfort; rashes and/or itching; and painful brassiere strap grooving) and postoperative complications. The weight of the excised breast tissue was measured in the operating room. Patients were generally seen at 6 weeks, 4 months, 8 months, 1 year, and 2 years. Measurements of the brassiere size and the distance from the sternal notch to the nipple were performed 4 months after surgery. Patients were then analyzed on the basis of the change in the bra cup size. The decrease in cup size, not a unit width of the breast, was used alone. For example, a change in bra size from D to C was noted as a decrease of one cup size (Table 1). We asked patients about the macromastia-related symptoms they experienced before and after surgery (at 8 months postoperatively). The patients were asked to give a subjective rating on a scale of 1 to 10, corresponding to the symptoms (Table 2).

Design

Before surgery, with the patient in the standing position, an indelible marker is used to mark a superiorly based smooth curve lineal line as the superior pedicle, which will be pulled down to the inframammary fold. This semicircular design should aim for a proper breast mound. As a result considering the size of the chest, the width of the upper flap should measure approximately 11–12 cm. Nipples are pulled out through the keyhole at the proper location (Fig. 1) [5]. Penn [8] proposed that the ideal distance from the sternal notch to the nipple is 21 cm. The general consensus is that a satisfactory measurement from the sternal notch to the nipple ranges from 19 to 21 cm, equivalent to the fourth intercostal space and the mid level of the humerus, and both the torso length and the thoracic cage dimensions must be considered when determining proper nipple location [9]. The distance from the nipples to the inframammary fold should be 5–6 cm (Fig. 2A); this distance is important for preventing a recurrence of the ptosis of the breast or nipples [6]. In case the upper skin paddles are not long enough in a moderate-size breast, we make a small semicircular marking on the middle of the inframammary fold, compensating for the shortness of the upper skin flap. In more detail, if the distance between the lower border of the semicircular line from the upper border of the nipple areola complex is less than 6 cm, we design a semicircular flap with insufficient distance to the inframammary fold (Fig. 2B). For achieving a minimal areolar scar, the periareolar scar can be designed to be tension free. We do this by measuring the areola at 4.0–5.0 cm with the patient in the sitting position. We then draw the new areola site circle at 2.5–3.0 cm [6].

Surgical technique

The procedure was performed with the patient in the supine position, with arms abducted on arm boards. However, the arm should not be at a right angle, because this can distort the breast shape at the time of closure. Initially, a tumescent solution is injected into the dermal layer of the inferior pedicle, aiming for easier de-epithelialization and less bleeding during dissection. To prevent necrosis of the flap, the inferior pedicle should be 2.5 cm in thickness and at least 9 cm in width (Fig. 3). The upper skin flap is elevated between the subcutaneous tissue and Scarpa's fascia reaching the upper end of the breast. The upper skin flap should be kept relatively thick in order to maintain as much superior fullness as possible. Therefore, the thickness of the upper skin flap should be at least 1.5 cm (Fig. 3). Upper flap elevation to the clavicle is not necessary. The breast tissue is then removed from the upper, lower medial, and lower lateral portions of the breast, leaving enough tissue in the inferior longitudinal pedicle to provide good mounting of breast size and shape (Fig.

Table 1. Patient characteristics and results

Patient	Age (yr)	Race	BMI (kg/m ²)	SN to NAC (cm)		Brassiere size (cup)		Reduction Vol per breast (g)	
				Preop	Postop	Preop	Postop	Rt	Lt
1	47	Caucasian	34	34	21	D	C	535	548
2	44	Caucasian	33.9	35	21	DD	C	546	569
3	64	Caucasian	33.6	38	22	DD	C	522	516
4	45	Black	38.1	40	23	DDD	D	789	781
5	53	Caucasian	32.8	32	21.5	D	C	455	451
6	41	Caucasian	34.4	30.5	22	DD	C	520	511
7	59	Caucasian	36.2	35	21.5	DD	C	571	588
8	53	Caucasian	32.5	32.5	21	D	C	434	439
9	51	Caucasian	33.6	33	21	DD	C	592	603
10	41	Caucasian	35	32	21.5	DD	C	586	588
11	43	Caucasian	31.2	31	21.5	D	C	421	429
12	60	Black	35	39	22.5	DD	C	682	685
13	49	Caucasian	31.6	33	21	D	C	496	513
14	45	Caucasian	35.8	35	22	DD	C	574	559
15	52	Caucasian	34.3	35	21.5	DD	C	572	584
16	50	Caucasian	37.2	38.5	22	DDD	D	682	698
17	42	Caucasian	31.6	31.5	21	DD	C	560	572
18	47	Caucasian	38.4	41	22.5	DDD	D	751	733
19	55	Caucasian	36.2	36	22	DD	C	542	530
20	43	Caucasian	34.2	32	21	DD	C	551	531
21	46	Caucasian	36.8	37	21.5	DDD	C	705	711
22	45	Caucasian	38.5	35.5	21.5	DD	C	656	671
23	44	Caucasian	32.4	30.5	21	D	C	428	436
24	62	Caucasian	34.2	40	22	DDD	D	793	762
25	51	Caucasian	34.7	34	21.5	DD	C	567	559
26	48	Caucasian	33.6	32	21	D	C	578	601
27	67	Caucasian	35.1	42	24	DDD	D	789	794
28	45	Black	37.2	38	22.5	DD	C	572	578
29	42	Caucasian	31.	34	21	D	C	514	507
30	48	Black	32.9	33.5	21.5	D	C	466	442
31	51	Caucasian	33.2	35	22	DD	C	571	592
32	44	Caucasian	36.9	33	21.5	DDD	C	699	704
33	58	Caucasian	35.7	33	22	DD	D	582	585
34	43	Caucasian	32.4	31.5	21	D	C	506	519
35	45	Caucasian	31.2	31	21	D	C	475	472
36	53	Caucasian	35.4	36	22.5	DD	D	559	574
37	43	Asian	30.1	31	21.5	D	C	309	313
38	52	Asian	31.5	30.5	21	D	C	286	301

BMI, body mass index; SN to NAC, mean distance from sternal notch to nipple for both breasts; Preop, preoperatively; Postop, postoperatively; Vol, volume; Rt, right; Lt, left.

Table 2. Complication

Complication	No. of patients
Necrosis of nipple or skin flap	0
Wound infection	0
Sensory change	0
Aseptic necrosis of breast tissue	0
Dehiscence of wound	0
Hematoma	1
Seroma	0

4A, B). A majority of the breast tissue is removed from the lateral segment. The redundant breast tissue is located laterally, par-

ticularly in the excessively large pendulous breast. There should not be too much lateral traction while holding the lateral segment to prevent excessive undermining of the inferior pedicle. After excision of the breast tissue, the upper flap is pulled gently to the inframammary line and sutured. The length of the upper flap can be modified with the creation of a small semicircular flap in the lower end of the middle inframammary fold in the case of insufficient length of the upper skin flap.

At the new location of the nipple, circular markings are made, which are smaller than the actual size of the nipple because holes for the nipple-areola complex are stretched out and become larger. Through the hole, the nipple is delivered and sutured with

Fig. 1. Preoperative design

Superiorly based semicircular line: medial end of the inframammary fold to lateral end of the inframammary fold. Nipple position, distance between the midclavicular line and the new nipple-areola complex: 19–21 cm.

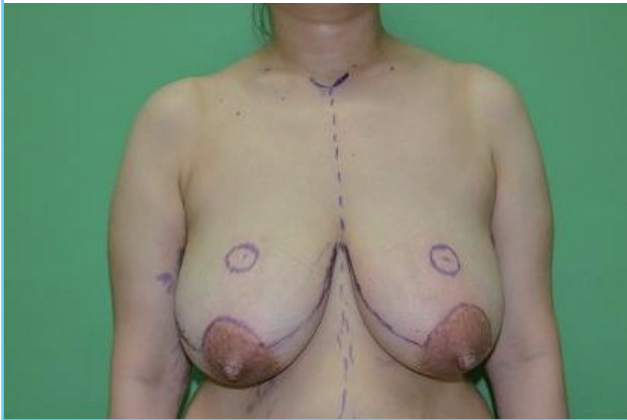


Fig. 3. Upper skin flap and inferior pedicle

Thickness of the upper skin flap should be at least 1.5 cm. Thickness of the inferior pedicle should be 2.5 cm, and the width should be at least 8 cm.

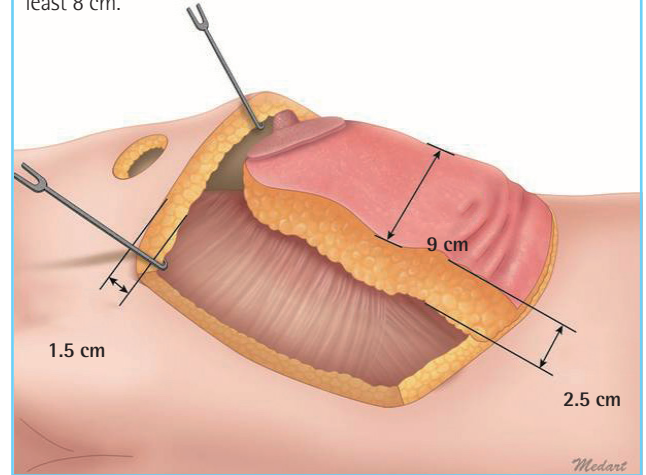


Fig. 2. Preoperative design

(A) New location of the nipple: a circular margin is made which is smaller than the nipple. (B) Distance between the lower end of the semicircular line to the nipple-areola complex (a+b): 5–6 cm.

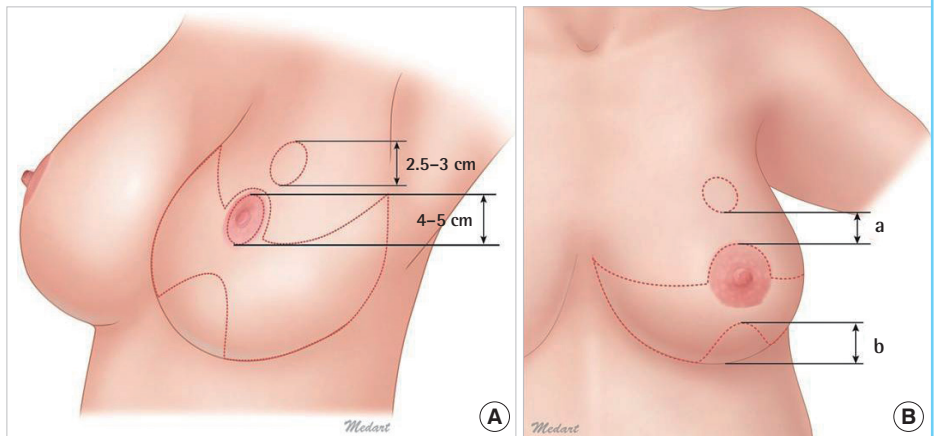
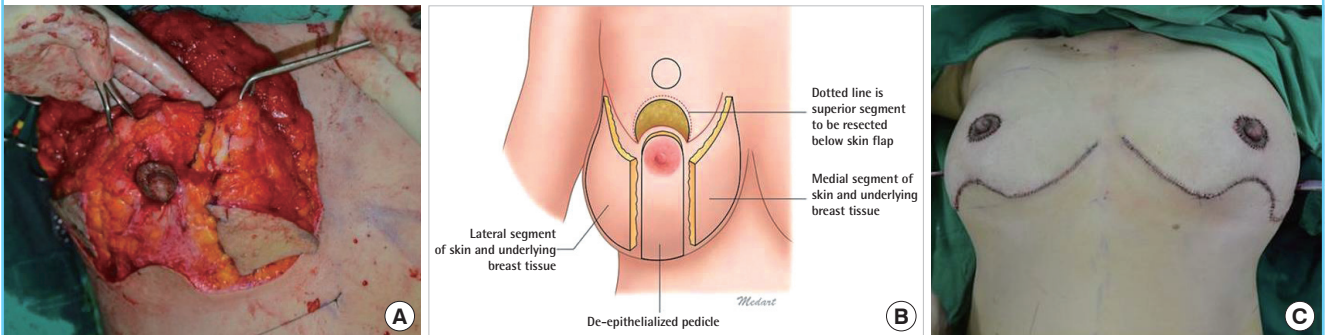


Fig. 4. Intraoperative view

Operative technique for semicircular horizontal reduction mammoplasty using inferior dermoglandular pedicle for transposition of the nipple-areola complex. (A) Excision of *en bloc* is performed. The inferior dermoglandular pedicle is 2.5 cm thick. (B) Outline of the two segments to be resected the medial and lateral; yellow and dotted line: superior segment to be resected below the skin flap. (C) Closure of the breast.

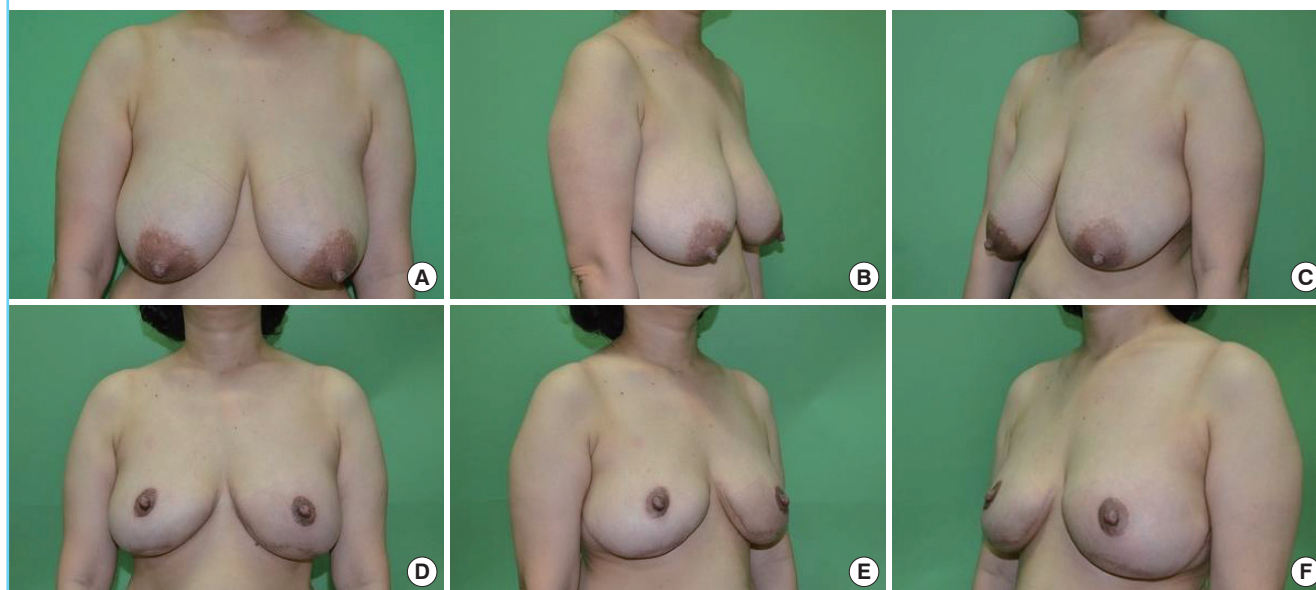


minimal tension. The nipples should be located 19–21 cm from the sternal notch or the midclavicular line and 9–11 cm from

the midline on symmetrical locations. The inframammary fold incision is closed, and a drain is placed in each breast (Fig. 4C).

Fig. 5. Preoperative and postoperative view

(A-C) A patient (Table 1, patient 37) with large pendulous breasts has a lower location of the nipple-areola complex. The distance from the sternal notch to the nipple is 31 cm. (D-F) Four months after surgery. The distance from the sternal notch to the nipple is 21.5 cm. The patient has maintained a good contour with minimal bottoming out. Further, the scars around the areola are excellent.



RESULTS

The average age of the patients was 49.2 years (range, 41–67 years). The average body mass index was 34.3 kg/m² (range, 30.1–38.5 kg/m²). The average total reduction per breast was 584 g, ranging from 286 to 794 g. The inferior longitudinal pedicle was used in all cases. The average specimen weight was 564 g (range, 286–793 g) for the right breast and 567 g (range, 301–794 g) for the left breast. The average follow-up period was 18 months (range, 0.3–2 years). Preoperatively, the average distance from the sternal notch to the nipple was 34.6 cm (range, 30.5–42 cm) for both breasts. Postoperatively, the average distance from the sternal notch to the nipple was 21.6 cm (range, 21–24 cm) for both breasts. The average reduction of the distance from the sternal notch to the nipple was 13 cm (range, 11–15 cm). Preoperatively, the median bra size was a DD cup. Postoperatively, the median bra size was a C cup. Patients reported a mean decrease in bra cup size of 1.7 cup sizes (range, decrease of 1 to 3). During follow-up, there were no patients with significant weight gain (Table 1).

The effect of reduction mammoplasty on several macromastia-related symptoms was assessed. The semicircular horizontal reduction mammoplasty resulted in significant decreases in all macromastia-related symptoms analyzed, including back pain (preoperatively vs. postoperatively, 5.5 vs. 1.2), neck pain (5.8 vs. 1.2), shoulder pain (3.8 vs. 1.3), chest discomfort (6.8 vs. 1.1), rashes and/or itching (3.2 vs. 1.5), and painful brassiere

Table 3. Macromastia associated symptoms

Characteristic	Preoperatively (range)	Postoperatively (range)	Pain relief rate
Back	5.5 (4–7)	1.2 (0–2)	2.5
Neck	5.8 (3–7)	1.2 (0–3)	2.7
Shoulder	6.2 (4–7)	1.3 (0–2)	2.9
Discomfort of the chest	6.8 (4–7)	1.1 (0–3)	3.4
Rash and/or itching	3.2 (4–7)	1.5 (0–2)	1
Painful brassiere strap grooving	5.3 (4–7)	1.4 (0–2)	2.3

Pain relief rate, decrease pain score per a breast cup size reduction.

strap grooving (5.3 vs. 1.4). We have tried to quantify the symptoms according to the breast cup size reduction (decrease pain score per breast cup size reduction). As a result, the back pain score was 2.5, neck pain score was 2.7, shoulder pain score was 2.9, chest discomfort score was 3.4, rash and/or itching score was 1, and painful brassiere strap grooving score was 2.3 per breast cup size reduction (Table 2).

We obtained a very satisfactory outcome with the least noticeable scar (Fig. 5). No complication was observed, such as necrosis of the nipple or skin flap, wound infection, sensory change, aseptic necrosis of breast tissue, or wound dehiscence. One patient had a small hematoma that resolved spontaneously (Table 3).

DISCUSSION

As our data unequivocally demonstrate, semicircular horizontal

reduction mammoplasty provides significant improvement for patients with respect to macromastia-related symptoms. Chest discomfort resulted in the most dramatic decrease. These findings are consistent with those of several prior studies that have analyzed the effect of reduction mammoplasty on patient well-being. Although several authors have reported their experience with horizontal reduction mammoplasty, our study mostly focused on patient outcomes [6,7]. We have quantified the symptoms according to the breast cup size reduction. If the data are accumulated on an ongoing basis, it will provide useful information in the field of breast reduction.

Fewer complications occurred with this technique than described in previous articles. The fact that necrosis of the nipple-areola complex never occurred in 38 cases is related to pedicle choice and design. The lateral thoracic artery, thoraco-acromial artery, internal mammary artery, and intercostal arteries that supply blood from anterior and posterior directions are the dominant arteries providing blood circulation to the breast [10,11]. Preserving the routes of this circulation is important for proper wound healing and preventing necrosis of the skin flap and aseptic necrosis of breast tissue. Reserving all dominant blood circulation reduces the risk of skin flap necrosis and nipple areolar necrosis [6,7].

We did not experience a sensation change. Sensory innervation of the breast has three major nerve distributions, namely anterior lateral intercostals, medial intercostals, and the cervical plexus. Branches of the cervical plexus provide superior medial sensory innervation. These fibers course superficially in the subcutaneous tissue and are usually undisturbed by the surgical elevation of the upper breast skin flap. Intercostal segmental nerves contribute the remainder of the breast sensation and can be considered the primary sensory nerves [12]. The upper skin flap is elevated between the subcutaneous tissue and Scarpa's fascia. Therefore, the subdermal plexus can be preserved.

Blood loss is decreased with this technique. The use of an infiltration solution containing epinephrine, an excision *en bloc* of breast tissue, and thorough cautery of all bleeding vessels contribute to hemostasis. No patient has ever required a blood transfusion.

It is recognized that the excessive skin undermining of vertical reduction mammoplasty leads to delayed healing [13]. Delayed wound healing did not occur in the cases considered in our study because skin undermining was avoided, and when the excision deep into the skin, minimal dissection of breast tissue was carried out laterally and superiorly; the upper skin flaps were maintained to be at least 1.5 cm thick throughout their length, and it was ensured that the inferior pedicle did not have too much lateral traction while the lateral segment was held.

Ideally, this surgical technique has been utilized in reduction mammoplasty to obtain proper breast shape and size, and an acceptable scar on large breasts, particularly when the nipple is located more than 40 cm from the sternal notch and more than 20 cm of transposition of the nipples is required. The conventional transverse bi-pedicle, longitudinal pedicle flap, upper lateral pedicle, transposition of the nipple, and mounting of breast method are technically contraindicated [14]. In the past, amputation of the large pendulous breast with a free nipple graft was utilized in reduction mammoplasty [3,15]. Gradingier [4] reported achieving satisfactory results by using nipple-areola transplantation. However, in our experience, amputation of the breast with a free nipple graft does not yield an aesthetically pleasing shape of the breast and shape of nipples because of flat deformation, discoloration, and partial necrosis of the nipple-areola complex. In the initial phase of this study, a patient presented with gigantomastia. Instead of amputating the breast, the semicircular horizontal technique of the skin with a smooth, semicircular incision in the upper skin flap was designed.

This technique can be applied to breasts of moderate size as well as large pendulous breasts by adjusting the design, thereby avoiding amputation. Perhaps, the most important advantage of the semicircular horizontal technique, particularly from the patient's perspective, is the elimination of the longitudinal scar in the center of the breast, which is the most noticeable. This technique does not involve the use of complicated, multiple flap rotations; thus, the final scars include the scar around the nipple-areola complex and at the inframammary sulcus only. A transverse scar can be hidden within the inframammary fold and is less visible without a vertical scar on the midline [6]. The surgical procedure is very simple in terms of flap design and dissection [6]. Our technique requires a shorter operating time than other techniques. We were able to shorten the operating time by 30–40 minutes as compared to other conventional vertical techniques [16].

The horizontal breast reduction can result in a boxy shape of the breast and tends to show a decrease in the projection of the breast mound [17,18]. For the improvement of projection and shape, a proper amount of tissue should be reserved in the inferior central flap and a significant amount of the breast tissue attached to the upper skin flap. This leaves a significant amount of breast tissue in the upper skin flap, which has several benefits. It can minimize the flatness of the upper breast and can reduce the mechanical force on the lower breast. This reduces the secondary bottoming out. Elevation of the upper flap to the clavicle is not necessary. Excessive dissection can lead to the problem of blood flow and the upper flap can drop over time. Further, for proper mounting of the breast, the width or semicircular line

should be designed properly. If the semicircular line is too flat, the breast mound becomes flat and boxy. We adjust the width of the upper flap by approximately 11–12 cm considering the chest size. The width of the breast can be adjusted through the lateral and medial resections of the upper breast tissue. However, our method is more effective when the distance from the nipple to the sternal notch is 28–33 cm.

In 2003, Lalonde et al. [6] published a horizontal reduction mammoplasty technique similar to our technique. However, there are some differences between these two techniques in that the semicircular line is more concave and the width adjustment is possible by using lateral and medial resection of the upper breast.

We obtained acceptable breast reduction results by using this technique. The semicircular horizontal mammoplasty is easy to design, can be modified according to breast size and shape, and has consistently produced good breast shape. A semicircular scar can be hidden in the inframammary fold and is less visible without a vertical scar on the midline. This technique is straightforward and easy to learn, and offers a safe, effective, and predictable way to treat moderately sized and large pendulous breasts.

REFERENCES

1. Kalliainen LK; ASPS Health Policy Committee. ASPS clinical practice guideline summary on reduction mammoplasty. *Plast Reconstr Surg* 2012;130:785-9.
2. Hidalgo DA, Elliot LF, Palumbo S, et al. Current trends in breast reduction. *Plast Reconstr Surg* 1999;104:806-15.
3. Mathes SJ. *Plastic surgery*. Vol. 6. Philadelphia: Saunders Elsevier; 2006.
4. Gradinger GP. Reduction mammoplasty utilizing nipple-areola transplantation. *Clin Plast Surg* 1988;15:641-54.
5. Passot R. La correction esthetique du prolapsus mammaire par le procede de la transposition du mamelon. *Presse Med* 1925;33:317-8.
6. Lalonde DH, Lalonde J, French R. The no vertical scar breast reduction: a minor variation that allows to remove vertical scar portion of the inferior pedicle wise pattern T scar. *Aesthetic Plast Surg* 2003;27:335-44.
7. White CP, Hynes NM. The horizontal breast reduction: surgical tips for maintaining projection. *Can J Plast Surg* 2013;21:167-72.
8. Penn J. Breast reduction. *Br J Plast Surg* 1955;7:357-71.
9. Westreich M. Anthropomorphic breast measurement: protocol and results in 50 women with aesthetically perfect breasts and clinical application. *Plast Reconstr Surg* 1997;100:468-79.
10. Maliniac JW. Arterial blood supply of the breast. *Arch Surg* 1943;47:329-43.
11. Palmer JH, Taylor GI. The vascular territories of the anterior chest wall. *Br J Plast Surg* 1986;39:287-99.
12. Neligan P. *Plastic surgery*. Vol. 5. London; New York: Elsevier Saunders; 2013.
13. Berthe JV, Massaut J, Greuse M, et al. The vertical mammoplasty: a reappraisal of the technique and its complications. *Plast Reconstr Surg* 2003;111:2192-9.
14. Hidalgo DA. Vertical mammoplasty. *Plast Reconstr Surg* 2005;115:1179-97.
15. Janis JE. *Essentials of plastic surgery*. St. Louis: Quality Medical Pub.; 2007.
16. Hall-Findlay EJ. A simplified vertical reduction mammoplasty: shortening the learning curve. *Plast Reconstr Surg* 1999;104:748-59.
17. Movassaghi K, Liao EC, Ting V, et al. Eliminating the vertical scar in breast reduction-Boston modification of the Robertson technique. *Aesthet Surg J* 2006;26:687-96.
18. Lalonde DH, French R, Lalonde J. The no vertical scar breast reduction: how to delete the vertical scar of the standard T-scar breast reduction and produce an excellent breast shape. *Perspect Plast Surg* 2001;15:103-18.