

References

1. Ma Q, Song H. Diagnosis and management of lymphoepithelial lesion of the parotid gland. *Rheumatol Int* 2011;31:959-62.
2. Seldin DC, Skinner M. Amyloidosis. In: Ruddy S, Sledge CB, Sargent JS, et al. *Kelly's textbook of rheumatology*. 9th ed. Philadelphia: Elsevier; 2012. p.1889-97.
3. Vitali C, Bombardieri S, Jonsson R, et al. Classification criteria for Sjogren's syndrome: a revised version of the European criteria proposed by the American-European Consensus Group. *Ann Rheum Dis* 2002;61:554-8.
4. Goto TK, Shimizu M, Kobayashi I, et al. Lymphoepithelial lesion of the parotid gland. *Dentomaxillofac Radiol* 2002;31:198-203.
5. Chhieng DC, Cangiarella JF, Cohen JM. Fine-needle aspiration cytology of lymphoproliferative lesions involving the major salivary glands. *Am J Clin Pathol* 2000;113:563-71.

Soft Tissue Chondroma Presenting as a Dermal Mass in the Toe

So Min Hwang, Jang Hyuk Kim, Min Wook Kim, Yong Hui Jung, Hyung Do Kim, Hong IL Kim, Min Kyu Hwang

Aesthetic, Plastic and Reconstructive Surgery Center, Good Moonhwa Hospital, Busan, Korea

Correspondence: So Min Hwang

Aesthetic, Plastic and Reconstructive Surgery Center, Good Moonhwa Hospital, 119 Beomil-ro, Dong-gu, Busan 601-803, Korea
Tel: +82-51-630-0199, Fax: +82-51-630-0145, E-mail: lexusair@gmail.com

No potential conflict of interest relevant to this article was reported.

Received: 2 Aug 2014 • Revised: 12 Sep 2014 • Accepted: 22 Sep 2014
pISSN: 2234-6163 • eISSN: 2234-6171
<http://dx.doi.org/10.5999/aps.2015.42.3.383> • *Arch Plast Surg* 2015;42:383-385

Copyright © 2015 The Korean Society of Plastic and Reconstructive Surgeons
This is an Open Access article distributed under the terms of the Creative Commons Attribution Non-Commercial License (<http://creativecommons.org/licenses/by-nc/3.0/>) which permits unrestricted non-commercial use, distribution, and reproduction in any medium, provided the original work is properly cited.

Soft tissue chondroma is a rare benign tumor, and it mainly affects hands and feet. Its prevalence reaches the highest level in individuals aged between 30 years and 60 years. In addition, it is known that there is no sex-related difference in its incidence. Repeated microtrauma has also been reported to be responsible for its occurrence.

A 72-year-old woman visited us with a chief complaint of a 3-year-history of a palpable, skin protuberance on the left third toe. The patient had a past history of taking surgical excision for skin protuberance at the department of dermatology of other hospital. Thereafter, however, the patient received resection of the skin protuberance again because of its recurrence. Nevertheless, the patient had a palpable mass at the surgical sites and complained about discomfort in the toe. Therefore, the patient visited us. On physical examination, the patient had a round, ill-defined skin protuberance with a diameter of approximately 1 cm. On palpation, it was a rather solid mass. In addition, the patient had a scratch on the skin surface (Fig. 1). On preoperative plain radiography, the patient had a calcified lesion with a diameter of < 1 mm in the deep lesion of the skin mass (Fig. 2).

After IV sedation, local anesthesia is applied and then the patient received a resection of the mass. We made an oval-shaped incision along the margin of the skin protuberance, for which we set the depth of resection at the right above the periosteum, thus attempting to sufficiently involve the subcutaneous adipose tissue. Thus, we performed a resection of the mass involving the calcified lesion identified on preoperative plain radiography. Postoperatively, the size of the resected mass was 1.0 × 0.8 cm. We performed histopathologic examinations (Fig. 3).

On histopathologic examinations, the patient was diagnosed with chondroma characterized by the

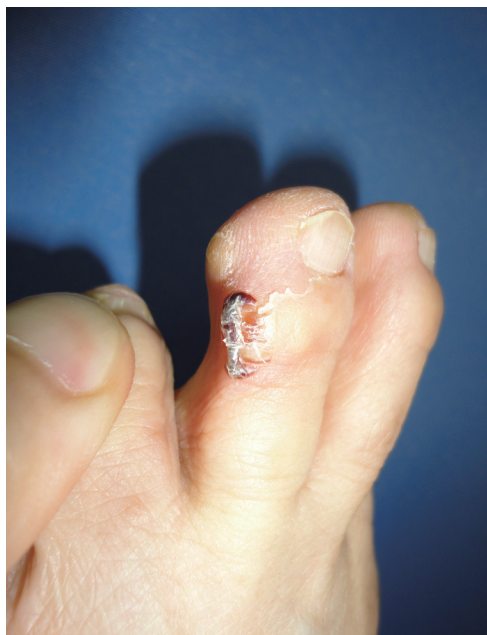

Fig. 1. Preoperative clinical view. 72-year-old female patients visited our hospital with chief complaint of 1 cm sized round and protuberance skin lesion which had a indetermined margin on dorsolateral aspect of third toe on left foot.

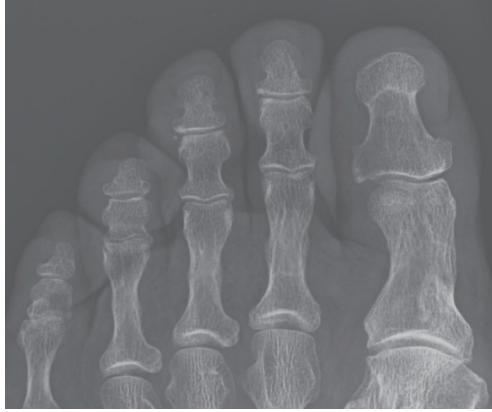


Fig. 2.
Preoperative radiologic finding.
One calcification lesion with less than 1 mm size was shown on plain anteroposterior radiograph.



Fig. 3.
Including calcified lesion, 1.0 x 0.8 cm sized mass excision was performed.

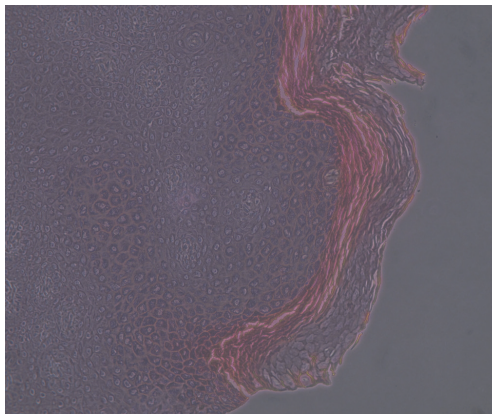


Fig. 4.
Histopathologic finding.
Pathologic confirmation disclosed that mass was chondroma which includes mature chondrocyte with mild focal cellular atypia in hyaline matrix (H&E, x 100).

presence of mature chondrocytes in the hyaline matrix accompanied by a mild focal cellular atypia (Fig. 4).

Postoperatively, the patient presented with a mild wound dehiscence, but achieved a recovery from it through the conservative treatments. At the surgical sites, there was no further recurrence until postoperative year 1 (Fig. 5).

Clinically, soft tissue chondroma is a rare entity. Irrespective of the sex, it mainly occurs in hands or feet of individuals aged between 30 years and 60 years. Most cases of the soft tissue sarcoma are

characterized by a slowly-growing mass. There are many asymptomatic cases in the early stage of onset. Over time, however, patients with soft tissue sarcoma complain of such symptoms as local tenderness, limited joint mobility and pain on action. Clinically, its incidence is also relatively lower. Therefore, it is often missed in the early stage of onset. Its final diagnosis should be made on histopathologic examinations [1]. In the current case, a 72-year-old woman did not recognize the necessity of taking the treatment until she complained of discomfort during gait. Therefore, the patient visited after long periods of time. At the department of dermatology of other medical institution, the patient solely received a resection of the skin lesion without taking other treatments. But the patient presented with recurrent episodes.

Still, little is known about the pathophysiology of soft tissue chondroma. It has been hypothesized, however, that the metaplasia of the adjacent joint or synovial membrane is responsible for its etiology [2,3]. In addition, Bannassy and Abdul-Khalik [4] also reported that the repeated, persistent microtrauma would also trigger its occurrence. Also in the current case, the patient formed a habit of scratching toes on a regular basis. Presumably, this might be associated with the occurrence of soft tissue sarcoma.

Still, little is known about the malignant transformation of soft tissue chondroma [5]. A differential diagnosis of it from chondrosarcoma should be made. This should also be accompanied any adjuvant radiological examinations and histopathologic analysis.

Also in the current case, there was a solitary calcified lesion 1 mm below the skin protuberance on preoperative plain radiography. Based on these findings, we determined that the patient had a recurrence of the skin lesion, although the patient received a resection of the skin protuberance, not because the lesion was a simple skin mass but because the mass was not removed from the deep layer of the soft tissue. We therefore perceived the necessity of performing a resection of the tumor involving the calcified lesion within the soft tissue, thus making a diagnosis of soft tissue chondroma following the surgical excision of the soft tissue tumor.

Although soft tissue chondroma is a benign tumor, it shows a relatively higher rate of local recurrence of 15% to 25% [5]. Presumably, this might be because we removed only the contents within the membrane

without involving the membrane covering the tumor or because we could not achieve a complete resection of the tumor during previous surgeries [1]. In the current case, the patient showed no recurrences during a 1-year period following the surgical excision of soft tissue chondroma at our medical institution. But this deserves continual, long-term follow-up studies.

Soft tissue chondroma is a rare entity. Its diagnosis cannot therefore be made solely on clinical presentations. Imaging studies and histopathologic examinations are essential for making a diagnosis of it. Although it is a benign tumor, it shows a higher rate of local recurrence. Therefore, surgeons should be aware of its local recurrence in making a surgical excision of it. Even postoperatively, surgeons should perform a meticulous monitoring of clinical course for long periods of time.

References

1. Khedhaier A, Maalla R, Ennouri K, et al. Soft tissues chondromas of the hand: a report of five cases. *Acta Orthop Belg* 2007;73:458-61.
2. Li C, Arger PH, Dalinka MK. Soft tissue osteochondroma: a report of three cases. *Skeletal Radiol* 1989;18:435-7.
3. Moon CW, Kim HM, Kim YS, et al. Soft tissue osteochondroma of the hand: a case report. *J Korean Soc Surg Hand* 2008;13:321-5.
4. Bahnassy M, Abdul-Khalik H. Soft tissue chondroma: a case report and literature review. *Oman Med J* 2009;24:296-9.
5. Min KD, Kim HT, Chun DI, et al. Arthroscopic resection of the chondroma in the supraspinatus of the shoulder. *J Korean Orthop Assoc* 2010;45:155-9.

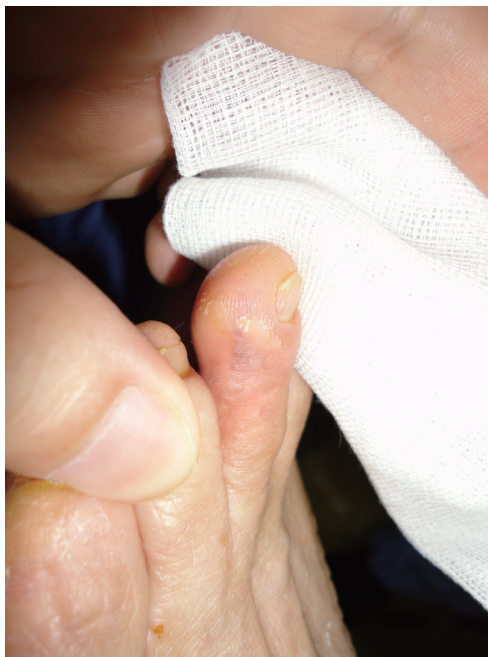

Fig. 5. Postoperative clinical view. 1-year follow up after operation shows no other complications nor recurrence signs.