

necessary, simply close the Redon, prick the skin in another site, and reopen the drainage. It will suck the liquid without losing the negative pressure.

This simple technique offers many advantages such as the availability of the required materials, lower risk of infection due to absence of material changing, a reduction in the risk of losing seromas (possible during the syringe changes), easier handling of the needle as compared to the whole syringe, a reduced number of devices with a decrease in costs, and higher accuracy of the drained fluid volume quantification.

This easy drainage method can be used daily for both seromas and liquid hematomas. It is also possible to connect a cannula needle [4] as an alternative to the simple needle. This can be attached to the skin appropriately in order to obtain permanent aspiration. This technique appears to be more accurate and cheaper than traditional drainage methods and can be an excellent alternative in voluminous seroma drains.

References

1. Glasberg SB, Light D. AlloDerm and Strattice in breast reconstruction: a comparison and techniques for optimizing outcomes. *Plast Reconstr Surg* 2012;129:1223-33.
2. Singh A, Thind MS, Mander KS, et al. Syringe suction drain. *Br J Plast Surg* 1992;45:484-5.
3. Tan O, Atik B, Parmaksizoglu D. An adjustable syringe suction drain. *Plast Reconstr Surg* 2005;116:2060-1.
4. Borman H. A simple apparatus for fluid evacuation: syringe suction drain. *Plast Reconstr Surg* 1999;104:1939-40.

Severe Facial Dermatitis Following Rhinoplasty due to an Unusual Etiopathogenesis: Rosacea

Süleyman Taş

Department of Plastic, Reconstructive and Aesthetic Surgery, R.T.E. University Training and Research Hospital, Rize, Turkey

Correspondence: Süleyman Taş

Department of Plastic, Reconstructive and Aesthetic Surgery, R.T.E. University Training and Research Hospital, Rize/center, 53100, Turkey
Tel: +90-464-2130491, Fax: +90-464-2170364
E-mail: drsuleymantas@live.com

I thank Dr. Inci Sema Taş for her valuable help in the preparation of this article.

No potential conflict of interest relevant to this article was reported.

Received: 1 Dec 2014 • Revised: 10 Jan 2015 • Accepted: 14 Jan 2015

pISSN: 2234-6163 • eISSN: 2234-6171

<http://dx.doi.org/10.5999/aps.2015.42.3.362> • Arch Plast Surg 2015;42:362-364

Copyright © 2015 The Korean Society of Plastic and Reconstructive Surgeons

This is an Open Access article distributed under the terms of the Creative Commons Attribution Non-Commercial License (<http://creativecommons.org/licenses/by-nc/3.0/>) which permits unrestricted non-commercial use, distribution, and reproduction in any medium, provided the original work is properly cited.

Cutaneous problems following rhinoplasty are minor, early, and temporary [1]. Usually, contact dermatitis with rash and pustules is observed, caused by the benzoin solution or gum used for increasing the adhesion of the tape. If the tape is applied too tightly, it can cause skin necrosis. Persistent redness and telangiectasia of the nasal skin are late cutaneous problems following rhinoplasty [1].

Rosacea is a chronic erythematous disease of the

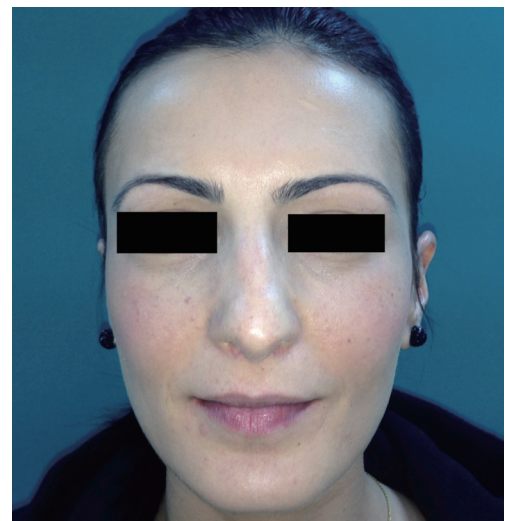

Fig. 1.
Preoperative appearance.

face, characterized by papules and pustules on the erythematous and telangiectatic regions. It may present with phymatous changes and ocular involvement, affect the central part of the face (especially the chin, nose, cheeks, and forehead), and last for months or years with remissions and exacerbations [2].

Rosacea may be seen at any age, but most commonly it begins between the ages of 30 years and 60 years. Although this chronic disease affects women more often, it is more severe in men and it does not show racial variation. Its occurrence is reported to range from 1.2% to 5.4% in people over the age of 50 years, although the actual incidence is unknown [3].

Here, the author reports severe facial dermatitis following rhinoplasty due to an unusual etiopathogenesis, reviews the relevant literature, and presents clinically relevant conclusions.

A 27-year-old woman underwent rhinoplasty surgery using the endonasal technique in February 2014. The patient appeared healthy with normal skin and no signs of acne (Fig. 1). The face was prepared with an iodine scrub. No autologous, heterologous, or foreign materials were used during surgery. PDS and Vicryl (Ethicon, Johnson & Johnson Company, Somerville, NJ, USA) were used as suture material. The nasal vestibules were packed with silicone splint. Nonocclusive Micropore (3M, St. Paul, MN, USA) Medical tape and a thermoplastic splint were applied over the nose. No material, such as benzoin solution or gum, was used for increasing the adhesion of the tape. The patient received prophylactic amoxicillin, 1,000 mg of clavulanic acid (2×1) and a non-steroidal anti-inflammatory drug (8 mg of lornoxicam, 2×1) for five days and was subsequently discharged.

The patient was admitted to my clinic five days postoperatively with extreme naso-facial itching and burning sensations. After the splint and bandages were removed, widespread erythema and exudative bullous lesions were apparent on the nose and cheeks (Fig. 2). The European standard battery patch test, with added hydrocortisone and 3M tape, was performed on the patient, along with a consultation with dermatology, and 1^+ sensitivity to the 3M tape was detected. The case was diagnosed as irritant contact dermatitis and treatment with a topical steroid (clobetasol propionate, 2×1) was started. The patient was then re-evaluated, since the lesions did not respond to steroid treatment for five days, and the existing lesions were exacerbated.

After a detailed history of the patient, it became

apparent that she experienced flushing and redness on the nose and cheeks once or twice a year, which would disappear spontaneously within one to two days.

A preliminary diagnosis of rosacea was considered for the patient, who re-consulted with dermatology, and tetracycline (100 mg, 2×1) was started for one week. Since the patient did not respond to this treatment, retinoic acid treatment (20 mg, 1×1) was started 22 days postoperatively. The patient rapidly responded to treatment with retinoic acid and the lesions disappeared in the second month postoperatively. No recurrence was detected in the six-month follow-up period, and the aesthetic outcome was satisfactory (Fig. 3).

Following rhinoplasty, minor skin reactions may occur depending on the tape and splint. This is referred to as a contact dermatitis reaction and often is reversible upon removal of the causative agent. However, spider veins and telangiectasia may sometimes develop, which can be exacerbated by the application of steroid injections for treating postoperative edema [4].

Acute contact dermatitis can be induced by irritants or allergens. Irritant contact dermatitis is the most common type, with effects ranging from slight erythema to more serious outcomes as blister formation or skin necrosis. The blisters or erythematous plaques may be limited to the contact area or can extend to neighboring areas, and patients complain of a burning sensation [1,5].

Allergic contact dermatitis is a delayed type IV cell-mediated immunological reaction which occurs against exogenous allergens. It usually occurs between 24 to 48 hours after the contact, but may also be

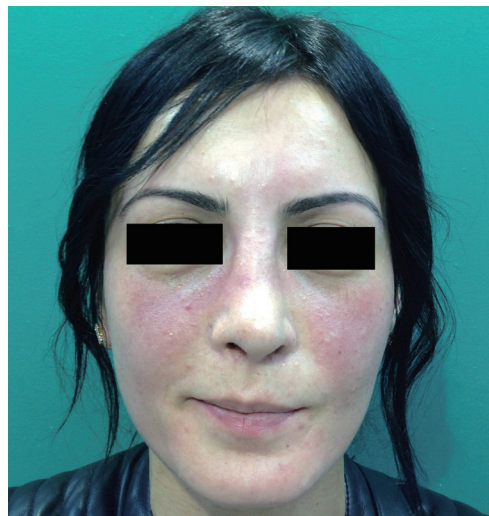


Fig. 2. Severe facial dermatitis is observed on the fifth day after the operation.

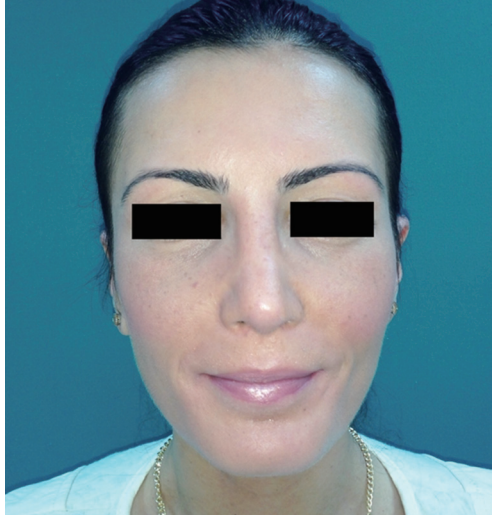

Fig. 3.
No recurrence was detected in the six-month follow-up period.

delayed until 14 days. Eruptions can develop into moderate to severe grade erythema and aqueous, crusty, itchy lesions. The diagnosis of allergic contact dermatitis can be confirmed by patch testing. The treatment requires the removal of the causative agent and is followed by cleaning the pustules. The affected area should be irrigated with desquamating soap and topical or systemic steroids and antihistamines should be applied [1,5].

The exact etiopathogenesis of rosacea is not known. According to the last accepted classification, there are four subtypes of rosacea and one variant. These are vascular (erythematotelangiectatic) rosacea, papulopustular (inflammatory) rosacea, rosacea phymatous (sebaceous hyperplasia), ocular rosacea, and variant rosacea [2,3].

The earliest sign of vascular rosacea is recurrent, temporary redness on the face, which gains a permanent character over time. Operations, some foods and drinks (hot tea, coffee, alcohol, chocolate, spices, tomatoes, peppers), emotional situations (anger and anxiety), and environmental factors (saunas, hot baths, warm and hot surroundings, fire, sun, wind, and cold) can aggravate the erythema. In the middle of the face, burning, stinging sensations and light squames may be observed. Telangiectasias, though not important for the diagnosis, can often be observed [2,3].

Though rosacea is a difficult disease to treat, it can be controlled. Primarily, the patients should be made aware of and avoid the predisposing factors that vary individually. The treatment of the condition is difficult and requires a multidisciplinary approach and combination therapy [2,3].

In this study, a condition is presented that can be

confused with contact dermatitis in an erythematotelangiectatic rosacea patient during the early postoperative period. This case resulted from the stress of the rhinoplasty operation that impacted pre-existing rosacea that was not preoperatively diagnosed. The topical steroid therapy, which was the initial treatment, aggravated the existing condition. Caution should be exercised in the diagnosis and treatment of these conditions, since they may be confused with one another. To the best of my knowledge, rosacea has not previously been reported as a cutaneous problem following rhinoplasty, despite its incidence rate of 1.2%–5.4%. Since contact dermatitis is often encountered in the early postoperative period, it is anticipated that delays in the treatment of undiagnosed rosacea can be prevented by investigating complaints involving flushing earlier in similar cases.

References

1. Rajabian MH, Sodaify M, Aghaei S. Severe facial dermatitis as a late complication of aesthetic rhinoplasty; a case report. *BMC Dermatol* 2004;4:1.
2. Crawford GH, Pelle MT, James WD. Rosacea: I. Etiology, pathogenesis, and subtype classification. *J Am Acad Dermatol* 2004;51:327-41; quiz 42-4.
3. Zuber TJ. Rosacea. *Prim Care* 2000;27:309-18.
4. Harsha BC. Complications of rhinoplasty. In: Shiffman MA, Di Giuseppe A, editors. *Advanced aesthetic rhinoplasty: art, science, and new clinical techniques*. Berlin: Springer; 2013. p.933-44.
5. Mabrie DC, Papel ID. An unexpected occurrence of acute contact dermatitis during rhinoplasty. *Arch Facial Plast Surg* 1999;1:320-1.