

of a direct incision above mass or an eyebrow incision leave a visible scar and also caused eyebrow depilation and hypopigmentation [2]. The endoscopic approach using a scalp incision was also found to cause hair loss around the operative scar and facial nerve injury [2]. Thus, because of these complications, an eyelid crease incision is preferred. Furthermore, we emphasize in cases of deep dermoid cyst, eyelid crease incision is an important approach because also enables the operator to identify anatomical structure and the condition of upper eyelid, such as, the levator aponeurosis as well as increasing cosmesis.

Initially, we considered removing the mass using the posterior approach through conjunctiva, because the mass was located below the Müller muscle and between conjunctivae. Goldberg and Lew [5] reported good results when the posterior approach was used to correct blepharoptosis. The biggest advantage of this approach is that the scar is not visible from the outside. However, in patients with a dermoid cyst, manipulation is difficult using a conjunctival posterior approach and this can result in rupture because of the narrow field of view.

We would like to remind the reader that a deep dermoid cyst under the levator aponeurosis and Müller muscle is rare, but that symptoms, such as, blepharoptosis can be observed in such cases. In addition, we emphasize the importance of correcting blepharoptosis and mass removal through an eyelid crease incision in such cases.

## References

1. Pryor SG, Lewis JE, Weaver AL, et al. Pediatric dermoid cysts of the head and neck. *Otolaryngol Head Neck Surg* 2005;132:938-42.
2. Kose R, Okur MI. Comparison of superior eyelid incision and directly over the lesion incision to brow dermoid cyst excision. *Eur J Plast Surg* 2009;32:83-5.
3. Yeola M, Joharapurkar SR, Bhole AM, et al. Orbital floor dermoid: an unusual presentation. *Indian J Ophthalmol* 2009;57:51-2.
4. Kronish JW, Dortzbach RK. Upper eyelid crease surgical approach to dermoid and epidermoid cysts in children. *Arch Ophthalmol* 1988;106:1625-7.
5. Goldberg RA, Lew H. Cosmetic outcome of posterior approach ptosis surgery (an American Ophthalmological Society thesis). *Trans Am Ophthalmol Soc* 2011;109:157-67.

## Reconstruction of Ear Deformity from Post-Piercing Perichondritis

Arthur W Perry<sup>1,2</sup>, Michael Sosin<sup>3</sup>

<sup>1</sup>Division of Plastic Surgery, Department of Surgery, Columbia University Medical Center, New York, NY; <sup>2</sup>Division of Plastic Surgery, Department of Surgery, Rutgers Robert Wood Johnson Medical School, New Brunswick, NJ; <sup>3</sup>Division of Plastic, Reconstructive, and Maxillofacial Surgery, Department of Surgery, R Adams Cowley Shock Trauma Center, University of Maryland Medical Center, Baltimore, MD, USA

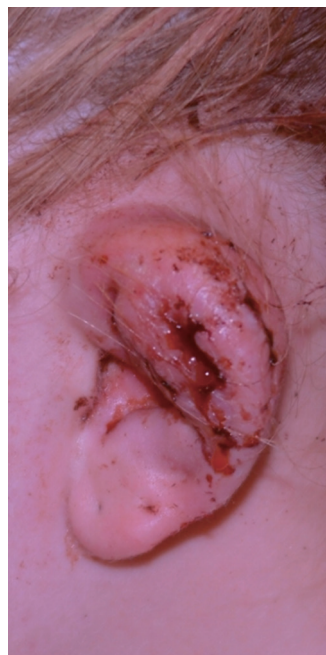**Correspondence:** Arthur W Perry  
Division of Plastic Surgery, Department of Surgery, Rutgers Robert Wood Johnson Medical School, New Brunswick, 3055 Route 27, Franklin Park, NJ 08823, USA  
Tel: +1-732-422-9600, Fax: +1-888-840-8232  
E-mail: dr.perry@perryplasticsurgery.com

No potential conflict of interest relevant to this article was reported.

Received: 4 Mar 2014 • Revised: 8 Apr 2014 • Accepted: 24 Apr 2014  
pISSN: 2234-6163 • eISSN: 2234-6171  
<http://dx.doi.org/10.5999/aps.2014.41.5.609> • Arch Plast Surg 2014;41:609-612

Copyright © 2014 The Korean Society of Plastic and Reconstructive Surgeons  
This is an Open Access article distributed under the terms of the Creative Commons Attribution Non-Commercial License (<http://creativecommons.org/licenses/by-nc/3.0/>) which permits unrestricted non-commercial use, distribution, and reproduction in any medium, provided the original work is properly cited.

Ear cartilage piercing has skyrocketed in popularity among teenagers and young adults [1]. In this lay procedure, the upper cartilage of the ear, the scapha, or the most lateral cartilage, the helical rim, are pierced with either a hollow-core or solid core instrument and jewelry is placed through the hole. While piercing



**Fig. 1.** Profile view of the infected ear at presentation.

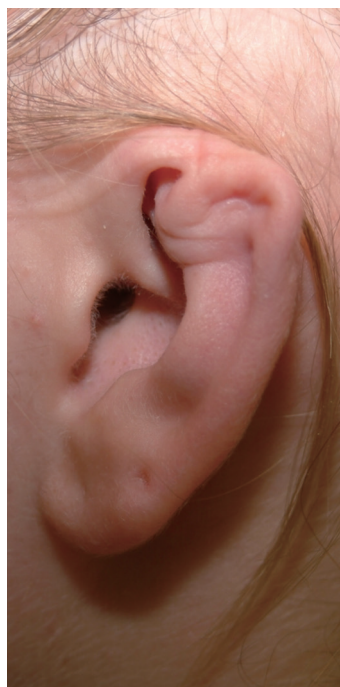through the earlobe skin is considered safe, cartilage's intrinsically poor blood supply predisposes transcartilaginous piercings to potentially devastating infections. Physicians must recognize early chondritis of the ear and initiate prompt treatment to avoid catastrophic deformities. This report describes a typical infection in a teenager and reviews the pathophysiology and treatment of ear chondritis.

A 17-year-old healthy girl underwent piercing to her left ear cartilage using a piercing gun at a shopping mall store. On the fifth day following piercing, she noted swelling of her ear. Two days later, her pediatrician placed her on oral dicloxacillin. Two weeks after the piercing, a family doctor incised a fluctuant area of the infected ear and drained pus. This subsequently grew out *Pseudomonas aeruginosa*, sensitive to all antibiotics. Three days later, she underwent an incision and drainage procedure in the operating room by an otolaryngologist who then switched her antibiotic to amoxicillin clavulonate. Three days later, she was referred to the first author, a plastic surgeon, who diagnosed cellulitis with grossly infected, draining anterior and posterior wounds (Fig. 1). By that time, she had lost a portion of the upper ear cartilage. In consultation with an infectious disease specialist, her antibiotics were changed to oral clindamycin and levaquin, with topical silver sulfadiazine and later mafenide acetate cream. Her infection began to improve within 24 hours and clinically resolved within one week. Oral antibiotics

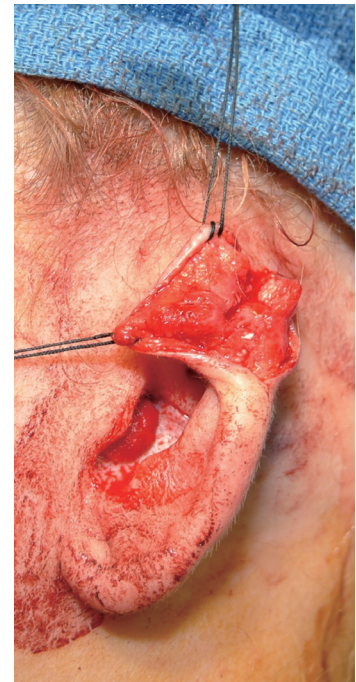
were continued for 6 weeks.

Following the infection, she was left with a significantly deformed ear (Fig. 2). One year following complete healing, she underwent a reconstruction of the ear, using cartilage grafts taken from the concha of the ipsilateral and contralateral ears, unfurling the existing cartilage, and stretching existing skin over the assembly (Figs. 3, 4). Six weeks following reconstruction demonstrated improved appearance, and the patient ultimately reported excellent satisfaction with the result (Fig. 5).

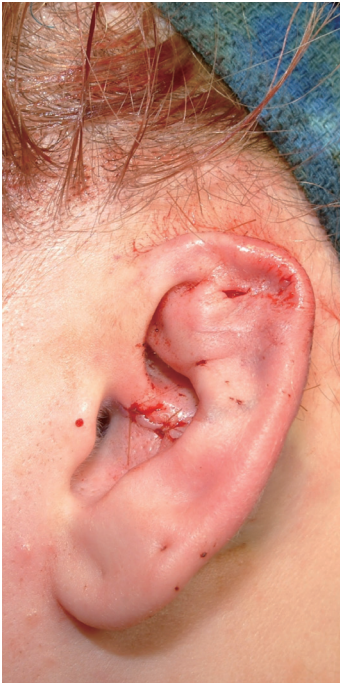Although the cosmetic deformities associated with cartilage piercing were described over 30 years ago, the recent surge in popularity calls attention to its dangers. Approximately a third of college students have some sort of body piercing, excluding ear lobes [2]. Ear cartilage piercing comprises over half of all body piercings and associated complications are underestimated because these infections are not reportable to public health entities. However, it is known that the incidence of perichondritis has increased and has been shown to have a greater risk of infection than earlobe piercing [3]. Unfortunately, cartilage ear piercing is often performed in a non-sterile environment by unqualified individuals that are unaware of potentially devastating consequences.



**Fig. 2.**  
Profile view of deformed ear one year post infection.



**Fig. 3.**  
Intraoperative reconstruction depicting hypertrophic scarring and adhesions.

**Fig. 4.**

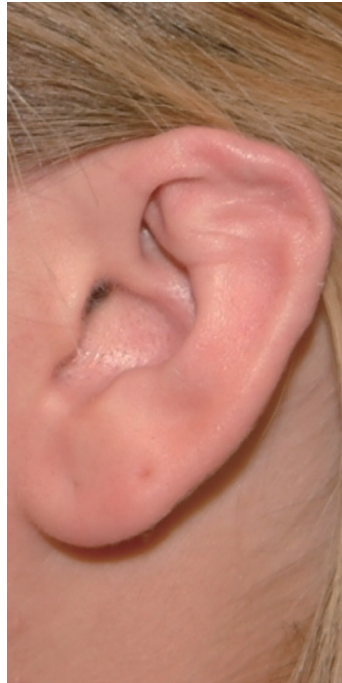Cartilaginous deformity resected, completion of autologous cartilage reconstruction, and reapproximation of skin flaps.

Cartilage piercing meets the American College of Surgeon's definition of surgery, and in this situation, this surgery is practiced by the lay. Infections in this location are particularly likely to result in significant deformity requiring complex plastic surgical reconstruction.

Lay piercing stores commonly swab the ear with isopropyl alcohol or benzalkonium chloride, which is active against gram-negative and gram-positive bacteria, but ineffective against *Pseudomonas* strains as well as spore forming bacteria. Iodine-povidone is not commonly used in retail establishments because of the perception of iodine allergies and the unappealing discoloration of skin and clothing.

Cartilage, if pierced at all, should be penetrated with sharp, hollow needles, which will core out the cartilage. The more common solid needles or spring-loaded piercing "guns" can cause the cartilage can crack in a stellate pattern, creating bleeding between the cartilage and the perichondrium [4]. Regardless of technique, any resultant subperichondrial bleeding further decreases the blood supply of the cartilage and increases the chance of infection.

Ear cartilage has no intrinsic blood supply and derives its nutrition from adherent perichondrium.

**Fig. 5.**

Postoperative result 6-weeks following ear reconstruction.

When bacteria are introduced into the cartilage, the host defense is meager resulting in a rapid and devastating infection. Pus hydrostatically lifts the perichondrium and skin, further isolating the cartilage's blood supply. Once an infection begins, antibiotics have limited effectiveness in the avascular cartilage, necessitating incision and drainage procedures. Intraoperative cultures are important to guide antibiotic usage to prevent further dissemination of bacteria. Initial incisions are chosen at the points of drainage. Where possible, these should be carefully planned to allow for future reconstruction.

*Pseudomonas aeruginosa*, *Staphylococcus aureus* and *Streptococcus pyogenes* are the pathogens isolated in most cases of auricular chondritis [3]. Topical silver sulfadiazene or mafenide acetate should be applied to the anterior and posterior ear surfaces and held in place with petrolatum impregnated fine mesh gauze. Oral or intravenous and topical antibiotics should be initiated immediately.

In the absence of fluctuance, oral or intravenous antibiotics should be used, with daily observation and drainage and debridement if necessary. Outpatient antibiotic treatment may be attempted, but if there is no response to oral antibiotics within 24 hours, then hospital admission for intravenous antibiotics is necessary. Antibiotics should be continued for six weeks. If left untreated or improperly managed, further erosion and deformity of the ear can possibly lead to hearing impairment.

The degree of deformity depends on the promptness and efficacy of treatment. Deformities will vary from small contour irregularities in the helical rim to complete absence of the ear. Reconstruction should not be attempted for a minimum of 6 months after complete resolution of the infection [4,5]. Reconstruction is individualized for the deformity and may consist of simple scar revision, cartilage sculpting, or complete reconstruction of the ear with cartilage grafts and flaps. Most commonly, a local skin envelope can be salvaged and can be unfurled and wrapped over shaped cartilage grafts taken from the opposite ear. Reconstructive complexity may escalate if initial reconstructions are inadequate.

The consequences of ear cartilage piercing include infection and potential loss of the ear. As such, patients should be counseled about these risks when considering the procedure.

## References

1. Chowdhury WA, Hossain MM, Chowdhury MR, et al. High ear piercing: a dangerous craze. *Mymensingh Med J* 2004;13:201-2.
2. Armstrong ML, Roberts AE, Owen DC, et al. Contemporary college students and body piercing. *J Adolesc Health* 2004;35:58-61.
3. Simplot TC, Hoffman HT. Comparison between cartilage and soft tissue ear piercing complications. *Am J Otolaryngol* 1998;19:305-10.
4. van Wijk MP, Kummer JA, Kon M. Ear piercing techniques and their effect on cartilage, a histologic study. *J Plast Reconstr Aesthet Surg* 2008;61 Suppl 1:S104-9.
5. Cicchetti S, Skillman J, Gault DT. Piercing the upper ear: a simple infection, a difficult reconstruction. *Br J Plast Surg* 2002;55:194-7.

## Axillary Fistula and Scar Contracture due to Uncontrolled Chronic Infection after Trans-Axillary Augmentation Mammoplasty

Kyung Han Yu, Soo A Lim, Jin Kyung Song, Yong Il Yoon

Department of Plastic and Reconstructive Surgery, KEPCO Medical Center, Seoul, Korea

**Correspondence:** Soo A Lim  
Department of Plastic and Reconstructive Surgery, KEPCO Medical Center, 308 Uicheon-ro, Dobong-gu, Seoul 132-703, Korea  
Tel: +82-2-901-3109, Fax: +82-2-901-3104  
E-mail: zzcrunch@naver.com

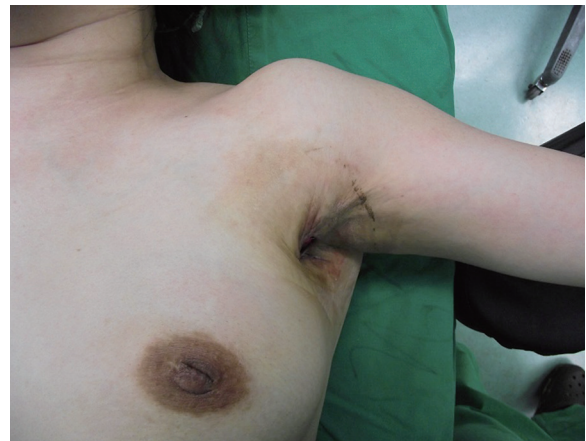This article was presented as a poster at the 3rd Research and Reconstructive Forum on May 9-10, 2013, in Daegu, Korea.

No potential conflict of interest relevant to this article was reported.

Received: 23 Apr 2014 • Revised: 16 May 2014 • Accepted: 3 Jun 2014  
pISSN: 2234-6163 • eISSN: 2234-6171  
<http://dx.doi.org/10.5999/aps.2014.41.5.612> • Arch Plast Surg 2014;41:612-615

Copyright © 2014 The Korean Society of Plastic and Reconstructive Surgeons  
This is an Open Access article distributed under the terms of the Creative Commons Attribution Non-Commercial License (<http://creativecommons.org/licenses/by-nc/3.0/>) which permits unrestricted non-commercial use, distribution, and reproduction in any medium, provided the original work is properly cited.

Infection after augmentation mammoplasty should not be underestimated. Because if not appropriately treated, it may lead to serious issues such as scarring, wound dehiscence, reinfection and after all, implant loss [1,2]. Generally, even if in severe infection, the course tends to improve with implant removal, antibiotic treatment and other additional surgical procedures like debridement, drainage [2]. But with above treatments it may lead serious secondary complications [2] and we experienced about axillary fistula and scar contracture with limitation of motion



**Fig. 1.** Limitation of motion of left shoulder due to scar contractures is shown. Checked active range of motion is about 70 degrees.