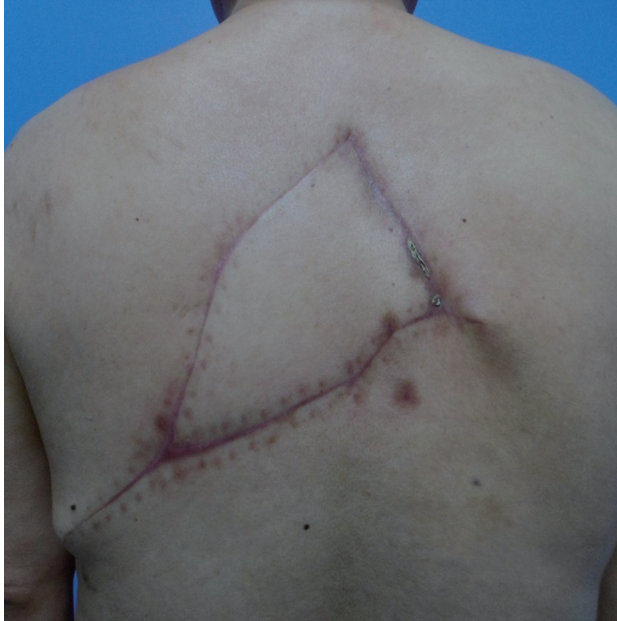

**Fig. 5.**

Postoperative two months, postoperative course was uneventful.

References

1. Mathes DW, Thornton JF, Rohrich RJ. Management of posterior trunk defects. *Plast Reconstr Surg* 2006;118:73e-83e.
2. Hallock GG. Reconstruction of posterior trunk defects. *Semin Plast Surg* 2011;25:78-85.
3. Hamdi M, Van Landuyt K, de Frene B, et al. The versatility of the inter-costal artery perforator (ICAP) flaps. *J Plast Reconstr Aesthet Surg* 2006;59:644-52.
4. Oh TS, Hallock G, Hong JP. Freestyle propeller flaps to reconstruct defects of the posterior trunk: a simple approach to a difficult problem. *Ann Plast Surg* 2012;68:79-82.
5. Prasad V, Almutairi K, Kimble FW, et al. Dorsolateral musculocutaneous perforators of posterior intercostal artery: an anatomical study. *J Plast Reconstr Aesthet Surg* 2012;65:1518-24.

Liposarcoma in the Axilla Developed from a Longstanding Lipoma

Yoon-Jae Lee, Yeon Jin Jeong, Jung Ho Lee, Young-Joon Jun, Young-Jin Kim

Department of Plastic Surgery, Bucheon St. Mary's Hospital, The Catholic University of Korea College of Medicine, Bucheon, Korea

Correspondence: Jung Ho Lee
Department of Plastic Surgery, Bucheon St. Mary's Hospital, The Catholic University of Korea College of Medicine, 327 Sosa-ro, Wonmi-gu, Bucheon 420-717, Korea
Tel: +82-32-340-7059, Fax: +82-2-594-7230
E-mail: tfm0822@catholic.ac.kr

No potential conflict of interest relevant to this article was reported.

Received: 17 Feb 2014 • Revised: 18 Apr 2014 • Accepted: 18 Apr 2014
pISSN: 2234-6163 • eISSN: 2234-6171
<http://dx.doi.org/10.5999/aps.2014.41.5.600> • Arch Plast Surg 2014;41:600-602

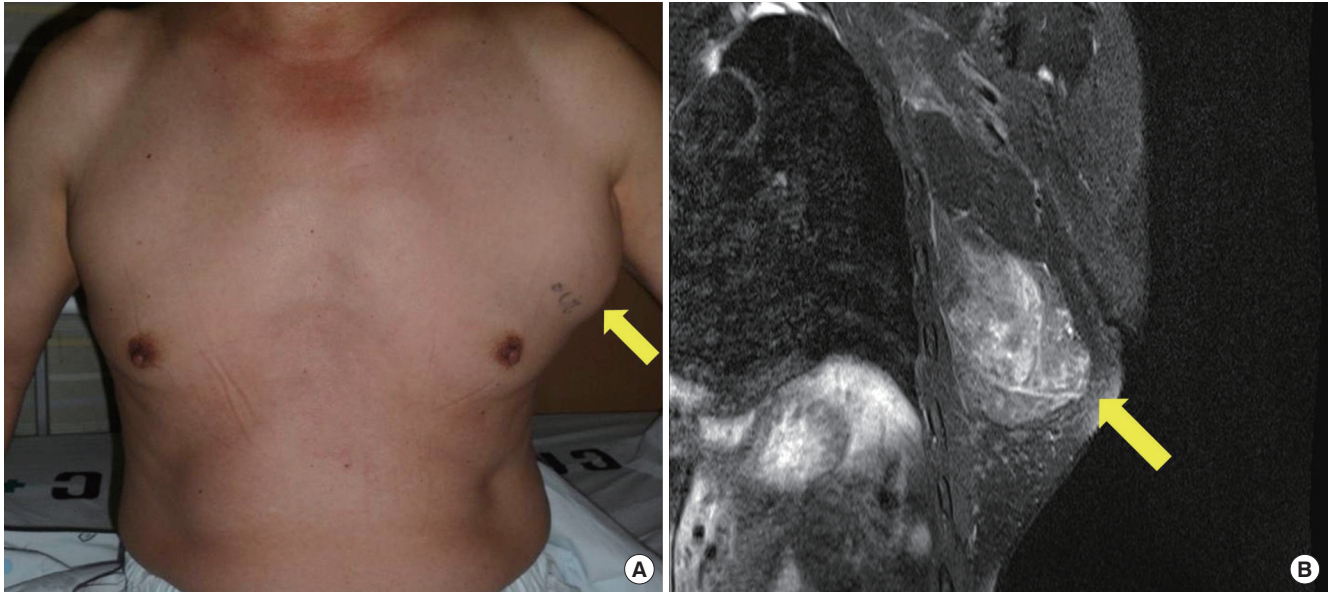
Copyright © 2014 The Korean Society of Plastic and Reconstructive Surgeons
This is an Open Access article distributed under the terms of the Creative Commons Attribution Non-Commercial License (<http://creativecommons.org/licenses/by-nc/3.0/>) which permits unrestricted non-commercial use, distribution, and reproduction in any medium, provided the original work is properly cited.

Liposarcoma is one of the most common soft-tissue sarcomas in adults, accounting for approximately 20% of all soft-tissue malignancies [1]. It usually occurs in the retroperitoneum and lower extremities and originates from primitive mesenchymal cells deep in the soft tissue, such as intermuscular fascia.

The concept of pathogenesis of liposarcoma arising from benign lipoma is generally not accepted, and only few cases suggesting the transformation of benign lipoma into liposarcoma have been reported [2].

We report a rare case of liposarcoma in the axilla that was developed from a longstanding lipoma and review recent concepts concerning the pathogenesis of liposarcoma.

A 70-year-old male presented with a recurred huge mass in the left axilla (Fig. 1A). The patient had no mass-related pain but complained of discomfort because of the mass. On physical exam, the mass was non-tender and movable. A preoperative magnetic resonance imaging (MRI) showed a $12 \times 10 \times 6$ -cm heterogeneously enhancing mass with a fat signal, suggesting lipoma or well-differentiated liposarcoma (Fig. 1B). He had a history of partial resection of the mass at the same site 11 years before his visit. At that time, because the primary aim of surgery was to improve the external appearance and the mass was adjacent to neurovascular structure, only partial resection was performed and the pathologic diagnosis was lipoma (Fig. 2).

**Fig. 1.**

(A) Preoperative photograph shows a huge mass in the left axilla (yellow arrow). (B) The preoperative magnetic resonance imaging shows a 12 × 10 × 6 cm heterogeneously enhanced mass with a fat signal (yellow arrow).

Intraoperatively, the frozen sectional biopsy could not confirm malignancy or benignity, and so we widely excised the mass, including the adjacent normal fat component, on the assumption that it was malignant. The size of the mass measured about 20 × 16 × 9 cm and had multiple large lobules. There was thick fibrous septum between the lobules but no sign of definite capsule which can be commonly seen in the lipoma. Postoperatively, the histological examination revealed a well-differentiated liposarcoma with tumor-free margins (Fig. 3). Postoperative positron-emission tomography-computed tomography (PET-CT) revealed no residual or metastatic tumor. The patient was referred to the oncology department and underwent adjuvant radiotherapy. He remained free of local recurrence or distant metastasis for 11 months postoperatively.

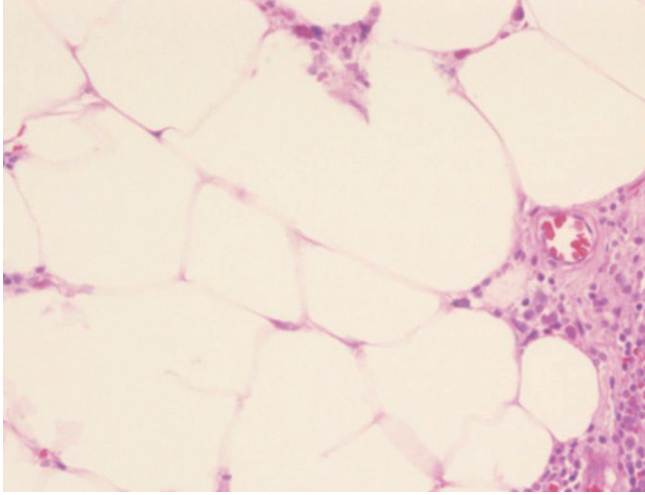
Unlike epithelial neoplasms, malignant transformation of benign soft-tissue tumors is extremely rare. Particularly, liposarcoma has been regarded to occur *de novo*, rather than secondarily from a benign lipoma [2].

However, recent studies regarding molecular and genetic abnormalities in lipomatous tumors have suggested a biologic potency of transformation of benign lipoma into well-differentiated liposarcoma. In detail, it is possible that some cells in tumors that appear morphologically benign may have already obtained the molecular or genetic changes for

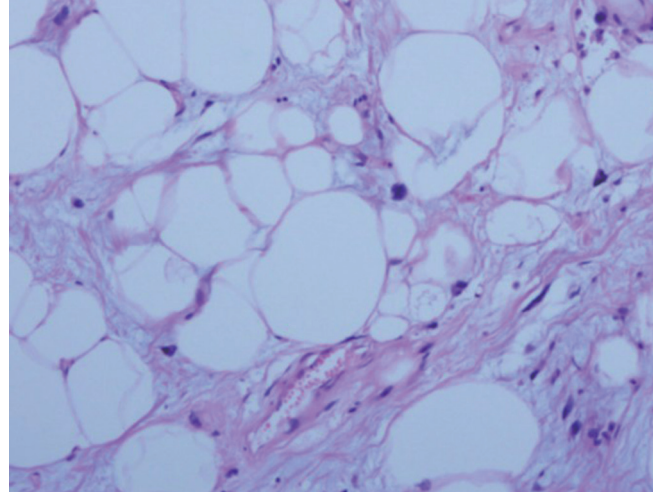
invasion and metastasis that are not reflected in their morphology [3]. Dei Tos et al. [4] found genetic similarity between lipoma and well-differentiated liposarcoma. Well-differentiated liposarcoma showed 12q13-15 amplification, and lipoma showed 12q13-15 rearrangement. Additionally, many cases supporting this theory have been reported. Kuhnen et al. [5] discovered a 14-cm tumor of the thigh, of which 80% was benign lipoma and 20% was atypical lipomatous tumor. In immunohistochemistry and *in situ* hybridization, the atypical lipomatous component of the tumor showed amplification of MDM2 and CDK4 whereas lipoma component showed no amplification. Actually, it cannot be completely ruled out that the axillary tumor have been primarily a malignant tumor and the diagnosis of lipoma in primary surgery might be due to inappropriate specimen section (i.e., biopsy of a benign portion of the tumor).

Based on the above studies, although rare, sarcomatous change of lipoma is supported by sufficient evidence to be accepted. Therefore, when creating a treatment plan and predicting the prognosis of a longstanding or recurrent lipomatous tumor, surgeons must consider the possibility of malignant transformation. Surgical options that cannot guarantee an en bloc excision of the tumor, such as liposuction, should not be performed without a solid histologic diagnosis beforehand.

Intraoperative frozen section biopsy, commonly

**Fig. 2.**

H&E staining ($\times 200$) of the mass excised 11 years earlier shows the lobules of mature adipocytes with little variation in size and shape of the cells which is consistent with a benign lipoma.

**Fig. 3.**

H&E staining ($\times 200$) of the mass shows relatively mature adipocytes proliferation with significant variation in cell size, and fibrous bands containing atypical stromal cells and lipoblasts which is consistent with a liposarcoma.

used in malignant solid tumor surgery, is not often helpful for differentiating benignity from malignancy because the adipose component of the mass is usually lost during tissue preparation, and the tissue structure can be distorted. Thus, for patients with longstanding lipoma, preoperative MRI is helpful in decision making for the surgical procedure as it is useful for distinguishing well-differentiated liposarcoma between benign lipoma. The presence of thick septae (> 2 mm) or a nodular component of nonadipose tissue within the lesion in MRI is highly suggestive of malignancy [2]. In addition, preoperative incisional biopsy before definite surgery is also recommended because intraoperative frozen biopsy may not be helpful.

In clinical practice, well-differentiated liposarcoma is considered to be a nonmetastasizing lesion but it shows a significant propensity for local recurrence when there are difficulties in obtaining an adequate surgical margin [2]. The combination of surgery and radiation therapy has been shown to decrease the risk of local recurrence [2]. The prognosis of liposarcoma will vary according to subtype: well-differentiated, myxoid, round, pleomorphic, and dedifferentiated. Patients with well-differentiated liposarcoma have a relatively good prognosis compared with patients with the other type. Another prognostic factor for well-differentiated liposarcoma is anatomic location, as the tumor in surgically resectable area does not recur after wide excision with a clear margin. However the tumor arising in deep anatomic sites such as retroperitoneum tend to recur repeatedly to the extent that may

dedifferentiate and metastasise [2].

References

1. Mack TM. Sarcomas and other malignancies of soft tissue, retroperitoneum, peritoneum, pleura, heart, mediastinum, and spleen. *Cancer* 1995;75:211-44.
2. Peterson JJ, Kransdorf MJ, Bancroft LW, et al. Malignant fatty tumors: classification, clinical course, imaging appearance and treatment. *Skeletal Radiol* 2003;32:493-503.
3. Mentzel T. Biological continuum of benign, atypical, and malignant mesenchymal neoplasms—does it exist? *J Pathol* 2000;190:523-5.
4. Dei Tos AP, Doglioni C, Piccinin S, et al. Coordinated expression and amplification of the MDM2, CDK4, and HMGI-C genes in atypical lipomatous tumours. *J Pathol* 2000;190:531-6.
5. Kuhnen C, Mentzel T, Lehnhardt M, et al. Lipoma and atypical lipomatous tumor within the same neoplasia: Evidence for a continuous transition. *Pathologie* 2010; 31:129-34.