

blood flow of the cervical vessels, especially in bilateral cases [5]. In the current case, we decided to follow-up with the patient on a monthly basis, not only because there were no symptoms or complications, but also because the radiologic study revealed only the dilatation of the internal jugular vein without any causative structural lesions. In addition, the patient refused to undergo cosmetic surgery.

In evaluating patients with trauma who experience neck swelling, clinicians should consider making a differential diagnosis of various conditions from simple contusion to life-threatening ones including pseudoaneurysm or a delayed rupture of the cervical vessels. These life-threatening vessel injuries can be confirmed by angiography, which should be accompanied by emergency intervention or surgery. Although IJP is a rare condition, when making a differential diagnosis of neck swelling in patients with trauma, clinicians should refrain from unnecessary evaluations by performing a physical examination and routine radiography to conserve time and money. We experienced a rare case of IJP in a patient with trauma. Clinicians should be aware of IJP as a candidate condition of the differential diagnosis of neck swelling in trauma patients.

## References

1. Paleri V, Gopalakrishnan S. Jugular phlebectasia: theory of pathogenesis and review of literature. *Int J Pediatr Otorhinolaryngol* 2001;57:155-9.
2. Haney JC, Shortell CK, McCann RL, et al. Congenital jugular vein phlebectasia: a case report and review of the literature. *Ann Vasc Surg* 2008;22:681-3.
3. Jianhong L, Xuewu J, Tingze H. Surgical treatment of jugular vein phlebectasia in children. *Am J Surg* 2006;192:286-90.
4. Chang YT, Lee JY, Wang JY, et al. Transaxillary subfascial endoscopic approach for internal jugular phlebectasia in a child. *Head Neck* 2010;32:806-11.
5. Hung T, Campbell AI. Surgical repair of left internal jugular phlebectasia. *J Vasc Surg* 2008;47:1337-8.

## Scalp Reconstruction after Resection of a Large Recurred Proliferating Trichilemmal Tumor Using an Anterolateral Thigh Free Flap

Matthew Seung Suk Choi<sup>1</sup>, Eui Jong Kim<sup>1</sup>, Jang Hyun Lee<sup>1</sup>, Ju Yeon Pyo<sup>2</sup>, Yong Wook Park<sup>2</sup>, Kyung Mook Lee<sup>3</sup>

Departments of <sup>1</sup>Plastic and Reconstructive Surgery and <sup>2</sup>Pathology, Hanyang University Guri Hospital, Hanyang University College of Medicine, Guri; <sup>3</sup>Department of Plastic and Reconstructive Surgery, Inje University Haeundae Paik Hospital, Inje University College of Medicine, Busan, Korea

Correspondence: Jang Hyun Lee

Department of Plastic and Reconstructive Surgery, Hanyang University Guri Hospital, Hanyang University College of Medicine, 153 Gyeongchun-ro, Guri 471-701, Korea  
Tel: +82-31-560-2330, Fax: +82-31-560-2338, E-mail: pslee@hanyang.ac.kr

This article was presented as a poster at the 70th Congress of the Korean Society of Plastic and Reconstructive Surgeons on November 9-11, 2012 in Seoul, Korea.

No potential conflict of interest relevant to this article was reported.

Received: 18 Apr 2013 • Revised: 1 May 2013 • Accepted: 2 May 2013

pISSN: 2234-6163 • eISSN: 2234-6171

<http://dx.doi.org/10.5999/aps.2013.40.4.458> • Arch Plast Surg 2013;40:458-460

Copyright © 2013 The Korean Society of Plastic and Reconstructive Surgeons

This is an Open Access article distributed under the terms of the Creative Commons Attribution Non-Commercial License (<http://creativecommons.org/licenses/by-nc/3.0/>) which permits unrestricted non-commercial use, distribution, and reproduction in any medium, provided the original work is properly cited.

Proliferating trichilemmal tumor (PTT) is an uncommon lesion that is characterized by an exuberant growth of cells derived from the external root sheath of the hair follicle. Histologically, it presents as trichilemmal keratinization. It is known to be derived from trichilemmal cysts and to have a potential for malig-

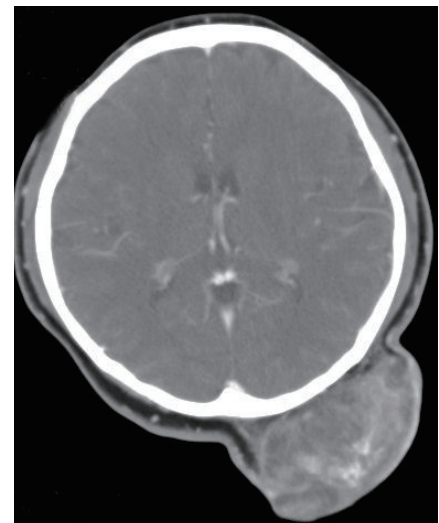
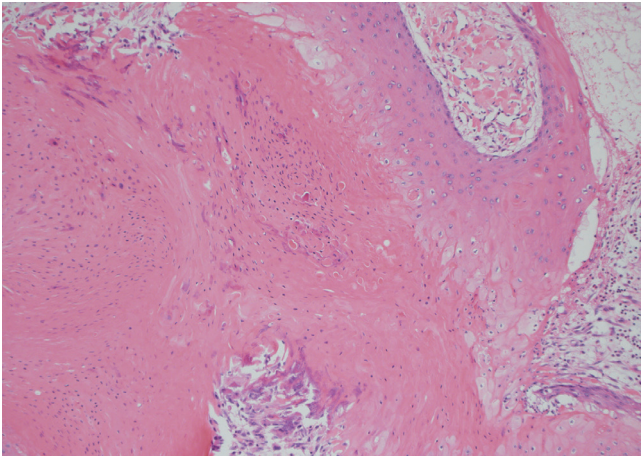


Fig. 1.

Findings at a local clinic. Computed tomography findings show mass involvement with the pericranium.

**Fig. 2.**

Histopathologic findings. The tumor shows typical features of trichilemmal keratinization of squamous epithelium without cytologic atypia (H&E,  $\times 100$ ).

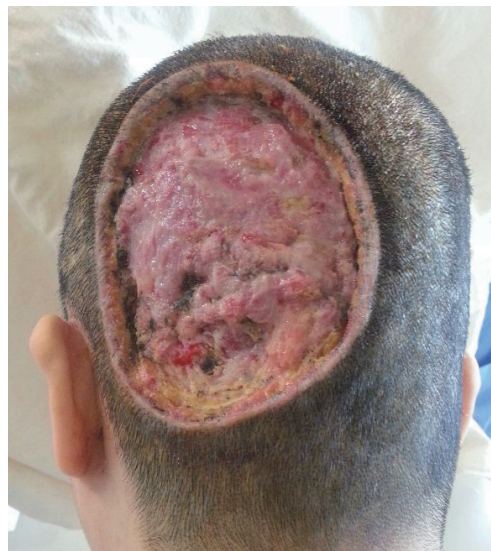nant conversion. In the latter case, it is called malignant proliferating trichilemmal tumor [1]. As it has some low-grade malignant potential as well as unpredictable biological behavior, wide excision with a 1 cm margin of normal tissue is required in order to prevent recurrence.

A 43-year-old woman who had been seen with a large ulcerated mass in the occipital area at a primary care hospital visited our institution. The dimension of the mass had been 13 cm  $\times$  10 cm  $\times$  5 cm on the computed tomography scan (Fig. 1). The tumor had been first noticed by the patient as a small asymptomatic lesion on the occiput 15 years earlier. No intervention had been undertaken, and the lesion had not increased in size for 11 years. However, 4 years prior to her presentation to the local clinic, the mass had begun to increase in size although there were no other significant symptoms such as pain or bleeding. According to the primary surgeon's clinical examination, the mass had been firm and adherent at its base, with a small necrotic central ulcer with contact bleeding. Given that it was biopsied as PTT, he had performed a mass excision at the suprapariosteal plane with a 1 cm free margin and coverage with a skin graft (Fig. 2). After an initial take of the skin graft, the wound had deteriorated rapidly with discharge, redness, and inflammatory changes, and the skin graft failed to take. The patient was transferred to our hospital with a 13 cm  $\times$  10 cm ulcerative lesion (Fig. 3).

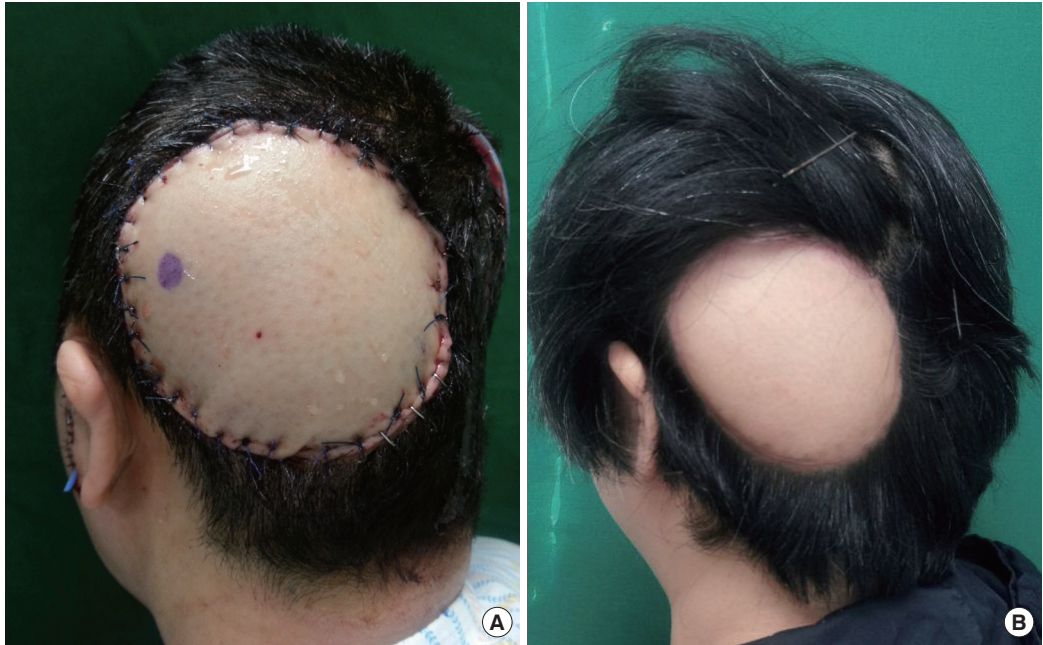After ruling out lymph node or distant metastasis, a treatment plan was set up. The recurred tumor was resected radically with a 1 cm margin at the subperiosteal level as the tumor was judged to be abutting on the periosteum intraoperatively, and the outer cortex of the skull was burred to minimize the risk of recurrence. The defect was covered by an anterolateral

thigh (ALT) free flap. A 15 cm  $\times$  12 cm fasciocutaneous flap was harvested from the patient's left thigh to resurface the resultant large post-excisional defect. The superficial temporal artery and its venae comitantes were used as the recipient vessels. Microanastomoses of the vessels were performed in an end-to-end pattern. The donor site was closed primarily. The postoperative course was uneventful, and the free flap healed completely. The thickness of the flap was well matched with that of the scalp, and the contour was aesthetically satisfactory. No recurrence has been observed for 8 months after surgery (Fig. 4).

A PTT appears on the skin with dense concentrations of hair follicles, mainly in the scalp. It usually presents initially as a subcutaneous cystic nodule, which may persist for several years, slowly enlarging to a larger nodular mass [1]. It is an aggressive tumor that invades across tissue planes and, in the scalp, it

**Fig. 3.**

A large, incompletely resected proliferating trichilemmal tumor. The patient was referred to our hospital with a large ulcerated lesion 2 weeks after the surgery.



**Fig. 4.** Postoperative findings. (A) Photograph at 3 days after the operation. (B) Follow-up photograph at 8 months after the reconstruction. The photograph shows an aesthetically pleasing contour and no recurrence.

may even extend intracranially, causing a high degree of morbidity and possible mortality. Local recurrence after excision is frequently seen [2]. Therefore, the authors decided to perform a wide full-thickness excision of the tumor, which subsequently required free flap coverage. Options for scalp reconstruction include the use of local flaps, tissue expansion, or free flaps [3]. It is generally accepted that the best replacement for scalp tissue is adjacent tissue because there is no other donor site on the body that can match the hair-bearing qualities of the scalp. Therefore, local flaps are the optimal choice for the best cosmetic effect. However, in the event of extensive scalp defects, where local tissue rearrangements are inadequate for reconstruction, the use of local flaps is limited [3].

Tissue expansion represents an excellent option because it essentially creates more locally available scalp tissue. However, it is a long and laborious process and in order to create sufficient local tissue for the coverage of large defects, such as in our report, the period of expansion required is several months, which is too long [4]. This procedure requires multiple operations with lengthy intervals, which results in prolonged wound care and increased patient discomfort. In our case, the patient had already undergone a prior operation, and she declined further staged procedures in favor of a single-stage reconstruction.

The ALT flap is an excellent choice for reconstruct-

ing large full-thickness scalp defects in a single stage. Aesthetically, the patient was very satisfied with the result, in terms of flap thickness, contour, and pliability. The main cosmetic drawback was the absence of hair. In order to counter this, hair restoration, whether using tissue expanders or via hair transplantation, needs to be planned in the future.

PTTs are rare soft tissue tumors presenting on hair bearing areas. The operating surgeon should be prepared to treat them aggressively when indicated. However, this often results in large full-thickness defects. We propose the use of the ALT free flap as a good option for the resurfacing of these defects.

## References

1. Satyaprakash AK, Sheehan DJ, Sangueza OP. Proliferating trichilemmal tumors: a review of the literature. *Dermatol Surg* 2007;33:1102-8.
2. Markal N, Kurtay A, Velidedeoglu H, et al. Malignant transformation of a giant proliferating trichilemmal tumor of the scalp: patient report and literature review. *Ann Plast Surg* 1998;41:314-6.
3. Leedy JE, Janis JE, Rohrich RJ. Reconstruction of acquired scalp defects: an algorithmic approach. *Plast Reconstr Surg* 2005;116:54e-72e.
4. Bo B, Qun Y, Zheming P, et al. Reconstruction scalp defects after malignant tumor resection with anterolateral thigh flaps. *J Craniofac Surg* 2011;22:2208-11.