

Efficacy of Quilting Sutures and Fibrin Sealant Together for Prevention of Seroma in Extended Latissimus Dorsi Flap Donor Sites

In Soo Shin, Dong Won Lee, Dae Hyun Lew

Institute for Human Tissue Restoration, Department of Plastic and Reconstructive Surgery, Yonsei University College of Medicine, Seoul, Korea

Original Article

Background The extended latissimus dorsi flap is important for breast reconstruction. Unfortunately, donor site seroma is the most common complication of extended latissimus dorsi flap for breast reconstruction. Although using fibrin sealant in the donor site reduces the rate of seroma formation, donor site seroma remains a troublesome complication. The purpose of this study was to analyze the effectiveness of the combination of quilting sutures and fibrin sealant in the latissimus dorsi donor site for the prevention of seroma.

Methods Forty-six patients who underwent breast reconstruction with extended latissimus dorsi flap were enrolled in the study. The patients received either fibrin sealant (group 1, n=25) or a combination of fibrin sealant and quilting sutures (group 2, n=21) in the extended latissimus dorsi donor site. Outcome measures were obtained from the incidence, volume of postoperative seroma, total drainage amount, indwelling period of drainage, and duration of hospital stay.

Results The incidence of seroma was 76% in group 1 and 42.9% in group 2 (P=0.022). We also found significant reductions in seroma volume (P=0.043), total drainage amount (P=0.002), indwelling period of drainage (P=0.01), and frequency of aspiration (P=0.043). The quilting sutures did not affect the rate of drainage, tube reinsertion, or hospital stay.

Conclusions The use of quilting sutures combined with fibrin sealant on the latissimus dorsi flap donor site is helpful for reducing the overall seroma volume, frequency of aspiration, and total drainage amount.

Keywords Mammoplasty / Surgical flaps / Seroma / Suture techniques

Correspondence: Dae Hyun Lew
Institute for Human Tissue Restoration, Department of Plastic and Reconstructive Surgery, Yonsei University College of Medicine, 250 Seongsan-ro, Seodaemun-gu, Seoul 120-752, Korea
Tel: +82-2-2228-2217
Fax: +82-2-393-6947
E-mail: dhlew@yuhs.ac

This article was presented as a poster at the 69th Congress of the Korean Society of Plastic and Reconstructive Surgeons on November 11, 2011 in Seoul, Korea.

No potential conflict of interest relevant to this article was reported.

Received: 2 May 2012 • Revised: 28 Jun 2012 • Accepted: 11 Jul 2012
pISSN: 2234-6163 • eISSN: 2234-6171 • <http://dx.doi.org/10.5999/aps.2012.39.5.509> • Arch Plast Surg 2012;39:509-513

INTRODUCTION

Latissimus dorsi flap is popular for breast reconstruction because it is well vascularized, stable, and easy to approach. Since Hokin [1] proposed latissimus dorsi flap for breast reconstruction, latissimus dorsi (LD) musculocutaneous flap, extended LD flap, or mini LD flap have progressively been used for early immediate breast reconstruction and delayed breast reconstruction

[2,3]. Unfortunately, donor site seroma is the most common complication of latissimus dorsi flap for breast reconstruction. The effective and timely provision of breast cancer treatment is particularly hampered by the development of postoperative seroma in approximately 15% to 81% of patients undergoing surgery [4]. Recently, seroma incidence has been reported to be 6% to 80% in cases of autogenous LD flap reconstruction and LD-implant reconstruction [5-7]. The development of seroma after

breast surgery is multifactorial, including a variety of dissection sizes, a result of shearing between subcutaneous tissue and underlying muscle, dead space, leakage from the disruption of the lymphatic and vascular channels, and inflammatory processes [8]. Seroma can be a significant source of a patient's discomfort, anxiety, infection, wound dehiscence, and consequently, flap necrosis, and scars [9,10]. For the prevention of donor site seroma, a variety of treatment measures such as electrocautery, endoscopic harvest, compression garment, repetitive aspiration, sclerotherapy, steroid injection, prolonged drainage, and capsulectomy have been described [7,11]. However, these treatments and preventive measures have not been uniformly successful.

Some studies have reported that fibrin sealant was useful for preventing seroma in a rat model, and the rate of seroma formation had been reduced from 90% to 20% using fibrin sealant [9,12]. Fibrin sealant has been described as a useful agent for reducing seroma after various surgical procedures, skin grafts, and cosmetic procedures [13,14]. Fibrin sealant plays a role as an adhesive agent in wound healing. Fibrin sealant is a mixture of fibrinogen and collagen. When the two solutions are mixed together in the presence of ionized calcium and fibronectin, the thrombin rapidly cleaves the fibrinogen to the fibrin. Fibrin polymers form a fibrin clot that is strengthened by a factor VIII-induced cross-linking [15]. Fibrin sealant decreases dead space, seals open lymphatic channels, achieves rapid hemostasis of large oozing raw surfaces, and adheres two raw surfaces together.

The commonly used modality for preventing seroma is quilting of the LD donor site. The use of quilting sutures to eliminate dead space under the flap has been reported to reduce the incidence of postoperative seroma formation in a variety of surgical procedures [16]. Recently, many studies in breast reconstruction surgery have shown that the use of quilting sutures of the LD donor site is useful in seroma prevention [11,17-20].

Furthermore, several studies [17-20] have reported that a combination of fibrin sealant and quilting sutures reduced seroma formation and total drainage. However, no comparative studies of an only fibrin sealant group and a combination of fibrin sealant and quilting suture group have been reported in breast reconstruction. We postulated that combining these two modalities could synergistically reduce the seroma rate and drainage volume compared to using fibrin sealant alone.

METHODS

A non-randomized retrospective study was conducted on 46 patients who underwent breast reconstruction with extended latissimus dorsi flaps between August 2010 and September 2011. The control group consisted of 25 patients who under-

went breast reconstruction with extended latissimus dorsi flap between November 2010 and March 2011. The experimental quilting suture group consisted of 21 patients who underwent breast reconstruction with extended latissimus dorsi flap between April and August 2011. The patients' charts were reviewed and information regarding age, body mass index (BMI), type of reconstruction, flap size, seroma volume, frequency of aspiration, reinsertion of drain, volume of drainage, indwelling period of drainage, and hospital stay was recorded.

Surgical techniques

A single surgeon performed the flap harvest and donor site closures in both groups. A transverse skin paddle was included. The extended latissimus dorsi flap size was approximately 2 to 3 cm, largely designed in reference to the removed breast tissue. Dissection of the flap was accomplished using electrocautery with a Colorado tip (Microneedle, ConMed Corporation, Utica, NY, USA) for minimizing thermal injury via an open technique. Adipose tissue was incorporated in the flap. The thoracodorsal nerve was transected, and the flap was transposed anteriorly. After meticulous electrocautery of noticeable donor bleeding, saline irrigation was performed. Two drainage tubes (HemoVAC, 200 mL) were inserted. The location and number of drainage tubes was the same for all patients. The control group (group 1) had the donor site closed with fibrin sealant (Tisseel, Baxter International Inc., Utica, NY, USA). The cavity was evenly sprayed with 4 mL of fibrin sealant using a spray device. Pressure was applied to the skin flaps for 3 minutes to ensure the obliteration of dead space. In the study group (group 2), one row of 2/0 polyglactin (Vicryl, Ethicon Inc., Somerville, NJ, USA) sutures was used at the three points (lateral, middle, medial side) of each skin flap (Fig. 1). Fibrin sealant was applied in the same manner as used in the control group. Both groups had standard postoperative care. All of the volumes and durations of wound drainage were recorded postoperatively. When the drainage was less than 20 mL over a 24-hour period, the drainage tubes were removed. In a postoperative clinical review, all symptomatic donor site seromas were aspirated, and the volumes were recorded.

Outcome measures

The primary outcome measures were the incidence and volume of postoperative seroma. A seroma was defined as the aspirated volume at the donor site above 10 mL or having to perform aspiration at least twice. Aspiration was performed using an aseptic technique; the total volume and frequency were recorded.

Secondary outcome measures were the total drainage, indwelling period of drainage, length of hospital stay, and rate of drainage reinsertion.

Statistical analysis

Patient data were collated and inputted into a spreadsheet (Microsoft Excel 2007, Microsoft, Redmond, WA, USA). Statistical analysis was performed using PASW Statistics ver. 18.0 (IBM Corp., New York, NY, USA), the independent t test (age, body mass index, and indwelling period), Mann-Whitney U test (flap size, volume of seroma, frequency of aspiration, volume of drainage, and hospital stay), Pearson's chi-squared test (seroma rate) and Fisher's exact test (HemoVAC reinsertion rate) were used to analyze the effects of interventions. We assumed that there was statistical significance if the P-value was less than 0.05. All the results were shown as mean ± standard deviation or median (interquartile range).

RESULTS

The average age of all the patients was 45 years, the average body mass index was 22.9 ± 2.9 kg/m², and the average flap size was 362.0 ± 97.1 cm². There were no statistically significant differences between the two groups with regard to age, body mass index, and flap size (Table 1).

	Group 1: fibrin sealant alone (n = 25)	Group 2: quilting sutures with fibrin sealant (n = 21)	P-value
No.	25	21	
Age	46.1 ± 9.0	44.0 ± 5.9	0.35 ^{a)}
Body mass index (kg/m ²)	23.5 ± 3.0	22.1 ± 2.7	0.1 ^{b)}
Immediate breast reconstruction	24	20	
Delayed breast reconstruction	1	1	
Flap size (cm ²)	391.0 (280.0-432.0)	369.8 (342.0-403.5)	0.64

Values are presented as mean ± standard deviation or Median (interquartile range).
^{a)}Independent t test; ^{b)}Mann-Whitney U test.

Seroma and drainage

The incidence of seroma was 76% in group 1 and 42.9% in group 2 (odds ratio, 0.24; relative risk, 0.56; P < 0.05) (Table 2). The seroma volumes were decreased with quilting sutures from a median of 45.0 mL (25.0-160.0 mL) to 30.0 mL (20.0-46.7 mL) (P = 0.022). Quilting sutures reduced the frequency of aspiration from a median of 3.0 (2.0-4.0) times to 2.0 (1.0-2.25) times (P = 0.043). However, quilting sutures did not reduce the rate of drainage reinsertion (P = 0.61) (Table 2).

The median total volume of drainage was significantly higher in group 1 (1,228.6 mL [824.2 to 2,078.0 mL]) than group 2 (754.8 mL [623.7 to 925.2 mL]; P = 0.002). The mean indwelling period of the drains was 15.8 days in group 1 and 12.1 days in group 2 (P = 0.01). However, the period of hospital stay was not statistically significantly different between the two groups (P = 0.36) (Table 3). The average daily drainage was consistently lower for group 2 (Fig. 2).

DISCUSSION

The extended latissimus dorsi flap is safe, reliable, and popular for breast reconstruction. However, donor site seroma has been reported in up to 80% of patients who undergo breast reconstruction with extended latissimus dorsi flap [5-7]. Patients who

	Group 1: fibrin sealant alone (n = 25)	Group 2: quilting sutures with fibrin sealant (n = 21)	P-value
No. of seroma	19	9	
Rate of seroma formation (%)	76	42.9	0.022 ^{a)}
Volume of seroma (mL)	45.0 (25.0-160.0)	30.0 (20.0-46.7)	0.043 ^{b)}
Frequency of aspiration	3.0 (2.0-4.0)	2.0 (1.0-2.25)	0.043 ^{b)}
HemoVAC reinsertion (%)	12	4.8	0.61 ^{c)}

Values are presented as median (interquartile range).
^{a)}Pearson's χ^2 test; ^{b)}Mann-Whitney U test; ^{c)}Fisher's exact test.

Fig. 1. Intraoperative picture

(A) Location of drain tubes. (B, C) Quilting sutures (black arrows).

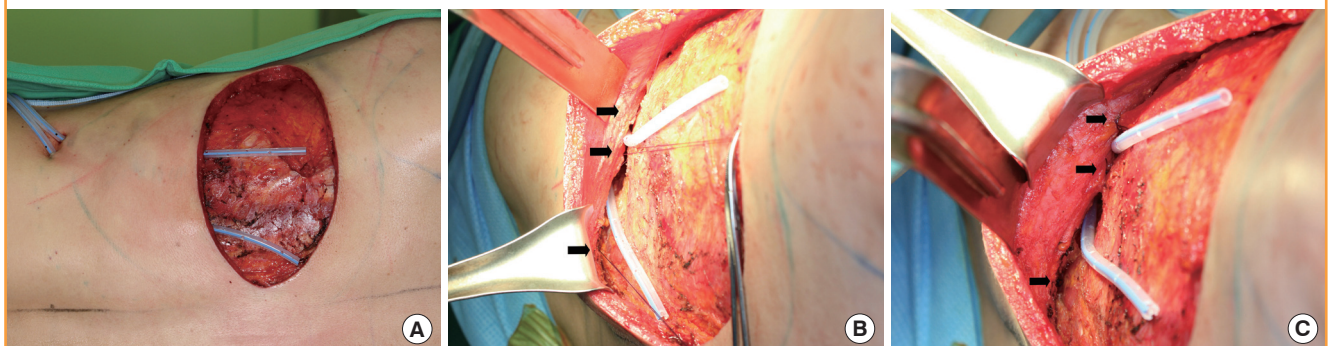


Table 3. Results for secondary outcome measures

	Group 1: fibrin sealant alone (n = 25)	Group 2: quilting sutures with fibrin sealant (n = 21)	P-value
Volume of drainage (mL)	1,228.6 (824.2-2,078.0)	754.8 (623.7-925.2)	0.002 ^{a)}
Indwelling period of drainage (day)	15.8 ± 5.9	12.1 ± 3.9	0.01 ^{b)}
Hospital stay (day)	14.0 (13.0-15.0)	13.4 (11.7-15.3)	0.36 ^{a)}

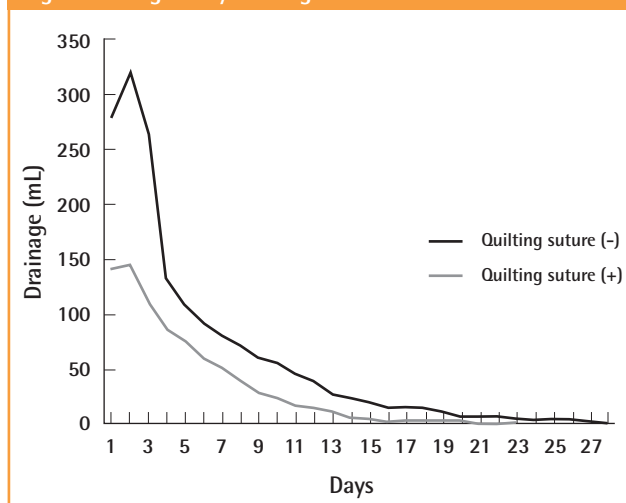
Values are presented as mean ± standard deviation or median (interquartile range).
^{a)}Mann-Whitney U test; ^{b)}Independent t test.

have suffered from seroma need repetitive aspiration in a post-operative clinical review. Occasionally, aspiration fails to remove seromas, which then requires reoperation to facilitate debridement of fibrinous loculations. Prevention of seromas decreases patient morbidity and the additional cost for treatment. The reduction of seroma also avoids delaying adjuvant chemotherapy and radiotherapy.

The cause of seroma seems to be multifactorial, although the etiology of seroma formation remains unknown. Schwabegger et al. [7] suggested that the use of electrocautery is a major causative factor in seroma formation after harvesting a latissimus dorsi flap, and it was postulated that thermal damage to tissue increases the incidence of seroma. We performed electrocautery with a Colorado needle to decrease thermal injury. Even if thermal injury had contributed to seroma formation in our patients, a single surgeon performed the flap harvest, thus this should not affect the group comparison. Taghizadeh et al. [21] reported that immediate breast reconstruction contributed to a higher rate of initial seroma, and they assumed that this resulted from axillary nodal dissection. Jain et al. [22] and Watt-Boolsen et al. [23] suggested that seroma could be plasma filtrates, either in the form of protein-poor transudates or a lymphatic leak. Alternatively, they proposed that it may be secondary to increase capillary permeability, resulting in protein-rich exudates, which are often observed during the inflammatory phase of wound healing. Interestingly, several studies have been shown that drains can act as irritants by prolonging the inflammatory phase, thus contributing to seroma formation [19,21].

Seroma formation occurs from extensive surgical dissection and disruption of tissue that results in a dead space while communicating with other areas of dissection following a mastectomy, axillary lymph node dissection, and LD muscle harvest [5,22,24]. Fibrin sealant and quilting sutures partly aim to restore the integrity of tissue planes and remove dead space. Saltz et al. [13] reported that fibrin sealant used in various surgical circumstances reduced seroma formation. Recently, Ali et al.

Fig. 2. Average daily drainage amount



[19] and Dancy et al. [20] have reported that a combination of fibrin sealant and quilting sutures reduced seroma formation, frequency of aspiration, and length of the drainage period, which was superior to the use of quilting sutures alone. The cost of fibrin sealant is approximately ₩315,000 (about 280USD) for each 4 mL kit. This cost is offset by reduced drainage and postoperative visits. Moreover, the decrease in a patient’s inconvenience and discomfort is invaluable.

Titely et al. [11] described a quilting technique performed in 10 patients who underwent a latissimus dorsi harvest. They quilted the skin flaps to the underlying tissue using 2/0 polydioxanone interrupted sutures every 3 to 4 cm in multiple layers. Seroma rates reduced from 56% to 0% after the quilting technique was used. Daltrey et al. [17] reported on a randomized trial of 108 patients who underwent classic and extended latissimus dorsi harvest. They performed multi-layered quilting using 2/0 vicryl interrupted sutures 3 to 4 cm apart in multiple layers. Seroma rates was reduced from 95% to 83%. Following these studies, Gisquet et al. [18] described that quilting sutures were also effective for reducing donor site seroma.

Several authors have presented the shearing effect of skin flaps against the underlying structures and dead space between the two planes [10,11]. Quilting sutures eliminate dead space and shearing forces; their use reduced seroma in our study from 76% to 42.9%.

This is the first study comparing a fibrin sealant only group to a combination of fibrin sealant and quilting suture group. We have shown that the combination of fibrin sealant and quilting suture is significantly superior to fibrin sealant alone for reducing the seroma rate, seroma volume, total drainage amount, and length of drain indwelling period with proportionately fewer aspirations. It also led to a decrease in postoperative visits for aspirations,

which decreased the patients' discomfort and inconvenience as well. However, it did not affect the length of hospital stay.

Multidisciplinary preventative strategies for reducing seroma should be designed and implemented depending on the predisposing risk factors. This study proposes that a combination of fibrin sealant and quilting sutures for an extended LD donor site closure may be an effective procedure to avoid donor-site seroma and related morbidity. However, our study is retrospective; thus, a major multicenter randomized controlled trial is required to provide powerful and reliable evidence.

REFERENCES

- Hokin JA. Mastectomy reconstruction without a prosthetic implant. *Plast Reconstr Surg* 1983;72:810-8.
- Min SY, Kim HY, Jung SY, et al. Oncological safety and quality of life associated with mastectomy and immediate breast reconstruction with a latissimus dorsi myocutaneous flap. *Breast J* 2010;16:356-61.
- Rusby JE, Paramanathan N, Laws SA, et al. Immediate latissimus dorsi miniflap volume replacement for partial mastectomy: use of intra-operative frozen sections to confirm negative margins. *Am J Surg* 2008;196:512-8.
- Woodworth PA, McBoyle MF, Helmer SD, et al. Seroma formation after breast cancer surgery: incidence and predicting factors. *Am Surg* 2000;66:444-50.
- Clough KB, Louis-Sylvestre C, Fitoussi A, et al. Donor site sequelae after autologous breast reconstruction with an extended latissimus dorsi flap. *Plast Reconstr Surg* 2002;109:1904-11.
- Roy MK, Shrota S, Holcombe C, et al. Complications of latissimus dorsi myocutaneous flap breast reconstruction. *Eur J Surg Oncol* 1998;24:162-5.
- Schwabegger A, Ninkovic M, Brenner E, et al. Seroma as a common donor site morbidity after harvesting the latissimus dorsi flap: observations on cause and prevention. *Ann Plast Surg* 1997;38:594-7.
- Aitken DR, Hunsaker R, James AG. Prevention of seromas following mastectomy and axillary dissection. *Surg Gynecol Obstet* 1984;158:327-30.
- Kulber DA, Bacilius N, Peters ED, et al. The use of fibrin sealant in the prevention of seromas. *Plast Reconstr Surg* 1997;99:842-9.
- Reddick LP. Seroma after latissimus dorsi myocutaneous flap for breast reconstruction. *Plast Reconstr Surg* 1990;85:826.
- Titley OG, Spyrou GE, Fatah MF. Preventing seroma in the latissimus dorsi flap donor site. *Br J Plast Surg* 1997;50:106-8.
- Lindsey WH, Masterson TM, Spotnitz WD, et al. Seroma prevention using fibrin glue in a rat mastectomy model. *Arch Surg* 1990;125:305-7.
- Saltz R, Sierra D, Feldman D, et al. Experimental and clinical applications of fibrin glue. *Plast Reconstr Surg* 1991;88:1005-15.
- McCarthy C, Lennox P, Germann E, et al. Use of abdominal quilting sutures for seroma prevention in TRAM flap reconstruction: a prospective, controlled trial. *Ann Plast Surg* 2005;54:361-4.
- Gosain AK, Lyon VB; Plastic Surgery Educational Foundation DATA Committee. The current status of tissue glues: part II. For adhesion of soft tissues. *Plast Reconstr Surg* 2002;110:1581-4.
- Nahas FX, Ferreira LM, Ghelfond C. Does quilting suture prevent seroma in abdominoplasty? *Plast Reconstr Surg* 2007;119:1060-4.
- Daltrey I, Thomson H, Hussien M, et al. Randomized clinical trial of the effect of quilting latissimus dorsi flap donor site on seroma formation. *Br J Surg* 2006;93:825-30.
- Gisquet H, Delay E, Paradol PO, et al. Prevention of seroma by quilting suture after harvesting latissimus dorsi flap. The "Chippendale" technic. *Ann Chir Plast Esthet* 2010;55:97-103.
- Ali SN, Gill P, Oikonomou D, et al. The combination of fibrin glue and quilting reduces drainage in the extended latissimus dorsi flap donor site. *Plast Reconstr Surg* 2010;125:1615-9.
- Dancey AL, Cheema M, Thomas SS. A prospective randomized trial of the efficacy of marginal quilting sutures and fibrin sealant in reducing the incidence of seromas in the extended latissimus dorsi donor site. *Plast Reconstr Surg* 2010;125:1309-17.
- Taghizadeh R, Shoaib T, Hart AM, et al. Triamcinolone reduces seroma re-accumulation in the extended latissimus dorsi donor site. *J Plast Reconstr Aesthet Surg* 2008;61:636-42.
- Jain PK, Sowdi R, Anderson AD, et al. Randomized clinical trial investigating the use of drains and fibrin sealant following surgery for breast cancer. *Br J Surg* 2004;91:54-60.
- Watt-Boolsen S, Nielsen VB, Jensen J, et al. Postmastectomy seroma. A study of the nature and origin of seroma after mastectomy. *Dan Med Bull* 1989;36:487-9.
- Pogson CJ, Adwani A, Ebbs SR. Seroma following breast cancer surgery. *Eur J Surg Oncol* 2003;29:711-7.

Discussion**The Use of Fibrin Sealant for the Reduction of Seroma**

Taik Jong Lee

Department of Plastic Surgery, Asan Medical Center, University of Ulsan College of Medicine, Seoul, Korea

“Efficacy of quilting sutures and fibrin sealant together for prevention of seroma in extended latissimus dorsi (ELD) flap donor sites”: In this article, the authors compared the efficacy of fibrin sealant alone with a combination of fibrin sealant and quilting sutures for prevention of seroma in ELD flap donor sites. Their 46 patients underwent mastectomy and ELD flap reconstruction and the two groups were homogenous except for the quilting sutures. They showed significantly greater reduction in the incidence (76 to 43 percent), total drainage amount, seroma volume, and so on in the combination group relative to the fibrin sealant only group.

“Does fibrin sealant reduce seroma after immediate breast reconstruction utilizing a latissimus dorsi (LD) myocutaneous (MC) flap?”: The authors of this article questioned the efficacy of fibrin sealant in prevention of seroma after LD flap breast reconstruction. Their patients all underwent partial mastectomy and axillary dissection, followed by immediate reconstruction utilizing LD flap. The two groups of patients (23 each) were equivalent except for the use of fibrin sealant spray. Interestingly, there was no delayed onset of seroma formation in all cases. They failed to show a significant benefit of using fibrin sealant for the prevention of seroma or reduction of the total amount of drainage or maintenance duration of the drains. The authors suggested the possibility that a tissue reaction had been elicited, or that dissolution and drainage of the material had occurred in speculating on the ineffectiveness of the fibrin glue.

These two articles have several commonalities. Firstly, both focused on the reduction of donor site seroma after LD or ELD flap breast reconstruction. Secondly, both have two homogeneous groups who underwent surgery by the same surgeon, having only one variable to compare. However, aside from the main procedure that was performed, there are important differences between the two studies. For example, one deals with complete mastectomy followed by ELD reconstruction while the other deals with partial mastectomy reconstructed with LD flap. De-

tails such as the definition of seroma used in the diagnosis and the method of drain insertion are also somewhat different.

The authors of the article “Does fibrin sealant . . .?” reported that the use of fibrin sealant in the LD flap donor site is not effective in reduction of drainage amount or duration. Surprisingly, few studies have reported the efficacy of fibrin sealant in the prevention of LD flap donor site seroma. One report using a rat LD flap model advocated the effectiveness of fibrin sealant [1]. However, other studies with stronger evidence have postulated that the use of fibrin glue does not prevent or reduce seroma incidence or magnitude [2,3]. Although the above-mentioned reports are not restricted to the LD flap donor site, one could anticipate that fibrin sealant alone, that is, without quilting sutures, does not have obvious benefit for prevention of LD flap donor site seroma.

On the other hand, quilting sutures have been reported to significantly reduce seroma formation after LD flap elevation [4,5]. The benefit of quilting sutures has been shown in other procedures such as abdominoplasty or transverse rectus abdominus myocutaneous (TRAM) flap elevation [6,7], and the suggested mechanisms include obliteration of the dead space and dispersion of tension. In short, there seems to be a consensus that quilting the donor site is generally effective in reducing seroma formation [6-8]. Recently a systematic review concluded that quilting suture is effective in prevention of LD donor site seroma, and combining quilting with fibrin glue further enhances its effectiveness [9]. Ali et al. [10] also showed that the combination of fibrin glue and quilting reduced drainage in the ELD donor site, compared with a quilting only group. They presumed that fibrin glue alone cannot maintain its integrity when under the stress of the shearing forces produced by movements of the torso when reclined in bed postoperatively. The authors of the article “Efficacy of quilting . . .” frankly reported a significant reduction in the incidence of seroma by adding the quilting sutures compared with using fibrin sealant alone. Economic as well as clinical benefits were evident as shown in reduction of the total amount and duration of seroma, reduction of drain re-insertion, and so on.

Donor site seroma still seems to be one of the major problems in LD or ELD flap breast reconstruction and efforts have been made to determine the best approach to preventing it. In short, fibrin sealant alone does not seem to be consistently effective. Quilting sutures, on the other hand, have been reported to be helpful in the prevention of LD donor site seroma, and a combination of quilting sutures and fibrin glue seems

to be even more effective. Now in the era of evidence-based medicine, we must take note of the best-designed studies in the literature as we reconsider how to prevent LD donor site seroma.

REFERENCES

1. Kulber DA, Baciliou N, Peters ED, et al. The use of fibrin sealant in the prevention of seromas. *Plast Reconstr Surg* 1997;99:842-9.
2. Carless PA, Henry DA. Systematic review and meta-analysis of the use of fibrin sealant to prevent seroma formation after breast cancer surgery. *Br J Surg* 2006;93:810-9.
3. Cipolla C, Fricano S, Vieni S, et al. Does the use of fibrin glue prevent seroma formation after axillary lymphadenectomy for breast cancer? A prospective randomized trial in 159 patients. *J Surg Oncol* 2010;101:600-3.
4. Titley OG, Spyrou GE, Fatah MF. Preventing seroma in the latissimus dorsi flap donor site. *Br J Plast Surg* 1997;50:106-8.
5. Daltrey I, Thomson H, Hussien M, et al. Randomized clinical trial of the effect of quilting latissimus dorsi flap donor site on seroma formation. *Br J Surg* 2006;93:825-30.
6. Lee MY, Lee TJ. Does abdominal quilting suture prevent seroma in TRAM flap breast reconstruction? *J Korean Soc Plast Reconstr Surg* 2011;38:241-4.
7. Nahas FX, Ferreira LM, Ghelfond C. Does quilting suture prevent seroma in abdominoplasty? *Plast Reconstr Surg* 2007;119:1060-4.
8. Dancey AL, Cheema M, Thomas SS. A prospective randomized trial of the efficacy of marginal quilting sutures and fibrin sealant in reducing the incidence of seromas in the extended latissimus dorsi donor site. *Plast Reconstr Surg* 2010;125:1309-17.
9. Sajid MS, Betal D, Akhter N, et al. Prevention of postoperative seroma-related morbidity by quilting of latissimus dorsi flap donor site: a systematic review. *Clin Breast Cancer* 2011;11:357-63.
10. Ali SN, Gill P, Oikonomou D, et al. The combination of fibrin glue and quilting reduces drainage in the extended latissimus dorsi flap donor site. *Plast Reconstr Surg* 2010;125:1615-9.

Correspondence: Taik Jong Lee
 Department of Plastic Surgery, Asan Medical Center, University of Ulsan College of Medicine,
 88 Olympic-ro 43-gil, Songpa-gu, Seoul 138-736, Korea
 Tel: +82-2-3010-3600, Fax: +82-2-476-7471, E-mail: tjlee@amc.seoul.kr

No potential conflict of interest relevant to this article was reported.

Received: 13 Aug 2012 • Revised: 14 Aug 2012 • Accepted: 15 Aug 2012
 pISSN: 2234-6163 • eISSN: 2234-6171
<http://dx.doi.org/10.5999/aps.2012.39.5.514> • Arch Plast Surg 2012;39:514-515

Discussion**The Continuing Battles against Seroma in Latissimus Dorsi Flap Donor Sites**

Goo-Hyun Mun

Department of Plastic Surgery, Samsung Medical Center, Sungkyunkwan University School of Medicine, Seoul, Korea

Seroma is a common and a frustrating complication of latissimus dorsi (LD) flap. It can lead to wound infection, skin flap necrosis, dehiscence and finally increased morbidity and cost. There have been many methods aimed at decreasing the incidence of seroma formation after LD flap harvest. These include avoidance of electrocautery dissection, the use of “quilting sutures” and/or fibrin sealant, endoscopic or robotic harvest, pressure dressings, sclerotherapy, and finally reoperation with capsulectomy [1]. Among them, the two main approaches nowadays are the application of fibrin sealant and quilting suture [2].

In this article “Does fibrin sealant reduce seroma after immediate breast reconstruction utilizing a latissimus dorsi myocutaneous flap?” the authors reported that the benefit of fibrin sealant is not clear and the use of this material should be prudently considered. For a total of 46 patients who underwent immediate breast reconstruction with LD flap after skin sparing partial mastectomy, the authors analyzed the daily cumulative drainage fluid volume and total drainage volume. There are conflicting studies regarding the efficacy of fibrin sealants in reducing seroma formation [2,3]. However, plenty of experimental and clinical studies show the reduction in the amount of drainage, seroma formation, and hospital stay in fibrin sealant. This study was performed in the setting of partial breast reconstruction after breast conserving surgery. Though their mean volume was slightly over 300 g, the extent of elevated LD muscle, skin, and subcutaneous fat might not have been extensive. Surprisingly, the authors noted no delayed seroma in their entire series. I suspect that the effect of fibrin sealant might become more evident

in seroma-prone conditions such as in extended LD flap for total breast reconstruction.

The authors of “The efficacy of quilting sutures and fibrin sealant for prevention of the seroma in the extended latissimus dorsi flap donor site” reported that quilting sutures with fibrin sealant is an effective approach to reducing seroma formation. Within the article, the authors concluded that the seroma incidence rate, seroma volume, total drainage volume, indwelling period of the drainage tube, and frequency of aspiration were lesser in the group that underwent quilting sutures with fibrin sealant than fibrin sealant only. Recently, the effect of combining quilting sutures with fibrin glue for LD flap donor sites has been studied. The combination of fibrin sealant and quilting sutures on the LD donor site reduced the volume of seroma drainage, the length of hospital stay, and the total seroma formation compared to those of the quilting suture only group [1,4,5]. This study was designed to compare the combination effect with a different control group, fibrin sealant only.

It would be interesting to compare the results with those of the former report [1] (Table 1). Overall, when judged by simple comparison, the quilting effect is stronger than the fibrin sealant effect in the reduction of seroma occurrence.

The current two studies are limited by their ‘retrospective chart review’ design. In recent reports on seroma in LD flap donor sites, prospective or well-designed retrospective cohort studies was undertaken. Although these two papers provided an insight on fibrin sealant and quilting sutures for reducing seroma formation in LD flap donor sites, a large-scale randomized controlled study is still required to obtain more reliable evidence before these techniques become our routine procedure.

REFERENCES

1. Dancey AL, Cheema M, Thomas SS. A prospective randomized trial of the efficacy of marginal quilting sutures and fibrin sealant in reducing the incidence of seromas in the extended latissimus dorsi donor site. *Plast Reconstr Surg*

Table 1. Comparison of seroma formation, seroma volume, and total drainage

	Dancey et al., 2010 [1]			Shin et al., Arch Plast Surg 2012;39:509-513		
	Quilting	Fibrin+quilting	Differential (%)	Fibrin	Fibrin+quilting	Differential (%)
Seroma incidence	3/13 (23.1%)	1/13 (7.7%)	15.4	19/25 (76%)	9/21 (42.9%)	33.1
Total drainage (mL)	1,045	680	34.9	1,228.6	754.8	38.6

- 2010;125:1309-17.
2. Kulber DA, Bacilious N, Peters ED, et al. The use of fibrin sealant in the prevention of seromas. *Plast Reconstr Surg* 1997;99:842-9.
 3. Sajid MS, Betal D, Akhter N, et al. Prevention of postoperative seroma-related morbidity by quilting of latissimus dorsi flap donor site: a systematic review. *Clin Breast Cancer* 2011;11:357-63.
 4. Ali SN, Gill P, Oikonomou D, et al. The combination of fibrin glue and quilting reduces drainage in the extended latissimus dorsi flap donor site. *Plast Reconstr Surg* 2010;125:1615-9.
 5. Bailey SH, Oni G, Guevara R, et al. Latissimus dorsi donor-

site morbidity: the combination of quilting and fibrin sealant reduce length of drain placement and seroma rate. *Ann Plast Surg* 2012;68:555-8.

Correspondence: Goo-Hyun Mun

Department of Plastic Surgery, Samsung Medical Center, Sungkyunkwan University School of Medicine, 81 Irwon-ro, Gangnam-gu, Seoul 135-710, Korea

Tel: +82-2-3410-2233, Fax: +82-2-3410-0036, E-mail: supramicro@gmail.com

No potential conflict of interest relevant to this article was reported.

Received: 3 Sep 2012 • Revised: 4 Sep 2012 • Accepted: 5 Sep 2012

pISSN: 2234-6163 • eISSN: 2234-6171

<http://dx.doi.org/10.5999/aps.2012.39.5.516> • Arch Plast Surg 2012;39:516-517
