

LETTER

Reply: Multiple Large Cysts Arising from Nevus Comedonicus

Hii-Sun Jeong¹, Hye-Kyung Lee¹, Seung-Hyun Lee¹, Hyoung-Suk Kim¹, Sang-Yeop Yi²

Departments of ¹Plastic and Reconstructive Surgery, and ²Pathology, Myongji Hospital, Kwandong University College of Medicine, Goyang, Korea

Correspondence: Hii-Sun Jeong

Department of Plastic and Reconstructive Surgery, Myongji Hospital, Kwandong University College of Medicine, 55 Hwasu-ro 14beon-gil, Deokyang-gu, Goyang 412-826, Korea
Tel: +82-31-810-6830, Fax: +82-31-810-6837, E-mail: hiiusunj@gmail.com

No potential conflict of interest relevant to this article was reported.

Received: 2 May 2012 • Revised: 2 May 2012 • Accepted: 3 May 2012

pISSN: 2234-6163 • eISSN: 2234-6171

http://dx.doi.org/10.5999/aps.2012.39.3.261 • Arch Plast Surg 2012;39:261

Copyright © 2012 The Korean Society of Plastic and Reconstructive Surgeons
This is an Open Access article distributed under the terms of the Creative Commons Attribution Non-Commercial License (<http://creativecommons.org/licenses/by-nc/3.0/>) which permits unrestricted non-commercial use, distribution, and reproduction in any medium, provided the original work is properly cited.

We appreciate Dr. Yu Jin Kim for her insightful commentary on our recent article [1]. The additional masses that are mentioned in Dr. Yujin Kim's commentary were attached to the two masses shown on the left side of the gross specimen figure, each with its own epidermal layer [1,2]. The epidermal cyst in the center of the coronal computed tomography image is that which had the foreign body reaction noted by histology (Figs. 1, 2). Likewise, this same cyst is the one that was found to be mildly warm during pre-operative clinical examination.

Our statement that cites Reference 7 was intended to describe skin appendage tumors as having pathologic findings of nevus comedonicus [1-3]. We agree with the opinion that your article should

have been more appropriately referenced in the discussion about direct pathologic findings and surgical treatments. Your advice is acknowledged and appreciated.

In the present case report, we tried to present the possibility that nevus comedonicus in the shallow epidermal layer can progress to a subcutaneous giant epidermal cyst as a late complication. In other words, nevus comedonicus should be considered in the differential diagnosis of other deep subcutaneous tumors.

Conservative treatments are aimed at reducing the formation of comedones and/or controlling infection. Considering surgical treatment, ordinary excision can be performed on localized lesions, including small pits [3,4]. In the case of an extensive lesion, wide excision and tissue expander reconstruction may be used [5]. In the present case, the dilated comedone was large enough to be explored by a probe. During exploration, the comedones seemed to have pits up to 1 cm in size, thus a wide excision with a 1 cm margin was selected in our case. Finally, we believe that the treatment modality chosen should be based on the level of the patient's discomfort, in addition to aesthetic concerns, scar formation, abscesses, and epidermal inclusion cysts.

References

1. Kim YJ. Letter: Multiple large cysts arising from nevus comedonicus. Arch Plast Surg. 2012;39:173-74.
2. Jeong HS, Lee HK, Lee SH, et al. Multiple large cysts arising from nevus comedonicus. Arch Plast Surg 2012;39:63-6.
3. Kim YJ, Hong CY, Lee JR. Nevus comedonicus with multiple cyst. J Korean Cleft Palate-Craniofac Assoc 2009;10:135-7.
4. Marcus J, Esterly NB, Bauer BS. Tissue expansion in a patient with extensive nevus comedonicus. Ann Plast Surg 1992;29:362-6.
5. Kargi E, Koca R, Ali Sahin D, et al. Nevus comedonicus. Plast Reconstr Surg 2003;112:1183-5.

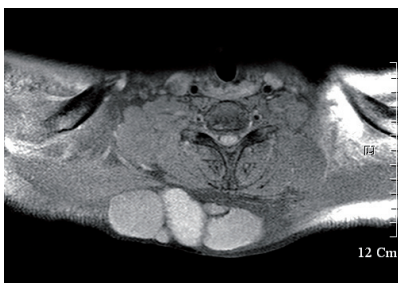

Fig. 1. Magnetic resonance imaging findings (T1 fat suppression image) of five epidermal cysts.

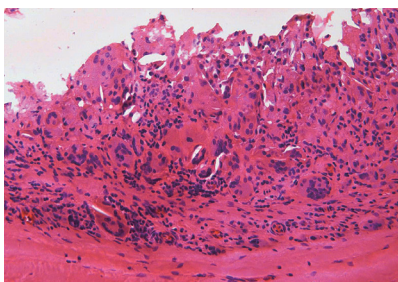


Fig. 2. Histopathological findings of the central epidermal cyst showed a foreign body reaction with multiple giant cells (H&E, ×20).