

detected in several cases [4]. In our case, immunohistochemical staining for vimentin was not performed. Positivity for vimentin implies that the tumor cells are of fibroblastic lineage. However, we were able to determine that with the satellite to spindle shape of cells.

Histopathologically, the tumors appear well-margined under low-power microscopic examination. The tumor cells are relatively stellate- and spindle-shaped fibroblastic cells separated by a densely fibrous to fibromyxoid matrix. These fibroblasts lack any atypical or hyperchromatic nuclei. Mitotic figures are very rare or absent, and tumor necrosis is not seen.

A wide variety of benign fibroblastic soft tissue tumors have been classified as fibroma. Among the entities included in this category are the nuchal fibroma, fibroma of the tendon sheath, sclerotic fibroma of the skin, and calcifying aponeurotic fibroma. Evens recently proposed an additional group--desmoplastic fibroblastoma. A general lack of awareness of this poorly recognized entity may lead to misdiagnosis of other soft tissue neoplasms because of the small number of reported examples. Miettinen and Fetsch [5] analyzed sixty-three cases of desmoplastic fibroblastoma from the files of the Armed Forces Institute of Pathology. Fifty-two of these cases were originally diagnosed as other tumors, including fibromatosis (n = 18), fibroma (n = 15), neurofibroma (n = 8), nodular fasciitis (n = 3), fibroma of the tendon sheath (n = 3), myxoma (n = 2) as well as chondroma, myofibroma, and myxoid lipoma (one case of each). The differential diagnosis of desmoplastic fibroblastoma includes benign, locally aggressive, and low grade malignant soft tissue tumors consisting of relatively uniform stellate- or spindle-shaped cells embedded in a myxocollagenous matrix, such as nodular fasciitis, fibromatosis, fibroma of the tendon sheath, nuchal fibroma, sclerotic fibroma of the skin, neurofibroma, solitary fibrous tumor, and low grade fibromyxoid sarcoma. Although desmoplastic fibroblastoma of the finger can be confused with fibroma of the tendon sheath, the latter is deeply attached to the tendon or tendon sheath. From a histological perspective, fibroma of the tendon sheath is more cellular and less homogeneous. It also differs from desmoplastic fibroblastoma because of a lobular growth pattern, with the lobules separated by cleftlike vascular spaces [3,5].

In conclusion, we present a rare case of desmoplastic fibroblastoma that developed on the finger with clinicopathologic and immunohistochemical features. Typically, this type of tumor has developed

as a firm, non-tender, slow growing mass in older males. Complete excision with functional preservation was performed and recurrence was not observed for 6 months after the operation. Despite a very small number of reported cases, desmoplastic fibroblastoma should be considered in a differential diagnosis for soft tissue tumors of the finger.

References

1. Evans HL. Desmoplastic fibroblastoma: a report of seven cases. *Am J Surg Pathol* 1995;19:1077-81.
2. Nishio J, Iwasaki H, Nishijima T, et al. Collagenous fibroma (desmoplastic fibroblastoma) of the finger in a child. *Pathol Int* 2002;52:322-5.
3. Hasegawa T, Shimoda T, Hirohashi S, et al. Collagenous fibroma (desmoplastic fibroblastoma): report of four cases and review of the literature. *Arch Pathol Lab Med* 1998;122:455-60.
4. Maghari A, Ma N, Aisner S, et al. Collagenous fibroma (desmoplastic fibroblastoma) with a new translocation involving 11q12: a case report. *Cancer Genet Cytogenet* 2009;192:73-5.
5. Miettinen M, Fetsch JF. Collagenous fibroma (desmoplastic fibroblastoma): a clinicopathologic analysis of 63 cases of a distinctive soft tissue lesion with stellate-shaped fibroblasts. *Hum Pathol* 1998;29:676-82.

Apocrine Hidrocystoma of the Cheek

Myung Jun Lee¹, Ho Jik Yang¹, Jong Hwan Kim¹, Hyung Woo Yim¹, Jong Min Lim¹, Hye Kyung Lee²

Departments of ¹Plastic and Reconstructive Surgery, and ²Pathology, Eulji University Hospital, Eulji University School of Medicine, Daejeon, Korea

Correspondence: Ho Jik Yang
Department of Plastic and Reconstructive Surgery, Eulji University Hospital, Eulji University School of Medicine, 95 Dunsanseo-ro, Seo-gu, Daejeon 302-799, Korea
Tel: +82-42-611-3029, Fax: +82-42-259-1111, E-mail: drhjyang@yahoo.co.kr

No potential conflict of interest relevant to this article was reported.

Received: 27 Jun 2011 • Revised: 26 Aug 2011 • Accepted: 27 Sep 2011
pISSN: 2234-6163 • eISSN: 2234-6171
<http://dx.doi.org/10.5999/aps.2012.39.1.86> • Arch Plast Surg 2012;39:86-88

Copyright © 2012 The Korean Society of Plastic and Reconstructive Surgeons
This is an Open Access article distributed under the terms of the Creative Commons Attribution Non-Commercial License (<http://creativecommons.org/licenses/by-nc/3.0/>) which permits unrestricted non-commercial use, distribution, and reproduction in any medium, provided the original work is properly cited.

Apocrine hidrocystomas commonly occur as a solitary cystic lesions and are very frequently located near the eye. They are thought to be benign skin

neoplasms derived from the secretory portion of the apocrine gland and usually present as a superficial, solitary, various-colored (skin-colored, light-brown, red-brown, bluish, or black) nodule on the periorbital area of the mid dermis layer [1]. It is interesting to note that whereas the axilla and the periorbital region are considered to be the most common sites of origin of apocrine hidrocystomas, the apocrine glands are usually located in the chest or perineum and only very rarely are located in the facial area [1]. So far, a total of 167 cases of apocrine hidrocystoma have been reported and systematically organized in Japan [2]. However, since the first report occurring on vagina of a 31-year-old female, only a few cases have been reported in Korea [3-5]. We, therefore, report a rare case of apocrine hidrocystoma occurring on the cheek in a 58-year-old female with a literature review.

A 58-year-old woman presented with a 10-year history of a painless mass on her right cheek. She had no notable past or family history except antihypertensive drug medication for hypertension. It had never bled or been infected. She had not noticed any increase in size with temperature or seasonal variation. The physical examination showed a mass measuring 15 × 15 mm on her cheek. The overlying skin was intact and the mass was smooth surfaced, dome shaped, and deep purple-colored (Fig. 1A). She was bothered by the mass only from a cosmetic point of view. Sonographically, a well-circumscribed cystic lesion measuring 13 × 15 mm was identified. However, there was no connection with any other adjacent structure (Fig. 1B). It was removed under local anesthesia. There was a distinct plane of dissection. Healing was uneventful. Macroscopic examination revealed a cyst of 18 × 15 × 12 mm in size, containing brownish, slimy fluid. The histopathologic examination showed cystic spaces in the subcutaneous layer (Fig. 2A). On microscopic examination, the dermis contained a multilocular cyst, lined by a cylindrical epithelium

of the apocrine secretory type. Beneath this was an outer layer of myoepithelial cells. The inner epithelial lining of the cyst was composed of columnar cells with eosinophilic cytoplasm and basally-located nuclei showing a “decapitation” secretion indicative of apocrine secretion (Fig. 2B, C). These histologic features are characteristic of apocrine hidrocystoma. A faint scar remained on her cheek at her two-month follow-up visit.

Apocrine hidrocystomas are benign cystic tumors that arise from the apocrine secretory coils. Though there are some references to multiple apocrine hidrocystomas in the literature, the most common presentation is a solitary lesion which is very frequently located near the eye. The incidence may not be known accurately, but it is estimated that it may be one per thousand of submitted cutaneous biopsies. However, presumed apocrine hidrocystomas located on the inner or outer canthus of the lower eyelid have the possibility of being Moll’s gland cysts [1]. Therefore, we can conclude the true incidence of apocrine hidrocystoma on the face may be lower than reported.

Solitary apocrine hidrocystomas have no seasonal variations, but multiple lesions have seasonal variations like eccrine hidrocystomas, which tend to appear more in hot and humid weather. Histologically, they are characterized by unilocular or multilocular cysts that are lined by a double lining of epithelium with the outer layer comprising flat myoepithelial cells and inner layer containing large columnar or cuboidal cells with eosinophilic cytoplasm and round or oval vesicular nuclei at the base of these cells. Decapitation secretion is a hallmark of apocrine hidrocystoma. A simple needle puncture is often done for a solitary lesion of hidrocystoma. It is also easily treated with simple excision [2-5].

According to the Japanese literature, locations of lesions of apocrine hidrocystomas in Japan were face (61.1%), scalp (12.6%), trunk (13.7%), and ex-

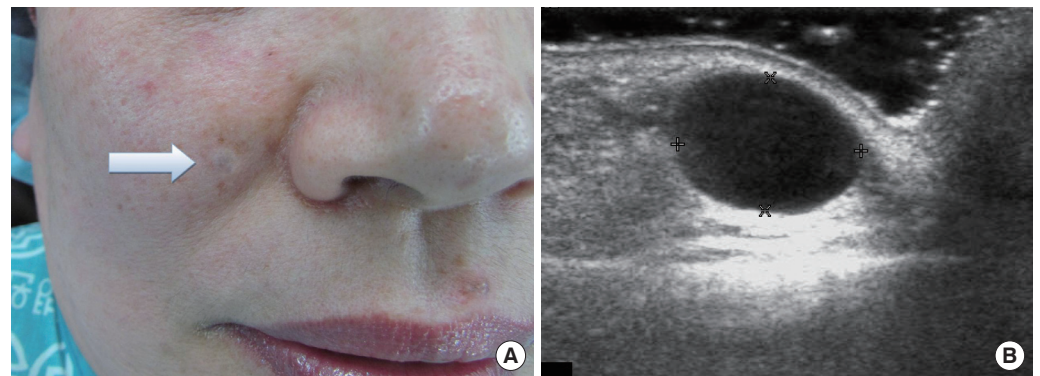


Fig. 1.
 (A) A dome-shaped, deep purple cystic mass (white arrow) on the right cheek.
 (B) A well-circumscribed cystic lesion without any other adjacent structure invasion, measuring 13 × 15 mm was identified sonographically.

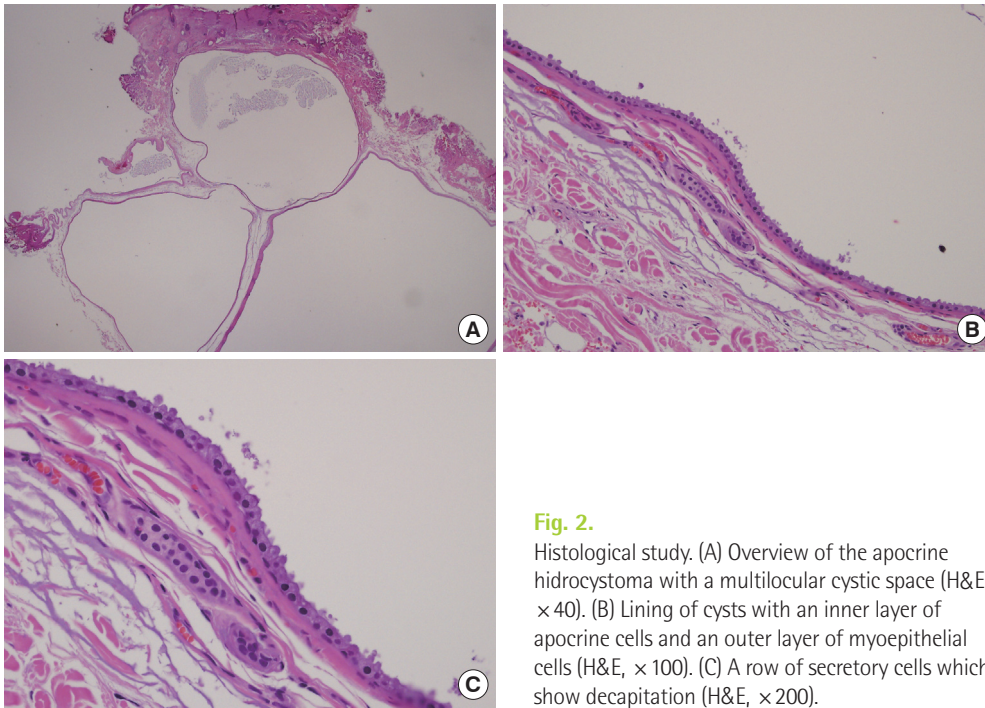


Fig. 2.

Histological study. (A) Overview of the apocrine hidrocystoma with a multilocular cystic space (H&E, ×40). (B) Lining of cysts with an inner layer of apocrine cells and an outer layer of myoepithelial cells (H&E, ×100). (C) A row of secretory cells which show decapitation (H&E, ×200).

Table 1. Literature review of apocrine hidrocystomas reported in Korea

Author	Sex/Age	Location	Size (mm)	Duration of disease (yr)
Han et al. [3]	F/31	Vagina	Rice sized	2
Kim et al. [4]	F/26	Left lower eyelid	Bean sized	10
Hwang et al. [5]	F/28	Anterior chest wall	Bean sized	Not mentioned

tremities (12.0%). The tumor seems to occur evenly in any age group, and in only 15 cases (9.0%) was the tumor found in apocrine gland-bearing regions, such as the axilla and groin [2]. However, we do not have properly compiled disease statistics in Korea. Among the papers that have been published in Korea to date, cases in the axilla and groin areas have not even been reported. The genital area, anterior chest wall, and eyelids were the only places. Considering the possibility of Moll's gland cysts, we can assume that only a few cases of apocrine hidrocystomas have been identified for certain in Korea so far (Table 1) [2-5]. This is a very small number of cases compared to Japan. In light of this disparity, we propose that the Korean medical community should systematize and strengthen the reporting system for not only this, but every disease, in order to generate more accurate medical statistics.

References

- McNiff J, McCalmont T, Sanguenza O, et al. Benign tumours with apocrine and eccrine differentiation. In: LeBoit P, Burg G, Weedon D, editors. World Health Organization Classification of Tumours: pathology and genetics of skin tumours. Lyon: IARC Press; 2006. p. 139-51.
- Anzai S, Goto M, Fujiwara S, et al. Apocrine hidrocystoma: a case report and analysis of 167 Japanese cases. *Int J Dermatol* 2005;44:702-3.
- Han KW, Myung KB, Kook HI. A case of apocrine hidrocystoma occurring in the female genitalia. *Korean J Dermatol* 1987;25:119-22.
- Kim HJ, Kim YT, Kim JH. A case of apocrine hidrocystoma. *Korean J Dermatol* 1992;30:407-10.
- Hwang SW, Cho KJ, Oh DJ, et al. Two pilosebaceous cysts with apocrine hidrocystoma in one biopsy site: a spectrum of the same disease process? *Ann Dermatol* 2008;20:11-3.