

How to Write a Scientific Paper: Three Tips to Remember

Kun Hwang

Department of Plastic Surgery, Inha University School of Medicine, Incheon, Kroea

Correspondence: Kun Hwang
Department of Plastic Surgery and the Center for Advanced Medical Education by the BK21 Project, Inha University School of Medicine, 27 Inhang-ro, Jung-gu, Incheon 400-711, Korea
Tel: +82-32-890-3514, Fax: +82-32-890-2918, E-mail: jokerhg@inha.ac.kr

No potential conflict of interest relevant to this article was reported.

Received: 10 Dec 2011 • Revised: 15 Dec 2011 • Accepted: 22 Dec 2011
pISSN: 2234-6163 • eISSN: 2234-6171
<http://dx.doi.org/10.5999/aps.2012.39.1.77A> • Arch Plast Surg 2012;39:77

Copyright © 2012 The Korean Society of Plastic and Reconstructive Surgeons
This is an Open Access article distributed under the terms of the Creative Commons Attribution Non-Commercial License (<http://creativecommons.org/licenses/by-nc/3.0/>) which permits unrestricted non-commercial use, distribution, and reproduction in any medium, provided the original work is properly cited.

In the field of plastic surgery, many new ideas and skills are developed by surgeons and researchers. “Publish or perish” is a phrase coined to describe the pressure in academia to publish work constantly to further or sustain one’s career [1]. To share knowledge or skill with others, or promote one’s position in schools, they should write papers. However, it is not easy to gather and develop writing material.

I learned an invaluable lesson at the International Confederation of Plastic, Reconstructive, and Aesthetic Surgery meeting which was held in Yokohama, Japan in 1995. At the opening ceremony, Dr. Joseph Murray who performed the first successful human kidney transplant on identical twins and who shared the Nobel Prize in Physiology or Medicine had the keynote lecture.

The elder retired plastic surgeon emphasized that scientists should remember 3 important words: curiosity, imagination, and persistence. Curiosity is an emotion related to natural inquisitive behavior such as exploration, investigation, and learning. We can have curiosity in any basic research or about surgical procedures. Imagination is the ability to form mental images, sensations and concepts, in a moment when they are not perceived through sight, hearing, or the other senses. Lastly, persistence is the determination to do something even though it is difficult or other people oppose it.

Reading a book about swimming cannot guarantee the ability to swim. Likewise, there is no royal road to writing papers. However, it would be helpful to the surgeon to remember Dr. Murray’s 3 words: curiosity, imagination, and persistence.

Reference

1. Neill US. Publish or perish, but at what cost? *J Clin Invest* 2008;118:2368.

Sural Intra-neural Ganglion Cysts Are Joint-related

Robert J. Spinner^{1,2}, Kimberly K. Amrami^{1,3}, Mohanad Ahmed Ibrahim Elshiekh¹, Neal M. Blitz⁴

Departments of ¹Neurologic Surgery, ²Orthopedics, and ³Radiology, Mayo Clinic, Rochester; ⁴Department of Orthopedic Surgery, Bronx-Lebanon Hospital Center, Bronx, USA

Correspondence: Robert J. Spinner
Departments of Neurologic Surgery, Orthopedics, Mayo Clinic, Gonda 8-214 South, Rochester, MN 55905, USA
Tel: +1-507-284-2376, Fax: +1-507-284-5206, E-mail: spinner.robert@mayo.edu

No potential conflict of interest relevant to this article was reported.

Received: 8 Nov 2011 • Revised: 15 Dec 2011 • Accepted: 28 Dec 2011
pISSN: 2234-6163 • eISSN: 2234-6171
<http://dx.doi.org/10.5999/aps.2012.39.1.77B> • Arch Plast Surg 2012;39:77-79

Copyright © 2012 The Korean Society of Plastic and Reconstructive Surgeons
This is an Open Access article distributed under the terms of the Creative Commons Attribution Non-Commercial License (<http://creativecommons.org/licenses/by-nc/3.0/>) which permits unrestricted non-commercial use, distribution, and reproduction in any medium, provided the original work is properly cited.

The recent article by Kim and Kim [1] provides a valuable case of a rare sural intra-neural ganglion cyst to the literature. We offer yet another example to highlight recent developments in our understanding of this entity.

A 42-year-old woman presented with a 6 month history of the spontaneous onset of moderately severe pain developing in the right lateral rearfoot in the retrolateral malleolar region with radiating dysesthesias into the dorsolateral foot. Symptoms were worse with standing or with activity. Exam revealed a 3 × 2 cm soft tissue tubular mass along the course of the sural nerve which had features consistent with a ganglion cyst. It was tender to palpation. Percussion produced radiating paresthesias in the sural nerve distribution. Sensation was intact on the dorsal foot to light touch. Magnetic resonance imaging (MRI) demonstrated a sural intra-neural ganglion cyst with a joint connection to the subtalar joint (Figs. 1, 2). At operation, this articular branch connection was identified, ligated and resected. The patient had full recovery immediately postoperatively; there was no clinical evidence of persistent pain or cyst at last follow-up examination.

As Kim and Kim [1] point out, the pathogenesis of these cysts has been controversial and poorly understood. Recent reports have clarified this. Layers of robust evidence have substantiated an articular origin for all types of intra-neural cysts first at the prototypic site (the common fibular nerve) and then at other joints throughout the appendicular skeleton and axial spine [2,3]. The unifying articular (synovial) theory has been shown to be generalizable and universal. Joint connections must be assumed to be present. We have emphasized the difficulties in identifying the joint connection with imaging and at operation. Experience with both can reliably and reproducibly identify the joint connection. High resolution imaging (MRI or computed tomography imaging with or without arthrography;

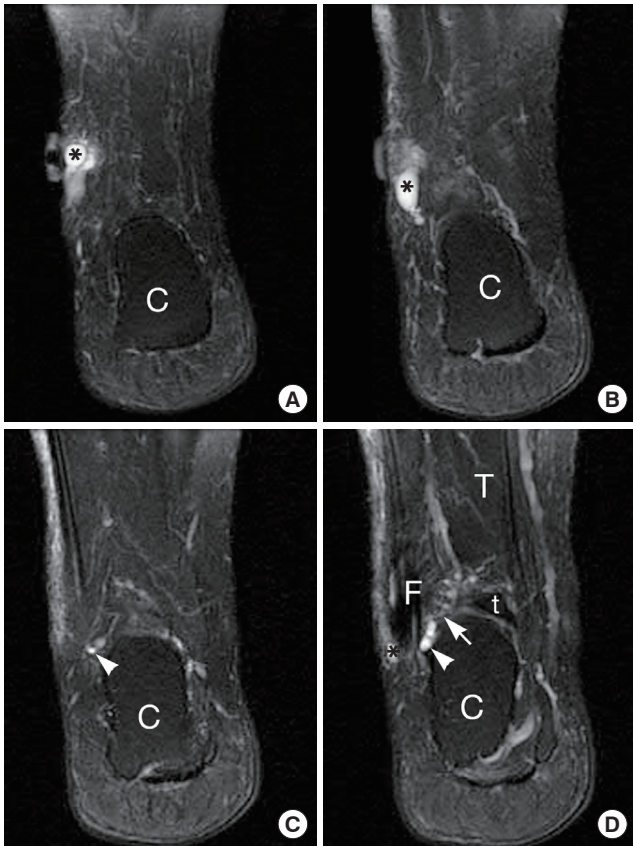


Fig. 1.

Conventional MRI of a patient with sural intraneural ganglion originating from subtalar joint. Serial coronal T2-weighted fast spin echo (FSE) images with fat suppression from posterior to anterior demonstrates an intraneural cyst arising from the lateral aspect of the subtalar joint. The cutaneous marker directs attention to the dominant portion of the cyst (asterisk, seen on [A], [B] and [D]) but the narrow tail of the cyst and its joint connection are not seen on these images (4 mm thick with 5 mm interslice gap) and could easily be missed without close inspection of serial images. Image (C) shows a portion of the cyst (white arrowhead, seen on [C] and [D]) but viewed individually does not show either the main portion of the cyst or its origin. The narrow joint connection is best seen on figure (D) (white arrow) but visualizing the complete course of the cyst on this sequence requires four contiguous images. Available imaging in the other planes (sagittal and axial) in this case similarly requires tracking along several images to connect the dominant portion of the cyst to its origin from the joint (not shown). C, calcaneus; F, fibular; T, tibia; t, talus.

or ultrasound) with conventional or 3-dimensional renderings may show convincingly a seemingly occult joint connection [3,4], even when reported by others not to be present. The consistent articular connection has fostered an understanding of the principles of these cysts. A capsular defect allows the passage of joint fluid to pass from the joint (often degenerative) along an articular branch and into the parent nerve. Propagation follows the path of least resistance within the epineurium of nerve. Intra-articular pressure and pressure fluxes influence cyst dimensions.

We have identified 9 cases of sural intraneural ganglia (Appendix).

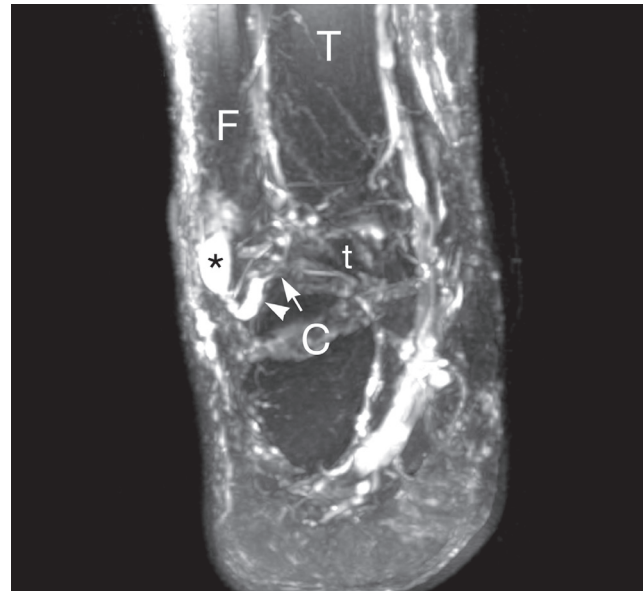


Fig. 2.

Three-dimensional rendering of conventional magnetic resonance images obtained in this patient with a sural intraneural ganglion cyst. Maximum intensity projection image created from the same series as Fig. 1 shows the entire course of the cyst (asterisk) and well demonstrates the recurrent course of the cyst (white arrowhead) and its origin from the subtalar joint (white arrow) in a single image. C, calcaneus; F, fibular; T, tibia; t, talus.

Of these, joint connections were only found in 3 instances: twice to the subtalar joint and once to the calcaneocuboid joint. Nevertheless, we are confident that joint connections were present in all of the remaining cases in the literature, including the one by Kim and Kim [1]. These joint connections can be predicted and must be anticipated. The articular branch anatomy of the sural nerve [5] would explain all of the locations of these cysts (Fig. 3). The unifying articular theory could explain all of their patterns of propagation [2,3].

Understanding the pathogenesis can help target surgery so as to simplify it. Surgery should include ligating or resecting the articular branch near the joint. The cyst itself need not be resected as it will be resorbed as long as the connection is disrupted. This approach minimizes intraneural dissection and eliminates intraneural recurrence, which is known to occur with high rates and was documented in several of these sural examples (Appendix). We believe that such recurrence would likely have been present in other patients (even those who were asymptomatic) if postoperative imaging had been performed. Resecting the nerve, while possible in the case of a distal cutaneous nerve (such as the sural nerve) and has been performed in several cases, could still result in intraneural (distal) recurrence. Furthermore, nerve sacrifice can not be extrapolated to other cases of intraneural ganglia involving major mixed peripheral nerves.

Knowledge of current pathogenesis and experience with the imaging and operative findings with these rare cysts will improve outcomes and eliminate intraneural recurrences.

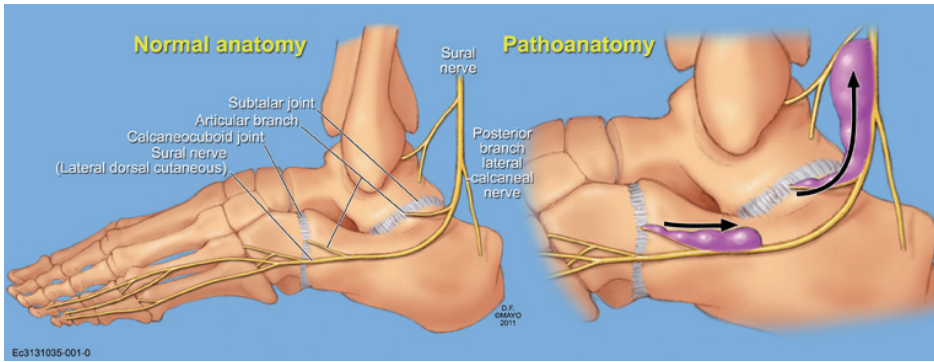


Fig. 3

The anatomy and pathoanatomy of known and potential sites of sural intraneural ganglion cysts. The drawing of the normal anatomy was based on descriptions by anatomists [5]. The confirmed joint-related sites of origin (subtalar and calcaneocuboid joints) are depicted. Other sites can be predicted based on the articular branch anatomy (with permission, Mayo Foundation, 2011).

Acknowledgments

The authors appreciate the assistance of David T. Wong, DPM, AAP-WCA, Attending Foot Surgery, Department of Orthopaedics, Bronx Lebanon Hospital Center.

References

1. Kim CH, Kim HS. Epineural ganglion cyst of the sural nerve at the foot: a case report. *J Korean Soc Plast Reconstr Surg* 2010;37:839-42.
2. Spinner RJ, Atkinson JL, Tiel RL. Peroneal intraneural ganglia: the importance of the articular branch: a unifying theory. *J Neurosurg* 2003;99:330-43.
3. Spinner RJ, Scheithauer BW, Amrami KK. The unifying articular (synovial) origin of intraneural ganglia: evolution-revelation-revolution. *Neurosurgery* 2009;65:A115-24.
4. Shahid KR, Spinner RJ, Skinner JA, et al. Evaluation of intraneural ganglion cysts using three-dimensional fast spin echo-cube. *J Magn Reson Imaging* 2010;32:714-8.
5. Sarrafian SK. *Anatomy of the foot and ankle: descriptive, topographic, functional*. 2nd ed. Philadelphia: Lippincott Williams and Wilkins; 1993.

Appendix. Sural intraneural ganglia					
Nerve	Joint connection	Joint involved	Recurrence	Age (yr) mean (range)	Gender
Sural: n=9	n=3 (c, g, h)	Subtalar: n=2 (g, h) Calcaneocuboid: n=1 (c)	n=3 (f, g, h)	46 (22-61)	6 women & 3 men
<ol style="list-style-type: none"> a. Kim CH, Kim HS. Epineural ganglion cyst of the sural nerve at the foot: a case report. <i>J Korean Soc Plast Reconstr Surg</i> 2010;37:839-42. b. Sato M, Ando T. Three cases of neural ganglions. <i>J Jap Surg Soc</i> 1967; 70:906. c. Pringle RM, Protheroe K, Mukherjee SK. Entrapment neuropathy of the sural nerve. <i>J Bone Joint Surg Br</i> 1974;56:465-8. d. Herrin E, Lepow GM, Bruyn JM. Mucinous cyst of the sural nerve. <i>J Foot Surg</i> 1986;25:14-8. e. Høgh J. Benign cystic lesions of peripheral nerves. <i>Int Orthop</i> 1988; 12:269-71. f. Acciarri N, Giuliani G, Poppi M, et al. Sural neuropathy produced by intraneural ganglion. <i>J Foot Surg</i> 1990;29:231-2. g. Araki N, Omakawa S, Matsuda T, et al. Intraneural cyst in the foot; report of three cases. <i>Orthopedics</i> 2009;60:353-5. h. Blitz NM, Prestridge J, Amrami KK, et al. A posttraumatic, joint-connected sural intraneural ganglion cyst-with a new mechanism of intraneural recurrence: a case report. <i>J Foot Ankle Surg</i> 2008;47:199-205. 					