

# Usefulness of Gold Thread Implantation for Crow's Feet

Kee Cheol Shin, Tae Hui Bae, Woo Seob Kim, Han Koo Kim

Department of Plastic and Reconstructive Surgery, Chung-Ang University Hospital, Chung-Ang University College of Medicine, Seoul, Korea

Original Article

**Background** Conservative techniques designed to block or delay the aging process have been utilized in various ways for many years. However, their effects can be relatively minimal and short-term in most cases compared to surgery. The objective of this study was to evaluate the efficacy and safety of gold thread implantation for the treatment of periorbital wrinkles.

**Methods** A total of 78 consecutive patients who showed mild to severe periorbital wrinkles were deemed appropriate candidates, including 69 women and 9 men ranging from 31 to 59 years (mean, 47 years). Six gold threads about 4 cm in length were inserted subdermally in each patient at intervals of about 0.5 cm. Follow-up assessments were performed 1, 4, and 12 weeks after the procedure. The efficacy was rated by the physician using the Wrinkle Severity Rating Scale and patients who made global assessments of changes in periorbital wrinkles using the Visual Analog Scale. Adverse events were monitored throughout the course of the study.

**Results** The patients showed significant improvements after the procedure. There were minor complications such as foreign body sensation in the eye (2.63%) and eye pain (1.32%) that improved spontaneously without any specific treatments.

**Conclusions** Subdermal implantation of gold thread improves the appearance of periorbital wrinkles and does not appear to have serious side effects. Insertion of gold thread may be an effective and safe method for facial rejuvenation.

**Keywords** Gold / Rejuvenation / Aging

**Correspondence:** Tae Hui Bae  
Department of Plastic and Reconstructive Surgery, Chung-Ang University Hospital, Chung-Ang University College of Medicine, 102 Heukseok-ro, Dongjak-gu, Seoul 156-755, Korea  
Tel: +82-2-26299-1615  
Fax: +82-2-825-9880  
E-mail: psbth@cau.ac.kr

No potential conflict of interest relevant to this article was reported.

Received: 19 Aug 2011 • Revised: 7 Sep 2011 • Accepted: 15 Sep 2011

pISSN: 2234-6163 • eISSN: 2234-6171 • <http://dx.doi.org/10.5999/aps.2012.39.1.42> • Arch Plast Surg 2012;39:42-45

## INTRODUCTION

Wrinkles are some of the Wrinkles first signs of the aging process. Wrinkles occur through elastosis in the dermis, which is associated with external and internal factors such as ultraviolet light, excessive massage, and body mass changes. Periorbital wrinkles, or crow's feet, are among the earliest aging phenomena because the periorbital skin is thin and the area has abundant expression muscles. Various surgical procedures and nonsurgical methods have been developed to correct crow's feet. However,

the temporal branch of the facial nerve can be damaged during surgical procedures, and only temporary effects are expected after nonsurgical treatments. The objective of this study was to evaluate the efficacy and safety of gold thread implantation for the treatment of periorbital wrinkles.

## METHODS

This clinical trial was approved by the Korean Food and Drug Administration (09-998) and the Institutional Review Board of

Chung-Ang University Hospital (GP-0452).

A total of 78 consecutive patients including 69 women and 9 men ranging from 31 to 59 years of age (mean, 47 years) with mild to severe periorbital wrinkles (score greater than 2) were deemed to be suitable candidates for inclusion in the study (Table 1) [1].

The implant material was 0.1 mm diameter gold thread braided with a strand of absorbable polyglycolic acid and fixed to a 60 mm length atraumatic cutting needle. After sterilization of both periorbital areas with design, 1:100,000 epinephrine mixed with 2% lidocaine was infiltrated at least 1 cm away from the lateral orbital rim. Six gold threads about 4 cm in length were inserted subdermally at intervals of about 0.5 cm, with 3 lines in the direction from the lateral eyebrow to the ear and 3 lines in the direction from the temple to the nose (Fig. 1). The small needle puncture wounds healed well without scarring and were treated with simple dressings.

Follow-up assessments were performed at 1, 4, and 12 weeks after the procedure. Efficacy was assessed by two independent plastic surgeons using posttreatment photographs according to the Wrinkle Severity Rating Scale (WSRS), and also by patients who made global assessment of changes in their periorbital wrinkles according to the Visual Analog Scale (VAS) (Fig. 2). Adverse events were monitored throughout the course of the study.

## RESULTS

Patients experienced significant improvements in periorbital wrinkles (Figs. 3, 4). The WSRS score, with a possible range of 0 to 5, was  $3.21 \pm 0.66$  at baseline and was  $2.41 \pm 0.57$  at post-treatment 12 weeks later. The average change in WSRS was  $-0.80 \pm 0.48$ , which was statistically significant ( $P < 0.0001$ , Wilcoxon signed rank test). The WSRS scores of 61 patients (80.26%; 95% confidence interval, 71.31% to 89.21%) decreased by more than 1 point at 12 weeks after the procedure.

The VAS at baseline was  $69.61 \pm 15.87$  and was  $28.09 \pm 15.03$  at posttreatment 12 weeks later. The average change in the VAS score 12 weeks after treatment was  $-41.5 \pm 16.59$ , which was

Fig. 1. Schematic procedure line

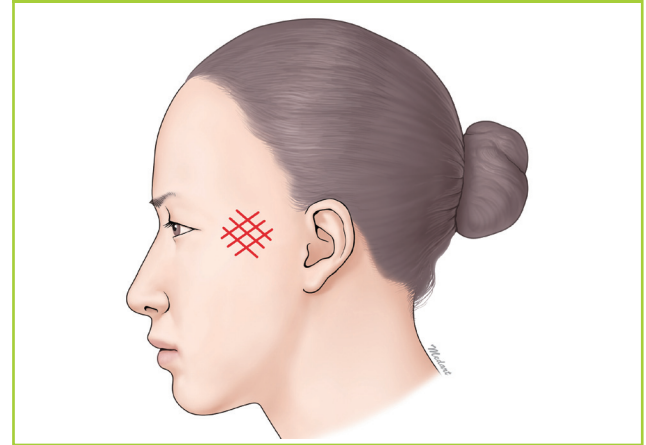


Table 1. Wrinkle severity rating scale	
Score	Description
5	Extreme: extremely deep and long folds, detrimental to facial appearance; 2- to 4-mm visible V-shaped fold when stretched; unlikely to have satisfactory correction with injectable implant alone
4	Severe: very long and deep folds; prominent facial feature; less than 2-mm visible fold when stretched; significant improvement is expected from injectable implant
3	Moderate: moderately deep folds; clear facial feature visible at normal appearance but not when stretched; excellent correction is expected from injectable implant
2	Mild: shallow but visible fold with a slight indentation; minor facial feature; implant is expected to produce a slight improvement in appearance
1	Absent: no visible fold; continuous skin line

From Day DJ, et al. Am J Clin Dermatol 2004;5:49-52, with permission Adis Data Information BV [1].

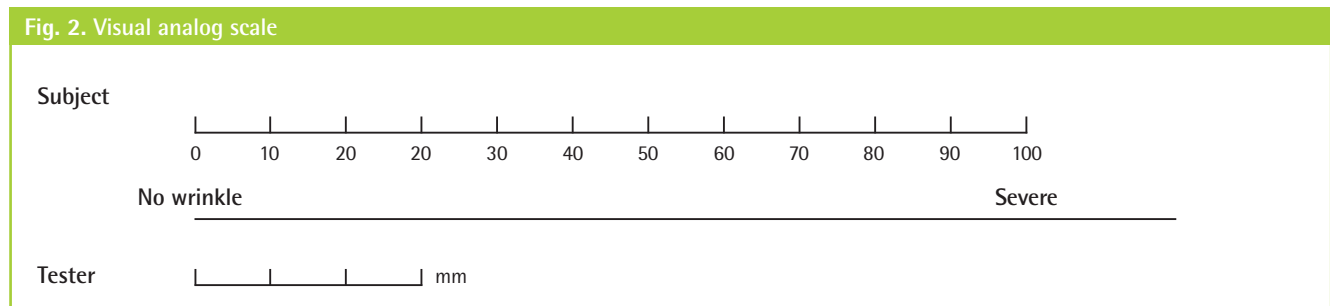


Fig. 3. Case

(A) Preoperative view of a 52-year-old male. (B) The patient 12 weeks postprocedure.

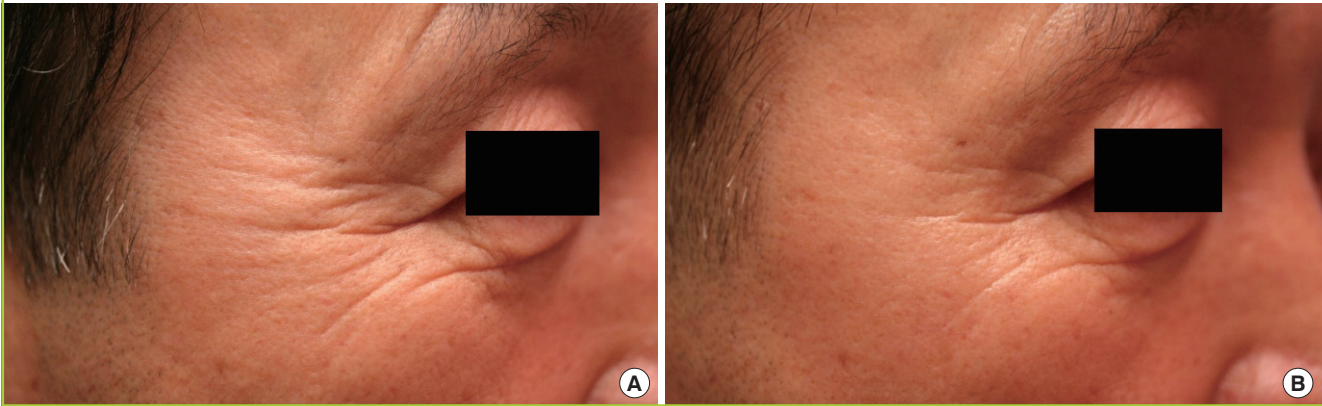
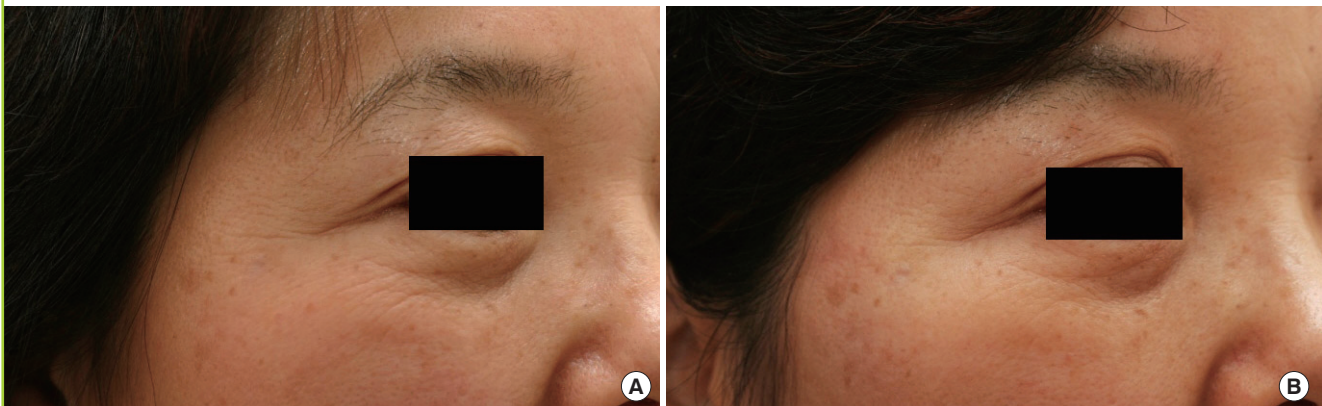


Fig. 4. Case

(A) Preoperative view of a 53-year-old female. (B) The patient 12 weeks postprocedure.



statistically significant ( $P < 0.0001$ , Wilcoxon signed rank test). Minor complications included foreign body sensation in the eye (2.63%) and eye pain (1.32%), which improved spontaneously without any specific treatments.

## DISCUSSION

Various methods have been developed for wrinkle removal and rejuvenation, from surgical approaches such as facelifts to non-surgical methods such as botulinum toxin, laser, peeling, fillers, and cosmetics [2-4]. Botulinum toxin is effective for the treatment of facial wrinkles caused by the action of facial muscles, and has the advantage of minimal side effects compared to surgical approaches. However, repeated injections are required, and even repeated administrations of botulinum toxin cannot improve all wrinkles. Lasers are effective for fine wrinkle elimination and improvement of skin elasticity due to increased elastic fibers and collagen in the dermis. However, laser treatment is expensive and can lead to complications such as thermal injury

and pigmentation. Peels can yield effective cosmetic results in combination with chemical formulas or machines, as in chemical peeling and dermabrasion. Chemical peels are better than other short term treatments for relatively large areas and are atraumatic compared to laser or dermabrasion. However, peels can produce inconsistent results due to concentration differences, uncertainty of penetration depth, and differences in the techniques of practitioners. Long term use of medications like retinoids are effective for improvements in wrinkles and increasing collagen in the dermis. However, it is unclear whether exclusive use is sufficient, as topical agents may only play a supportive role to the above procedures.

Ideal implants should have the following characteristics: resistance against physical force, chemical inertness, and biologic fitness. They must be non-allergenic, non-immunogenic, non-carcinogenic, and non-inflammatory. Metals, ceramics, and polymers have been used as implants in humans. Gold is stable, easy to process, and induces no adverse reactions such as inflammatory processes, infections, or allergic or immunological

reactions. Therefore, it has been used in dental implants, gold lid load (gold weight implants) to treat lagophthalmos of facial nerve palsy, as additives for alcohol and food as decoration, and recently as additives in cosmetics [5].

The use of gold thread in dermatology was first introduced by Dr. Caux in France about 30 years ago. Adamyan and colleagues identified pathological changes after experiments using subdermal gold thread insertion, including collagen production in the capsule formed by subdermal implantation of gold thread [6]. Gold thread implantation promotes angiogenesis, as the immediate area surrounding the capsule is rich in blood vessels compared with other regions, and the number of mast cells around gold thread increases over time. Therefore, we sought to investigate the cosmetic effects of subdermal capsular collagen formation by gold thread implantation.

Gold thread implantation is a treatment and prophylaxis procedure intended to improve the skin structure and to slow the aging process, achieving fine wrinkle elimination, smoothing of deep wrinkles, improvement of skin elasticity, and skin reinforcement. This clinical trial had limitations including a small study sample, lack of a control group, and a short follow-up period. Therefore, it remains to be seen whether the effects were temporary or shorter than those of nonsurgical methods.

Despite these limitations, we demonstrated that subdermal

implantation of gold thread improved periorbital wrinkles and did not appear to have serious side effects. Therefore, gold thread implantation may be an effective and safe alternative method for facial rejuvenation.

## REFERENCES

1. Day DJ, Littler CM, Swift RW, et al. The wrinkle severity rating scale: a validation study. *Am J Clin Dermatol* 2004;5:49-52.
2. Barton FE. Facial rejuvenation techniques. *Mund Kiefer Gesichtschir* 1997;1:328-34.
3. Fagien S. Botox for the treatment of dynamic and hyperkinetic facial lines and furrows: adjunctive use in facial aesthetic surgery. *Plast Reconstr Surg* 1999;103:701-13.
4. Fagien S, Carruthers JD. A comprehensive review of patient-reported satisfaction with botulinum toxin type a for aesthetic procedures. *Plast Reconstr Surg* 2008;122:1915-25.
5. Choo PH, Carter SR, Seiff SR. Upper eyelid gold weight implantation in the Asian patient with facial paralysis. *Plast Reconstr Surg* 2000;105:855-9.
6. Rondo Junior W, Vidarte G, Michalany N. Histologic study of the skin with gold thread implantation. *Plast Reconstr Surg* 1996;97:256-8.