

Case Report

Discordant findings of different positron emission tomography/CT tracers in a case of glioblastoma

ABSTRACT

^{18}F -2-fluoro-2-deoxy-D-glucose (^{18}F -FDG) positron emission tomography (PET) CT has proven useful in the evaluation of high-grade glioma and is also useful as a predictor of the degree of malignancy in newly diagnosed brain tumors. It is commonly accepted that high-grade gliomas are characterized by increased FDG uptake, whereas the low-grade glioma demonstrates reduced or absent FDG uptake. ^{18}F -FDOPA is an amino acid PET tracer which is a marker of the proliferative activity of brain tumors and demonstrates positive uptake in all grades of brain tumors; however, the degree of tracer uptake is significantly higher in high-grade tumors as compared to low-grade tumors. Here, we discuss a case where both FDG and DOPA PET/CT scans raised suspicion of low-grade glioma; however, the final histopathology report confirmed WHO grade IV Glioblastoma.

Keywords: ^{18}F -DOPA, ^{18}F -2-fluoro-2-deoxy-D-glucose, dual tracer positron emission tomography, false-negative positron emission tomography/CT, high-grade glioblastoma

INTRODUCTION

Glioblastoma accounts for a majority of malignant gliomas, and it is the most common malignant brain tumor. Magnetic resonance imaging (MRI), considered as gold standard in neuroimaging, offers limited options in delineation between high- and low-grade tumors. ^{18}F -2-fluoro-2-deoxy-D-glucose (^{18}F -FDG) positron emission tomography (PET) CT, a nonspecific radiotracer used for noninvasively assessing the biological aggressiveness of tumors, is limited in the detectability of tumors with only modest increases in glucose metabolism, such as low-grade and recurrent tumors due to the high physiologic rate of metabolism of glucose by normal brain tissue. Due to the relatively low tracer uptake in normal gray matter, amino acid PET tracers such as ^{18}F -FDOPA can detect gliomas with greater sensitivity than ^{18}F -FDG in primary and recurrent tumors. The degree of ^{18}F -FDOPA tracer uptake is significantly higher in high-grade tumors as compared to low-grade tumors. Scans with both the tracers ^{18}F -FDG and ^{18}F -DOPA have proven useful in the evaluation of newly diagnosed and recurrent brain tumors, both in characterization as well as a predictor

of the degree of malignancy. Here, we present a rare case of atypical imaging findings in a patient with high-grade glioma. MRI along with ^{18}F -FDG and ^{18}F -DOPA PET CT scans was suggestive of low-grade glioma; however, on histopathology and immunohistochemistry, the lesion turned out to be WHO grade IV glioblastoma.

RAM ELUMALAI KUMAR, NITIN GUPTA, RAJEEV RANJAN¹, RITU VERMA, ETHEL SHANGNE BELHO, ISHITA BARAT SEN²

Department of Nuclear Medicine and PET/CT, Mahajan Imaging Centre, Sir Ganga Ram Hospital, ¹Department of Neurology, Sir Ganga Ram Hospital, New Delhi, ²Department of Nuclear Medicine and PET/CT, Fortis Memorial Research Institute, Gurugram, Haryana, India


Address for correspondence: Dr. Nitin Gupta, Department of Nuclear Medicine and PET/CT, Mahajan Imaging Centre, Sir Ganga Ram Hospital, New Delhi - 110 060, India. E-mail: drnitingpt@gmail.com

Submitted: 12-Oct-2020, **Revised:** 28-Nov-2020,
Accepted: 07-May-2021, **Published:** 01-Nov-2021

This is an open access journal, and articles are distributed under the terms of the Creative Commons Attribution-NonCommercial-ShareAlike 4.0 License, which allows others to remix, tweak, and build upon the work non-commercially, as long as appropriate credit is given and the new creations are licensed under the identical terms.

For reprints contact: WKHLRPMedknow_reprints@wolterskluwer.com

How to cite this article: Kumar RE, Gupta N, Ranjan R, Verma R, Belho ES, Sen IB. Discordant findings of different positron emission tomography/CT tracers in a case of glioblastoma. World J Nucl Med 2021;20:401-4.

Access this article online	
Website: www.wjnm.org	Quick Response Code 
DOI: 10.4103/wjnm.wjnm_135_20	

CASE REPORT

A 29-year-old right-handed female presented with new-onset right-sided focal seizures with secondary generalization. She had no associated comorbidities and was treated with antiepileptic drugs. Initial plain MRI evaluation revealed a well-defined rounded lesion in the left parietal lobe of the brain. Her systemic survey was negative for granulomatous disease. She was further worked up with contrast-enhanced MRI [Figure 1a-c], MR spectroscopy (MRS), and MR venography, which revealed a peripherally enhancing cystic lesion in the left parietal lobe with absent choline peak, normal NAA, and dominant lactate peak. A possible diagnosis of neurocysticercosis was considered. At this point, no active intervention was done and she was kept on close follow-up. Despite taking two antiepileptic drugs in adequate dosage, she developed recurrent sensory phenomenon involving right lower limb, lower trunk, and perineal region with occasional involvement of the right upper limb. In view of the aforementioned symptoms, she was advised for different PET/CT tracers [^{18}F]-FDOPA PET CT and [^{18}F]-FDG PET CT of the brain for further evaluation.

The axial CT and fused [^{18}F]-FDOPA PET/CT and [^{18}F]-FDG PET/CT scan findings revealed a large, non- ^{18}F -FDG [Figure 1d-f] and peripherally [^{18}F]-DOPA avid [Figure 1g-i], peripherally enhancing cystic lesion in the left high parietal lobe, with irregularly thickened hyperdense margins and perilesional edema. The lesion demonstrated washout of [^{18}F]-DOPA on delayed images acquired at 45 min after the initial scan. In view of absent [^{18}F]-FDG uptake and moderate [^{18}F]-DOPA uptake, the possibility of low-grade glioma was considered and histopathological correlation was advised. The patient continued to worsen clinically, and a decision to surgically remove the lesion was taken. Before the surgery, the [^{18}F]-FDG scan [Figure 1j-l] was repeated at a separate institute after 15 days which showed a similar picture. She tolerated the procedure fairly well and her postoperative course was uneventful. Final histopathology and immunohistochemistry report [Figure 2a-d] revealed a glial tumor with high cellularity with foci of tumor necrosis and endothelial proliferation and over expression of p53, GFAP, vimentin, and IDH-1 with Ki67 index $\sim 20\%$ and negative for EMA and synaptophysin, suggestive of IDH-1 wild-type WHO grade IV glioblastoma.

DISCUSSION

Glioma is the most common malignant brain tumor with an average incidence rate of 6.0 per 100,000 population in the United States.^[1] Low-grade glioma generally occurs in relatively younger age group, having an indolent clinical course

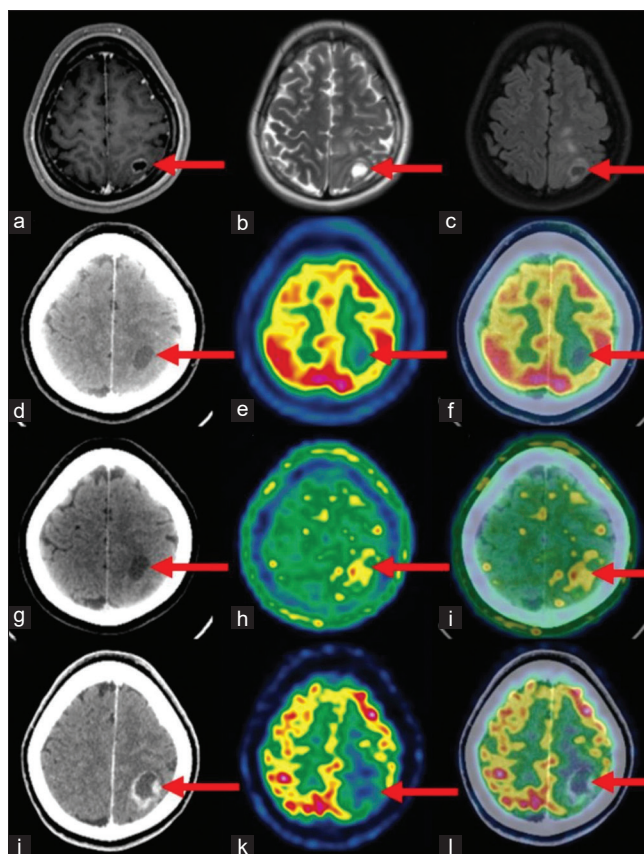


Figure 1: (a-c) Images showing hypointense lesion (red arrow) with peripheral enhancement on T1-weighted images, hyperintense lesion (red arrow) on T2-weighted images, and peripheral enhancement (red arrow) on T1RM images. (d-i) Images showing peripherally enhancing cystic lesion (red arrow) in left high parietal lobe with absent ^{18}F -2-fluoro-2-deoxy-D-glucose uptake and mild peripheral [^{18}F]-DOPA uptake. (j-l) ^{18}F -2-fluoro-2-deoxy-D-glucose positron emission tomography/CT repeated in another institute, images show peripherally enhancing cystic lesion (red arrow) in left high parietal lobe with absent ^{18}F -2-fluoro-2-deoxy-D-glucose uptake

with better prognosis and long-term survival. Glioblastoma, which accounts for nearly 60%–70% of malignant glioma, carries a poor prognosis despite aggressive multimodality therapeutic options; thus, early diagnosis is important for better patient outcome.^[1]

Multiple imaging modalities such as MRI, MRS, and positron emission tomography are used in evaluation of glioma. Conventional MRI gives important information about the contrast material enhancement, perienhancement edema, hemorrhage, necrosis, mass effect, which helps clinicians about tumor aggressiveness and hence tumor grade.^[2] However, often a high-grade glioma may be mistaken for a low-grade glioma when it demonstrates minimal edema, no contrast material enhancement, no necrosis, and no mass effect.^[2] MRI of our patient revealed mild peripheral enhancement of a hypointense lesion on T1 sequence and hyperintense lesion on T2 sequence, thus reducing the probability of a high-grade glioma on MRI. High-grade

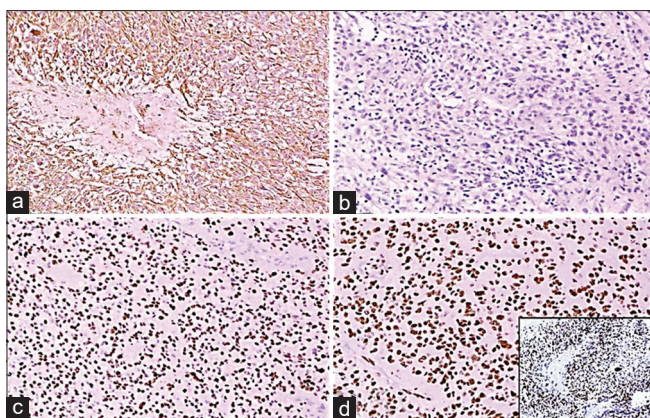


Figure 2: (a) GFAP-positive tumor cells (IHC, $\times 200$). (b) Immunohistochemistry for IDH-1R132 mutation is negative. (c) Immunohistochemistry for ATRX showing retained expression. (d) Immunohistochemistry for P53 showing over expression (positive for mutation), inset image showing high Ki67 proliferative index

gliomas typically exhibit elevated choline, elevated lactate and decreased NAA on MRS.^[3] Acute demyelinating lesions and high-grade brain tumors are difficult to distinguish on MRS, as both usually present with elevated choline, decreased NAA, and increased lactate peak.^[3] Our patient's MRS showed absent choline peak, normal NAA, and dominant lactate peak, supporting low-grade pathology. PET using radioactively labeled glucose and amino acids has increased utility in diagnosis, therapy planning, and therapeutic response assessment of malignant brain tumors.^[4] Among PET radiotracers, [^{18}F]-FDG is the most commonly used tracer.^[4] It is widely believed that high-grade glioma shows increased [^{18}F]-FDG uptake and low-grade glioma shows reduced or absent [^{18}F]-FDG uptake.^[4] This property has been tapped to diagnose malignant transformation of low-grade glioma into high-grade glioma, to guide biopsies, to assess posttreatment response, and to detect early tumor relapse compared to radio necrosis.^[4] However, a high physiological [^{18}F]-FDG uptake in the surrounding normal brain tissue limits its use for the diagnosis of all grades of cerebral glioma, which may not be visualized in a large fraction of low-grade primary and recurrent tumors. In acknowledgement of the variability of [^{18}F]-FDG uptake in brain tumors, our patient underwent [^{18}F]-FDG brain PET twice, the second time at a separate institute; however, the results were the same, thus establishing absent [^{18}F]-FDG uptake in the lesion. Few case reports of high-grade glioblastoma showing low [^{18}F]-FDG uptake were reported in the literature.^[5-7] Padma *et al.* in their series reported low [^{18}F]-FDG uptake in 15% of high-grade glioma and attributed low uptake to intense necrosis in the high-grade tumors as well in association with prior intervention or chemotherapy.^[5] Since there was no history of any prior intervention and also the lesion did not demonstrate any

significant degree of necrosis on the corresponding CT/MRI, the tumor hypometabolism seen in our patient cannot be explained on these grounds.

Due to the relatively low tracer uptake in normal gray matter, amino acid PET tracers such as [^{18}F]-DOPA can detect glioma with greater sensitivity than [^{18}F]-FDG in primary and recurrent tumors and are helpful in differentiating recurrent tumors from treatment-induced changes.^[8] [^{18}F]-DOPA uptake is usually significantly higher in high-grade tumors as compared to low-grade newly diagnosed tumors.^[8] Another factor which supports high-grade glioma is persistent tracer uptake in the delayed images. Our patient showed low to moderate tracer uptake in the initial scan with washout in the delayed images, prompting us to believe the lesion as a low-grade tumor. The incorporation of molecular markers along with histological features in latest (2016) guidelines for WHO grading of brain tumors helped us in this case, as the lesion was highly cellular with foci of tumor necrosis and endothelial proliferation with over expression of p53, GFAP, vimentin, IDH-1 on immunohistochemistry with Ki67 index $\sim 20\%$ and negative for EMA and synaptophysin, suggestive of IDH-1 wild-type WHO grade IV glioblastoma.^[9]

CONCLUSION

We hereby conclude that high-grade glioma represents a heterogeneous subgroup of primary malignant brain tumors which may have atypical imaging findings. The most important factor is the clinical course of the disease. Any rapid worsening or new symptom, despite optimal medical management, should be considered a red flag and further treatment planned accordingly.

Declaration of patient consent

The authors certify that they have obtained all appropriate patient consent forms. In the form the patient(s) has/have given his/her/their consent for his/her/their images and other clinical information to be reported in the journal. The patients understand that their names and initials will not be published and due efforts will be made to conceal their identity, but anonymity cannot be guaranteed.

Financial support and sponsorship

Nil.

Conflicts of interest

There are no conflicts of interest.

REFERENCES

- Ostrom QT, Gittleman H, Liao P, Vecchione-Koval T, Wolinsky Y,

- Kruchko C, *et al.* CBTRUS Statistical Report: Primary brain and other central nervous system tumors diagnosed in the United States in 2010-2014. *Neuro Oncol* 2017;19:v1-88.
2. Law M, Yang S, Wang H, Babb JS, Johnson G, Cha S, *et al.* Glioma grading: Sensitivity, specificity, and predictive values of perfusion MR imaging and proton MR spectroscopic imaging compared with conventional MR imaging. *AJNR Am J Neuroradiol* 2003;24:1989-98.
 3. Horská A, Barker PB. Imaging of brain tumors: MR spectroscopy and metabolic imaging. *Neuroimaging Clin N Am* 2010;20:293-310.
 4. Demetriades AK, Almeida AC, Bhangoo RS, Barrington SF. Applications of positron emission tomography in neuro-oncology: A clinical approach. *Surgeon* 2014;12:148-57.
 5. Padma MV, Said S, Jacobs M, Hwang DR, Dunigan K, Satter M, *et al.* Prediction of pathology and survival by FDG PET in gliomas. *J Neurooncol* 2003;64:227-37.
 6. Davis WK, Boyko OB, Hoffman JM, Hanson MW, Schold SC Jr., Burger PC, *et al.* [¹⁸F]2-fluoro-2-deoxy glucose positron emission tomography correlation of gadolinium-enhanced MR imaging of central nervous system neoplasia. *AJNR Am J Neuroradiol* 1993;14:515-23.
 7. Atkinson M, Juhász C, Shah J, Guo X, Kupsky W, Fuerst D, *et al.* Paradoxical imaging findings in cerebral gliomas. *J Neurol Sci* 2008;269:180-3.
 8. Fueger BJ, Czernin J, Cloughesy T, Silverman DH, Geist CL, Walter MA, *et al.* Correlation of 6-¹⁸F-fluoro-L-DOPA PET uptake with proliferation and tumor grade in newly diagnosed and recurrent gliomas. *J Nucl Med* 2010;51:1532-8.
 9. Gupta A, Dwivedi T. A simplified overview of World Health Organization Classification Update of central nervous system tumors 2016. *J Neurosci Rural Pract* 2017;8:629-41.