

Case Report

Reactive changes with microfilaria in a suspected metastatic axillary lymph node on positron emission tomography–computed tomography in breast malignancy: An interesting finding

ABSTRACT

Positron emission tomography–computed tomography (PET-CT) has evolved as an important diagnostic tool in the diagnosis and management of breast carcinoma. PET/CT can help in staging as well as detecting metastases to mediastinal, axillary, and internal mammary nodes. However, PET-CT is not useful in differentiating between inflammation and malignancy.

Keywords: Breast cancer, microfilaria, positron emission tomography–computed tomography

INTRODUCTION

The applications of 2-deoxy-2-[¹⁸F] fluoro-D-glucose positron emission tomography (PET) in the management of patients with breast cancer have been extensively studied. According to these studies, PET-computed tomography (PET/CT) is not routinely performed for the diagnosis of primary breast cancer, although PET/CT in specific subtypes of breast cancer correlates with histopathologic features of the primary tumor.^[1] In the detection of distant metastases, this imaging tool may have a better accuracy in detecting lytic bone metastases compared to bone scintigraphy. Thus, PET/CT is recommended when advanced-stage disease is suspected, and conventional modalities are inconclusive. Furthermore, PET/CT has a high sensitivity and specificity to detect locoregional recurrence and is recommended in asymptomatic patients with rising tumor markers. Axillary lymph node status is one of the main prognostic factors in breast cancer.^[2] PET-CT is a good investigational tool for detecting axillary lymph node involvement. Filariasis is a global social health problem of tropical and subtropical countries like India. *Wuchereria bancrofti* accounts for 95% of cases of lymphatic filariasis. *Microfilaria* in cytospreads is a rare finding.

CASE REPORT


We report the case of a 57-year-old female who presented with a right breast lump. PET-CT was done for initial evaluation along with other investigations. On PET-CT, there was a fluorodeoxyglucose (FDG)-avid soft-tissue lesion in the right breast ~2.5 cm × 1.5 cm in the upper quadrant of the breast with several FDG-avid right axillary lymph nodes with the largest measuring ~2.0 cm × 1.0 cm [Figures 1-5] in size. Histopathology from biopsy of the right breast lesion was suggestive of infiltrating ductal carcinoma; however, histopathology from fine-needle aspiration cytology right axillary lymph node showed reactive lymphoid hyperplasia

ANUJA ANAND, AARTI TYAGI¹, SHUBHAM JAIN², PANKAJ DOUGALL

Departments of Nuclear Medicine and PET-CT, ¹Pathology and ²Oncosurgery, Max Super Speciality Hospital, New Delhi, India

Address for correspondence: Dr. Anuja Anand, Department of Nuclear Medicine and PET-CT, Ground Floor, East Block, 2-Press Enclave Road, Max Super Speciality Hospital, New Delhi - 110 017, India.
E-mail: dr.anuja.anand@gmail.com

Submission: 02-Nov-18, **Accepted:** 20-Nov-18, **Published:** 07-Nov-2019

Access this article online	
Website: www.wjnm.org	Quick Response Code 
DOI: 10.4103/wjnm.WJNM_98_18	

This is an open access journal, and articles are distributed under the terms of the Creative Commons Attribution-NonCommercial-ShareAlike 4.0 License, which allows others to remix, tweak, and build upon the work non-commercially, as long as appropriate credit is given and the new creations are licensed under the identical terms.

For reprints contact: reprints@medknow.com

How to cite this article: Anand A, Tyagi A, Jain S, Dougall P. Reactive changes with microfilaria in a suspected metastatic axillary lymph node on positron emission tomography–computed tomography in breast malignancy: An interesting finding. *World J Nucl Med* 2020;19:171-3.

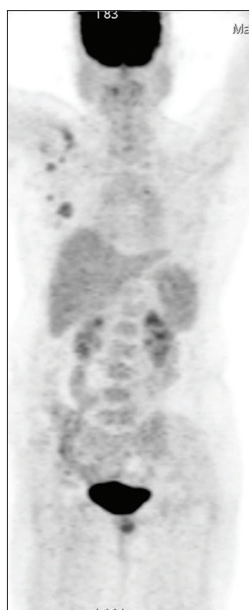

Figure 1: Fluorodeoxyglucose positron emission tomography-computed tomography Maximum Intensity Projection images show the right breast lesion and right axillary lymph nodes

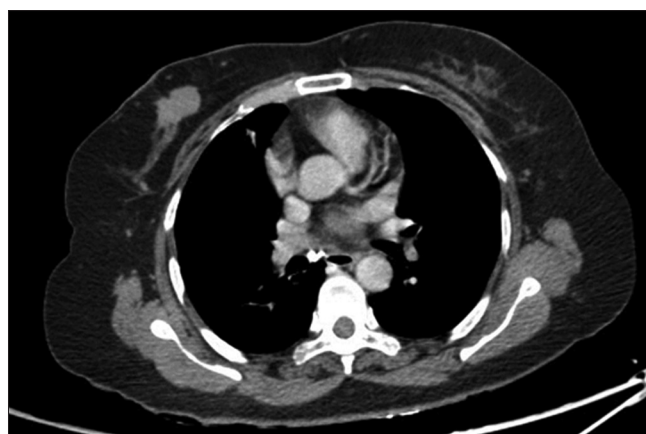

Figure 2: CT images show the right breast lesion

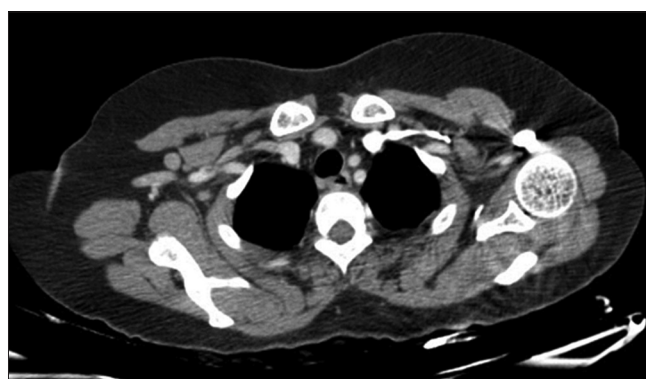


Figure 4: CT images show well-defined rounded right axillary lymph nodes

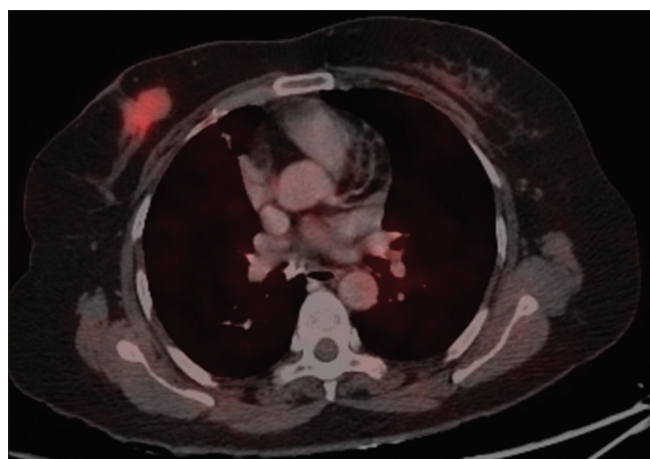


Figure 3: Right breast lesion with fluorodeoxyglucose uptake is appreciated

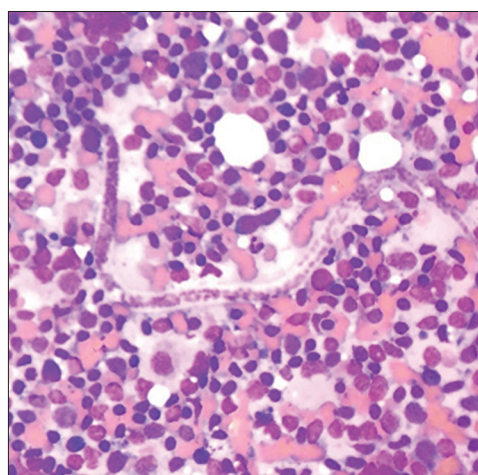


Figure 6: Fine-needle aspiration cytology showed reactive lymphoid hyperplasia with giant cell reaction and presence of microfilaria

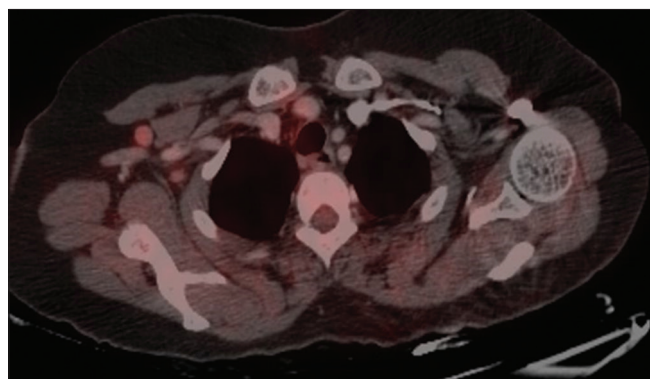


Figure 5: Fluorodeoxyglucose avid right axillary lymph nodes are seen

with giant cell reaction and presence of microfilaria [Figure 6]. Therefore, PET-CT was false-positive for axillary lymph node

metastasis; however, it is an interesting and rare finding in which the patient is a diagnosed case of carcinoma breast with filariasis of axillary lymph node.

DISCUSSION

The mechanism of FDG localization in infection is similar to that in cancer in that cells involved in infection and

inflammation, especially neutrophils and the monocyte/macrophage, are able to express high levels of glucose transporters, especially glucose transporter 1. The common indications of FDG PET/CT in infection and inflammation include the following in descending order of accuracy: sarcoidosis, osteomyelitis, spondylodiscitis, fever of unknown origin, vasculitis, diabetic foot, prosthesis (especially hip), and vascular grafts. Furthermore, it is also used for assessing the extent of fungal infection and evaluation of therapy in infectious or inflammatory diseases.^[3] There has not been much published work regarding the role of PET-CT in parasitic infection, though review of literature shows some role in the follow-up of patients with rare parasitic infection.^[4] Thus, this case represents a rare finding for filariasis of axillary lymph node positive on whole body PET-CT.

CONCLUSION

Microfilariae at the site of the axillary lymph nodes have been reported, but the coexistence along with breast primary is still rare and furthermore being FDG-avid on PET-CT is even rarer. The lesson learned from this case is that parasitic infection is also an important differential of infective/inflammatory condition in which FDG uptake can be demonstrated in patients with malignancy especially in endemic areas.

Declaration of patient consent

The authors certify that they have obtained all appropriate patient consent forms. In the form the patient(s) has/have given his/her/their consent for his/her/their images and other clinical information to be reported in the journal. The patients understand that their names and initials will not be published and due efforts will be made to conceal their identity, but anonymity cannot be guaranteed.

Financial support and sponsorship

Nil.

Conflicts of interest

There are no conflicts of interest.

REFERENCES

1. Paydary K, Seraj SM, Zadeh MZ, Emamzadehfard S, Shamchi SP, Gholami S, *et al.* The evolving role of FDG-PET/CT in the diagnosis, staging, and treatment of breast cancer. *Mol Imaging Biol* 2018;30:1536-632.
2. Soerjomataram I, Louwman MW, Ribot JG, Roukema JA, Coebergh JW. An overview of prognostic factors for long-term survivors of breast cancer. *Breast Cancer Res Treat* 2008;107:309-30.
3. Farghaly H, Nasr H, Al Qami A. Role of FDG PET/CT in infection and inflammation. *J Nucl Med* 2015;30:314-19.
4. Caoduro C, Porot C, Vuitton DA, Bresson-Hadni S, Grenouillet F, Richou C, *et al.* The role of delayed 18F-FDG PET imaging in the follow-up of patients with alveolar echinococcosis. *J Nucl Med* 2013;54:358-63.