

Case Report

Temporal muscle uptake causing an unusual focal artifact on three-dimensional stereotactic surface projections statistical maps of (¹⁸F) fluorodeoxyglucose brain positron emission tomography in a patient with Alzheimer's disease

ABSTRACT

(¹⁸F) fluorodeoxyglucose brain positron emission tomography and statistical mapping analysis, such as three-dimensional stereotactic surface projections, have been used widely for the evaluation of dementia patients. We present an unusual focal artifact on the statistical maps resulting from intense temporal muscle uptake in a patient with Alzheimer's disease. Various degrees of physiologic uptake can be seen in head and neck muscles. However, it is unusual to see a focal artifact on the statistical maps due to temporal muscle uptake. This case illustrates the importance of quality control of imaging processing when atypical findings are seen on statistical maps.

Keywords: (¹⁸F) fluorodeoxyglucose, physiologic, positron emission tomography, temporalis muscles, three-dimensional stereotactic surface projections

INTRODUCTION

Semi-quantitative method using three-dimensional stereotactic surface projection (3D-SSP) analyses incorporated with a visual assessment to improve diagnostic confidence and accuracy have been intensively validated in the diagnosis of neurological abnormalities including dementia using single-photon emission computed tomography (SPECT) and positron emission tomography (PET).^[1] Artifact caused by physiologic activity is unusual but might effect on interpretation of results. We report a case with focal artifact on statistical mapping of (¹⁸F) fluorodeoxyglucose ([¹⁸F] FDG) brain PET study caused by physiologic muscular activity to emphasize the importance of quality assurance of the imaging processing.

CASE REPORT

A 67-year-old female patient who had been diagnosed probable Alzheimer's disease for 1 year. She had a history of traumatic brain injury 20 years ago. She had no localized

neurological symptom or history of headache. Her fasting glucose level on the day of (¹⁸F) FDG PET imaging was 103 mg/dL. During 30 min following, intravenous injection of 6.2 mCi (229.4 MBq) (¹⁸F) FDG, the patient was instructed to rest in the dimly lit quiet room, without talking, reading, or having active muscle movement. Subsequently, PET/CT images were acquired for 30 min (six 5-min frames added together after confirmation of no head motion) and reconstructed using a 3D Iterative reconstruction method

TANYALUCK THIENTUNYAKIT, SATOSHI MINOSHIMA¹

Department of Radiology, Division of Nuclear Medicine, Faculty of Medicine Siriraj Hospital, Mahidol University, Bangkok, Thailand, ¹Department of Radiology and Imaging Sciences, University of Utah, Salt Lake City, Utah, USA


Address for correspondence: Dr. Tanyaluck Thientunyakit, Department of Radiology, Division of Nuclear Medicine, Faculty of Medicine Siriraj Hospital, Mahidol University, Bangkok 10700, Thailand.
E-mail: stanyalu@hotmail.com

Submission: 31-Oct-18, **Accepted:** 09-Nov-18, **Published:** 23-Jul-2019

This is an open access journal, and articles are distributed under the terms of the Creative Commons Attribution-NonCommercial-ShareAlike 4.0 License, which allows others to remix, tweak, and build upon the work non-commercially, as long as appropriate credit is given and the new creations are licensed under the identical terms.

For reprints contact: reprints@medknow.com

How to cite this article: Thientunyakit T, Minoshima S. Temporal muscle uptake causing an unusual focal artifact on three-dimensional stereotactic surface projections statistical maps of (¹⁸F) fluorodeoxyglucose brain positron emission tomography in a patient with Alzheimer's disease. World J Nucl Med 2020;19:168-70.

Access this article online	
Website: www.wjnm.org	Quick Response Code 
DOI: 10.4103/wjnm.WJNM_97_18	

(4 iterations and 20 subsets). The visual interpretation was done by an experienced nuclear medicine physician along with quantitative analysis using 3D-SSP analysis obtained by Cortex ID software (GE Healthcare, Milwaukee, WI, USA).

Her (^{18}F) FDG brain PET images showed hypometabolism in posterior cingulate, precuneus, parietal association, frontal and temporal lobes, bilaterally, which was consistent with Alzheimer's disease. Apart from that, there was diffuse extracranial FDG uptake in the bilateral temporal and masseter muscles. The intense muscle uptake fused with cortical uptake in the right frontal lobe due to particular anatomic proximity and limited image resolution, which resulted in an unusual focal artifact in the right frontal lobe on both 3D-SSP projection image and 3D-SSP Z-score map demonstrating areas of decreased uptake at the corresponded right frontal lobe region [Figure 1a-f] without demonstrable anatomical abnormality in the following magnetic resonance imaging of the brain.

DISCUSSION

Physiologic skeletal muscle FDG uptake has been described,^[2] most commonly in the head and neck areas^[3] resulting from voluntary muscular activity^[4] or involuntary activity such as stress-induced muscle tension or spasm.^[5-8] The physiologic uptake of FDG in temporal and masseter muscles, in this case, might be explained by subconscious muscular tension,

although the patient did not report any symptom, or by voluntary activity such as clenching teeth. Anxiety was one of most common causes of increased head and neck muscle uptake,^[9] and it mainly affects paravertebral muscles.^[10]

Statistical mapping techniques such as 3D-SSP have been commonly used to improve diagnostic confidence and accuracy of SPECT and PET interpretation.^[11] However, when atypical findings, such as this rare focal artifact, are seen on the statistical maps, it is critical to inspect original images and perform quality assurance of the imaging processing, instead of simply relying on the processed maps for scan interpretation.

Declaration of patient consent

The authors certify that they have obtained all appropriate patient consent forms. In the form the patient(s) has/have given his/her/their consent for his/her/their images and other clinical information to be reported in the journal. The patients understand that their names and initials will not be published and due efforts will be made to conceal their identity, but anonymity cannot be guaranteed.

Acknowledgement

The author(s) thank Miss. Phattaranan Phawaphutanon for assisting in the clinical data record. This case is a volunteer participated in the research project co-funded by the National Research Council of Thailand via Health System Research Institute, Faculty of Medicine Siriraj Hospital, Mahidol University, and the International Atomic Energy Agency.

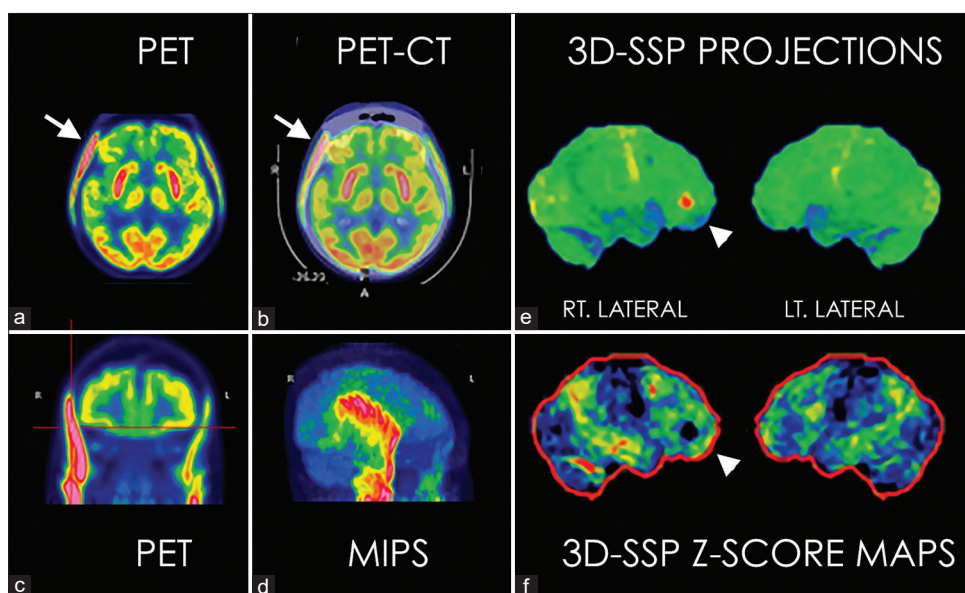


Figure 1: The transaxial (^{18}F) fluorodeoxyglucose brain positron emission tomography images (a) showed hypometabolism in bilateral frontal and temporal lobes and diffuse extracranial fluorodeoxyglucose uptake corresponding to temporal and masseter muscles bilaterally on the fused positron emission tomography/computed tomography (b) Coronal positron emission tomography (c) and maximum-intensity projection (d) confirmed extracranial uptake to be in temporal muscle, which fused with cortical uptake in the right frontal lobe (arrow, a and b) resulted in an unusual focal “hot spot” artifact in the right frontal lobe on the three-dimensional stereotactic surface projections projection image (arrowhead, e) and a round “defect” on the three-dimensional stereotactic surface projections Z-score map image (arrowhead, f)

Financial support and sponsorship

The research was partially supported by Siriraj Grant for Research Development and Faculty of Medicine Siriraj Hospital, Mahidol University.

Conflicts of interest

There are no conflicts of interest.

REFERENCES

1. Minoshima S, Frey KA, Koeppe RA, Foster NL, Kuhl DE. A diagnostic approach in Alzheimer's disease using three-dimensional stereotactic surface projections of fluorine-18-FDG PET. *J Nucl Med* 1995;36:1238-48.
2. Karunanithi S, Soundararajan R, Sharma P, Naswa N, Bal C, Kumar R, *et al.* Spectrum of physiologic and pathologic skeletal muscle (18)F-FDG uptake on PET/CT. *AJR Am J Roentgenol* 2015;205:W141-9.
3. Parida GK, Roy SG, Kumar R. FDG-PET/CT in skeletal muscle: Pitfalls and pathologies. *Semin Nucl Med* 2017;47:362-72.
4. Bar-Shalom R. Muscle uptake of 18-fluorine fluorodeoxyglucose. *Semin Nucl Med* 2000;30:306-9.
5. Barrington SF, Maisey MN. Skeletal muscle uptake of fluorine-18-FDG: Effect of oral diazepam. *J Nucl Med* 1996;37:1127-9.
6. Abouzied MM, Crawford ES, Nabi HA. 18F-FDG imaging: Pitfalls and artifacts. *J Nucl Med Technol* 2005;33:145-55.
7. Kostakoglu L, Wong JC, Barrington SF, Cronin BF, Dynes AM, Maisey MN, *et al.* Speech-related visualization of laryngeal muscles with fluorine-18-FDG. *J Nucl Med* 1996;37:1771-3.
8. Jabour BA, Choi Y, Hoh CK, Rege SD, Soong JC, Lufkin RB, *et al.* Extracranial head and neck: PET imaging with 2-[F-18] fluoro-2-deoxy-D-glucose and MR imaging correlation. *Radiology* 1993;186:27-35.
9. Cohade C, Osman M, Pannu HK, Wahl RL. Uptake in supraclavicular area fat ("USA-fat"): Description on 18F-FDG PET/CT. *J Nucl Med* 2003;44:170-6.
10. Engel H, Steinert H, Buck A, Berthold T, Huch Böni RA, von Schulthess GK, *et al.* Whole-body PET: Physiological and artifactual fluorodeoxyglucose accumulations. *J Nucl Med* 1996;37:441-6.