

## Original Article

## Correlation between imaging and tissue biomarkers of hypoxia in squamous cell cancer of the head and neck

## ABSTRACT

The aim of this study was to correlate endogenous tissue biomarkers of hypoxia with quantitative imaging parameters derived from  $^{18}\text{F}$ -fluoro-misonidazole (F-MISO) and  $^{18}\text{F}$ -fluoro-deoxy-glucose (FDG) positron emission tomography/computed tomography (PET/CT) and clinical outcomes in locoregionally advanced head and neck squamous cell carcinoma (HNSCC). Tumor-tissue blocks of HNSCC patients with pretreatment F-MISO-PET/CT and FDG-PET/CT were de-archived for expression of hypoxia-inducible factor-1 alpha (HIF-1 $\alpha$ ) subunit, carbonic anhydrase-IX (CA-IX), and glucose transporter subunit-1 (GLUT-1) using immunohistochemistry (IHC). The intensity of staining was graded and correlated with quantitative imaging parameters and with disease-related outcomes. Tissue blocks were analyzed for 14 of 20 patients. On IHC, median H-scores for HIF-1 $\alpha$ , CA-IX, and GLUT-1 were 130, 0, and 95, respectively. No significant correlation of tissue biomarkers of hypoxia with quantitative imaging parameters was found. However, borderline significant correlation was seen for H-scores of CA-IX with hypoxic tumor volume (HTV) ( $r = 0.873$ ,  $P = 0.054$ ) and fractional hypoxic volume ( $r = 0.824$ ,  $P = 0.086$ ) derived from F-MISO-PET/CT. At a median follow-up of 43 months, 5-year Kaplan–Meier estimates of locoregional control, disease-free survival, and overall survival were 53%, 43%, and 40%, respectively. Increased expression of HIF-1 $\alpha$  or GLUT-1 (dichotomized by median H-scores) was not individually associated with disease-related outcomes. However, a combination of high HTV (>4.89cc) with above median H-scores of either HIF-1 $\alpha$  (>130) and/or GLUT-1 (>95) was associated with worse clinical outcomes. None of the three patients with such “adverse hypoxic profile” were long-term survivors. There is no significant correlation of endogenous tissue biomarkers of hypoxia (HIF-1 $\alpha$ , CA-IX, and GLUT-1) with quantitative imaging parameters (on F-MISO-PET/CT and FDG-PET/CT) or long-term outcomes in HNSCC. However, a combination of both can identify a subgroup of patients with adverse outcomes.

**Keywords:** And imaging, biomarkers, head–neck cancer, hypoxia, immunohistochemistry

## INTRODUCTION

Head and neck squamous cell carcinoma (HNSCC) presents as advanced-stage disease (Stages III–IV) in large majority of patients worldwide, with resultant unsatisfactory outcomes despite aggressive multimodality treatment. Definitive radiotherapy combined with concurrent chemotherapy is the contemporary standard of care in the nonsurgical management of advanced stage HNSCC<sup>[1,2]</sup> and is associated with variable 5-year disease-related outcomes ranging from 40% to 65%.<sup>[3]</sup> Although distant metastases are being increasingly recognized, the predominant pattern of relapse in HNSCC still remains central in-field failure in the high-dose region within the index tumor bed.<sup>[4]</sup> One of the well-known adverse


**SHREYA KUNDER, ABHISHEK CHATTERJEE, SUBHAKANKHA MANNA<sup>1</sup>, MANOJ MAHIMKAR<sup>1</sup>, ASAWARI PATIL<sup>2</sup>, VENKATESH RANGARAJAN<sup>3</sup>, ASHWINI BUDRUKKAR, SARBANI GHOSH-LASKAR, JAI PRAKASH AGARWAL, TEJPAL GUPTA**

Departments of Radiation Oncology, <sup>1</sup>Mahimkar Lab, <sup>2</sup>Pathology, <sup>3</sup>Nuclear Medicine & Molecular Imaging, Advanced Centre for Treatment Research & Education in Cancer (ACTREC)/Tata Memorial Hospital (TMH), Tata Memorial Centre, Homi Bhabha National Institute (HBNI), Mumbai, India

**Address for correspondence:** Dr. Tejpal Gupta, Department of Radiation Oncology, Advanced Centre for Treatment Research and Education in Cancer, Tata Memorial Centre, Homi Bhabha National Institute, Tata Memorial Hospital, Kharghar, Navi Mumbai - 410 210, Maharashtra, India.  
E-mail: tejpgupta@rediffmail.com

**Submitted:** 04-Jul-2020, **Revised:** 29-Nov-2020,

**Accepted:** 11-Jan-2021, **Published:** 20-Aug-2021

Access this article online	
<b>Website:</b> www.wjnm.org	<b>Quick Response Code</b> 
<b>DOI:</b> 10.4103/wjnm.WJNM_91_20	

This is an open access journal, and articles are distributed under the terms of the Creative Commons Attribution-NonCommercial-ShareAlike 4.0 License, which allows others to remix, tweak, and build upon the work non-commercially, as long as appropriate credit is given and the new creations are licensed under the identical terms.

**For reprints contact:** WKHLRPMedknow\_reprints@wolterskluwer.com

**How to cite this article:** Kunder S, Chatterjee A, Manna S, Mahimkar M, Patil A, Rangarajan V, *et al.* Correlation between imaging and tissue biomarkers of hypoxia in squamous cell cancer of the head and neck. World J Nucl Med 2021;20:228-36.

biological features associated with significantly increased risk of failure and compromised outcomes in various solid tumors including HNSCC is tumor hypoxia.<sup>[5,6]</sup> Indirect methods of visualization of tumor hypoxia using biological and functional imaging such as positron emission tomography/computed tomography (PET/CT) offer valuable insights into tumor biology.<sup>[6]</sup> Hypoxia PET imaging, usually done with substituted nitroimidazoles such as <sup>18</sup>F-fluoro-misonidazole (F-MISO) allows noninvasive visualization and quantification of tumor hypoxia at the macroscopic level, with segmented hypoxic volumes carrying independent prognostic significance.<sup>[7,8]</sup> Alternatively, assessment of endogenous tissue biomarkers of hypoxia using immunohistochemistry (IHC) on formalin-fixed paraffin-embedded (FFPE) tumor-tissue blocks represents an attractive method to visualize and quantify hypoxia at the cellular and microscopic level with high expression of endogenous hypoxic biomarkers correlating with worse outcomes.<sup>[9,10]</sup> There is very sparse data investigating the correlation of hypoxia imaging biomarkers (derived from F-MISO-PET/CT) with endogenous tissue biomarkers of hypoxia (assessed on FFPE tumor-tissue blocks) and their association with clinical outcomes in HNSCC. The most optimal timing of F-MISO-PET/CT acquisition for assessment of tumor hypoxia has been reported<sup>[11]</sup> and correlated with various quantitative functional imaging parameters with each other as well as long-term outcomes in a prospective cohort of HNSCC patients treated with definitive radio(chemo) therapy.<sup>[12]</sup> Herein, we assess and report on the correlation of endogenous tissue biomarkers of hypoxia with quantitative imaging parameters derived from F-MISO-PET/CT and <sup>18</sup>F-fluoro-deoxy-glucose (FDG)-PET/CT and test the association of these tissue biomarkers with long-term clinical outcomes in the same study cohort.

## MATERIALS AND METHODS

Patient selection criteria have been described in detail previously.<sup>[11,12]</sup> Briefly, adults (18–65 years of age) with locoregionally confined (stage cT1-T3, N0-N2c), biopsy-proven squamous cancer of the oropharynx, hypopharynx, or larynx and planned for definitive radio(chemo) therapy were included after written informed consent. The index study registered with the Clinical Trials Registry of India (CTRI 2013/09/003988) was duly reviewed (Project No. 1088), with a separate review for this study (Project 3032) and approved by the Institutional Ethics Committee of our institute that functions in accordance with the Declaration of Helsinki. All patients provided written informed consent before participation in the index study, however for the current project, we received a waiver of consent (as there was no additional contact needed with participants by the

researchers for this study). All biological imagings as well as testing of endogenous tissue biomarkers on the study were funded through competitive institutional research grants with the sponsors having no role in the design, conduct, interpretation, or reporting.

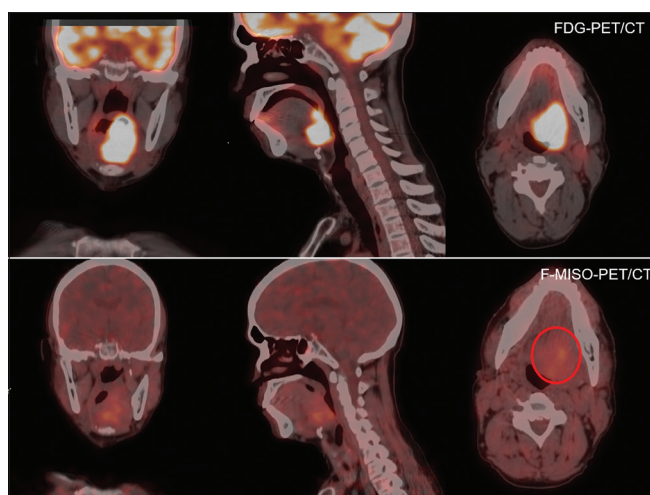
### Pretreatment imaging

Metabolic and hypoxia imaging on the study were scheduled typically within 10 days of biopsy from the primary site. The median time interval between biopsy and first PET imaging was 9 days (range 1–23 days). All pretreatment imaging was done within 1 week (typically 3–5 days) of each other. All patients underwent CT-based simulation and target volume delineation. Gross tumor volume (GTV) of the primary tumor delineated on planning CT was recorded as  $GTV_{CT}$ . Details of pretreatment FDG-PET/CT and F-MISO-PET/CT image acquisition and segmentation have been described in detail.<sup>[11,12]</sup> Briefly, a whole-body (vertex till the upper thigh) scan was acquired in the fasting state nearly 45–60 min after intravenous injection of FDG at 5 mBq/kg body weight. All FDG-PET imagings were done on a 16-slice time-of-flight (TOF) PET/CT scanner system (Philips Gemini with Astonish reconstruction) with 60 s per bed position and 50% overlap for the emission study with CT-based attenuation correction using postacquisition correction algorithms and processed on a Philips Extended Brilliance Workspace (EBW) workstation using tumor tracking software. Quantitative FDG-PET/CT parameters included calculation of maximum, mean, and minimum standardized uptake values ( $SUV_{max-FDG}$ ,  $SUV_{mean-FDG}$ , and  $SUV_{min-FDG}$ ) using standardized, validated methodology. Briefly, volumetric regions of interest (ROIs) encompassing the primary tumor were placed on FDG-PET/CT images and an automatic edge-detection algorithm was used to generate the metabolic tumor volume (MTV) using 42% of  $SUV_{max}$  as per our standard institutional practice. Any part of MTV initially defined by such relative thresholding that extended beyond the soft tissues into air or bone was edited away to yield the actual MTV. F-MISO used for hypoxia imaging in our study was synthesized by an accredited, certified laboratory as per previously published protocol<sup>[13]</sup> with a radiochemical purity >95% and duly approved for human use by the national regulatory agency. F-MISO was injected at 3.5 mBq/kg body weight without a specific need for fasting and images were acquired on the same 16-slice TOF PET/CT scanner system (Philips Gemini with Astonish reconstruction) at 1-, 3-, and 5-h postinjection of the radionuclide. The scan area encompassed the entire head and neck region including lung apices inferiorly. The scans were acquired at 45 s per bed position for the 1-h study, 75 s per bed position for the 3-h study, and 2 min per bed position for the 5-h study. CT-based attenuation correction was done of the TOF acquired

data with postacquisition correction algorithms. F-MISO imaging data were also processed on Philips EBW workstation using tumor tracking software. Spherical ROIs were placed on the F-MISO-PET/CT images on contralateral posterior neck musculature opposite the axial CT slice containing the largest transverse dimensions of the primary tumor. The mean SUV of the volume encompassed within the ROI was deemed the background and 1.5 times the background was considered as threshold for defining significant hypoxia in accordance with previously published data.<sup>[14]</sup> Using this threshold, volumetric ROIs encompassing the tumor were placed and hypoxic tumor volume (HTV) was segmented for the primary tumor. F-MISO images acquired early (at 1-h) after injection of the radiotracer were disregarded due to poor focalization limiting the correlative analysis to F-MISO scans acquired at later time points (at 3- and 5-h). Relevant quantitative parameters of interest included HTV generated on F-MISO-PET/CT scans at 3-h ( $HTV_{3hrs-F-MISO}$ ) and 5-h ( $HTV_{5hrs-F-MISO}$ ) postinjection of the radio-tracer as well as the maximum, mean, and minimum SUV at 3-h ( $SUV_{max-3hrs-F-MISO}$ ,  $SUV_{mean-3hrs-F-MISO}$ , and  $SUV_{min-3hrs-F-MISO}$ ) and 5-h ( $SUV_{max-5hrs-F-MISO}$ ,  $SUV_{mean-5hrs-F-MISO}$ , and  $SUV_{min-5hrs-F-MISO}$ ), respectively, after injection of the radio-tracer. In addition, fractional hypoxic volumes (FHV) were generated from ratios of HTV to  $GTV_{CT}$  (on planning CT) and  $MTV$  (on FDG-PET/CT for the 3-h and 5-h images ( $FHV_{CT-3hrs}$ ,  $FHV_{FDG-3hrs}$ ,  $FHV_{CT-5hrs}$ , and  $FHV_{FDG-5hrs}$ ). Representative FDG-PET/CT and F-MISO-PET/CT images of a typical patient from our study cohort are provided in Figure 1.

### Immunohistochemical staining

Biopsy samples from patients included in the study cohort preserved as FFPE tumor-tissue blocks were de-archived for analysis. IHC was done using standardized protocols to assess for tissue expression of endogenous biomarkers of hypoxia. IHC markers that were tested included hypoxia-inducible factor-1 alpha (HIF-1 $\alpha$ ) subunit, a major regulator of cellular responses to hypoxia;<sup>[15]</sup> carbonic anhydrase-IX (CA-IX), a transmembrane metalloenzyme which participates in extracellular hypoxia driven acidosis;<sup>[16]</sup> and glucose transporter subunit-1 (GLUT-1), an HIF-1 regulated molecule sustaining enhanced glycolysis in hypoxic cells.<sup>[17]</sup> A single tissue section from all cases was first stained with hematoxylin and eosin (H and E) for review by an experienced head and neck pathologist blinded to the results of PET/CT analysis to confirm the viability of the tumor and adequacy of tissue for immunohistochemical staining. The technical performance of IHC testing is described in detail in an online supplementary file (S1). Immunohistochemical scoring was carried out semiquantitatively according to Colorado Hybrid (H)-scoring criteria. The intensity of staining was scored as 0 (absent), 1 (weak), 2 (moderate), or 3 (strong) and



**Figure 1:** Coronal, sagittal, and axial sections of  $^{18}F$ -fluoro-deoxy-glucose-positron emission tomography/computed tomography (upper panel) and  $^{18}F$ -fluoro-misonidazole-positron emission tomography/computed tomography (lower panel) of a representative patient from the study cohort. Note the large  $^{18}F$ -fluoro-deoxy-glucose-avid primary tumor in the left base of the tongue with maximum standardized uptake value of 13.27. Corresponding  $^{18}F$ -fluoro-misonidazole-positron emission tomography/computed tomography of the same patient acquired 3-h after injection of the radiotracer showing focalization of  $^{18}F$ -fluoro-misonidazole (circled in the axial section) with tumor background ratio  $>1.5$  in the center of the  $^{18}F$ -fluoro-deoxy-glucose-avid primary tumor indicating the presence of hypoxia

the percentage of positive tumor cells was scored from 0% to 100%. The H-score was calculated by multiplying the intensity of staining and the percentage of positive tumor cells. The range of possible scores was from 0 to 300. In addition to the above-mentioned endogenous tissue biomarkers of hypoxia, p16 IHC<sup>[18]</sup> was also done as a surrogate for human papillomavirus (HPV)-associated head–neck cancer.

### Therapy, response assessment, and follow-up

All patients had been treated with definitive curative-intent radio(chemo) therapy using 6 MV photons on Helical Tomotherapy Hi-ART-II (Accuray, Sunnyvale, CA, USA) using simultaneous integrated boost intensity-modulated radiation therapy technique to tumoricidal doses (66–70 Gy/30–33 fractions over 6.5–7 weeks) with or without concurrent weekly cisplatin chemotherapy (30 mg/m<sup>2</sup>) as appropriate. The first follow-up was scheduled at 10–12 weeks after completion of definitive radio(chemo) therapy and consisted of detailed clinical examination and response assessment FDG-PET/CT. Subsequently, patients underwent periodic clinical follow-up as per study protocol. Any clinical suspicion of recurrence was confirmed through appropriate imaging, directed examination under anesthesia, and biopsy/cytology from the accessible lesion(s) if necessary. Salvage therapy at recurrence was at the discretion of the treating oncologist and was individualized based on the site and pattern of relapse, disease-free interval, performance status, and anticipated morbidity.

## Statistical considerations

Functional biological imaging and tumor tissues of all 20 patients included in the index study formed the dataset for this correlative study. Descriptive statistics such as median H-scores and interquartile range (IQR) were used to report and analyze the endogenous tissue biomarkers of hypoxia. Quantitative functional and biological imaging parameters were correlated with endogenous tissue biomarkers (H-scores) using Pearson's rank correlation (2-tailed) after logarithmic or square-root transformation to ensure the normality of data. For parameters, where normality could not be achieved (even after transformation), Spearman's rho correlation (2-tailed) was used assuming nonnormal distribution. Tissue biomarkers of hypoxia were also correlated with disease-related clinical outcomes. The H-scores of each tissue biomarker (derived from IHC) were dichotomized at their median values for correlating with clinical outcomes using the product-limit method of Kaplan–Meier and compared using the log-rank test. All time-to-event outcomes were calculated from the date of registration till the defined event of interest or date of the last follow-up. Time-to-event outcomes included local and/or regional failure for locoregional control (LRC); any site of failure (locoregional failure, distant metastases, or second new primary tumor) for disease-free survival (DFS); and death (due to any cause) for overall survival (OS). The cutoff date for time-to-event analysis was October 31, 2019. Any  $P < 0.05$  was considered statistically significant. Multivariate analysis was not attempted given the limited number of patients and evident collinearity between various quantitative biological imaging parameters and IHC scores. Statistical analysis was done on the Statistical Package for the Social Sciences (SPSS) version 21.0 (IBM Corp, Armonk, NY, USA).

## RESULTS

A total of 20 patients had been included in the index study after written informed consent. Patient, disease, and treatment characteristics of the study have been described in detail previously.<sup>[11]</sup> Relevant details of functional, biological imaging, and its correlation with clinical outcomes have also been reported recently.<sup>[12]</sup> Pretreatment functional, biological imaging included FDG-PET/CT in all 20 patients and F-MISO-PET/CT in 18 of 20 patients. FFPE tumor-tissue blocks were available for analysis in 14 of 20 patients. All the quantitative imaging parameters of interest used in this correlative study are summarized in Table 1. H-scores of all three tissue biomarkers (HIF-1 $\alpha$ , CA-IX, and GLUT-1) from all patients with available tumor tissue blocks ( $n = 14$ ) are described individually in Table 2. Moderate to strong

**Table 1: Descriptive imaging parameters used in the study**

Imaging parameters	Mean value (range)	Median value (95% CI)
GTV <sub>CT</sub>	25.37 (2.18-56.91) cc	22.07 (17.97-32.76)
MTV <sub>FDG</sub>	9.64 (3.07-27.26) cc	7.93 (6.57-12.71)
SUV <sub>Max-FDG</sub>	22.00 (9.12-45.21)	21.61 (17.07-26.12)
SUV <sub>Mean-FDG</sub>	13.69 (5.6-30.4)	13.44 (10.97-16.41)
HTV <sub>F-MISO-3h</sub>	6.52 (0.0-19.33) cc	4.89 (3.26-9.78)
SUV <sub>Max-F-MISO-3h</sub>	2.20 (0.0-3.62)	2.50 (1.62-2.77)
SUV <sub>Mean-F-MISO-3h</sub>	1.52 (0.0-2.8)	1.52 (1.19-1.86)
FHV <sub>CT-3hour</sub>	0.24 (0.0-0.80)	0.16 (0.10-0.38)

CI: Confidence interval; GTV: Gross tumor volume; CT: Computed tomography; MTV: Metabolic tumor volume; FDG: Fluoro-deoxy-glucose; SUV: Standardized uptake value; max: Maximum; HTV: Hypoxic tumor volume; F-MISO: Fluoro-misonidazole; FHV: Fractional hypoxic volume

**Table 2: Details of the primary site, stage, and H-scores on immunohistochemistry in patients with formalin-fixed paraffin-embedded blocks**

Site	AJCC stage (7 <sup>th</sup> edition)	H-scores on IHC		
		HIF-1 $\alpha$	CA-IX	GLUT-1
Oropharynx	T3N1	0	4	0
Oropharynx	T3N2c	180	2	90
Oropharynx	T2N2c	120	120	100
Hypopharynx	T2N2c	0	5	80
Larynx	T2N1	140	0	180
Larynx	T3N2c	40	2	0
Hypopharynx	T2N1	140	4	0
Hypopharynx	T3N1	160	0	160
Hypopharynx	T4N2c	140	0	80
Oropharynx	T3N2c	80	0	10
Hypopharynx	T3N1	180	0	0
Oropharynx	T3N2c	10	0	180
Oropharynx	T3N2a	270	0	100
Larynx	T2N0	100	0	160

IHC: Immunohistochemistry; AJCC: American Joint Committee on Cancer; HIF-1 $\alpha$ : Hypoxia-inducible factor-1 alpha subunit; CA-IX: Carbonic anhydrase-IX; GLUT-1: Glucose transporter subunit-1

intensity of IHC staining for HIF-1 $\alpha$ , CA-IX, and GLUT-1 is depicted in Figure 2 in three illustrative cases from the study cohort. The median (IQR) H-scores of HIF-1 $\alpha$ ; CA-IX; and GLUT-1 were 130 (IQR: 32.5–165); 0 (IQR: 0–4); and 95 (IQR = 0–160), respectively. IHC for p16 showed strong nuclear positivity in just 2 of the 14 FFPE samples, one of which was an advanced oropharyngeal cancer while the other site of the primary tumor was in the hypopharynx. Given that just two patients were found to be HPV-associated HNSCC based on p16-IHC, this was not used for any correlative analyses. There was no statistically significant correlation of endogenous tissue biomarkers of hypoxia on IHC with quantitative biological imaging parameters on PET/CT [Table 3]. However, correlation of borderline significance was seen for H-scores of CA-IX with HTV<sub>3 hrs-F-MISO</sub> ( $r = 0.873$ ,

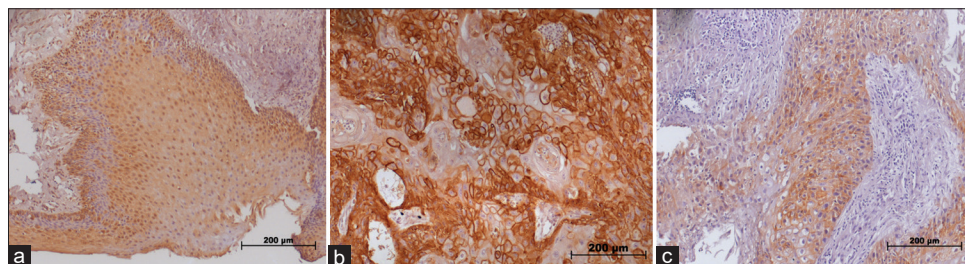
$P = 0.054$ ) and  $FHV_{CT-3\text{ hrs}}$  ( $r = 0.824, P = 0.086$ ), respectively. At a median follow-up of 43 months, the 5-year Kaplan–Meier estimates of LRC, DFS, and OS were 53%, 43%, and 40%, respectively, for the entire study cohort. Since the median H-score of CA-IX was zero, it was not used for further correlation with survival outcomes. Increased expression of HIF-1 $\alpha$  [Figure 3] or GLUT-1 [Figure 4] dichotomized by the median H-score on IHC was not associated with worse LRC or survival. However, when we grouped patients having both increased HTV (on F-MISO-PET/CT) and high expression of hypoxia markers (above median on IHC) to create “adverse hypoxic profile,” reflecting increased hypoxia both at microscopic and macroscopic levels, we found statistically

significant results. Three of the 14 patients had such adverse hypoxic profiles, none of which were long-term survivors. A combination of high  $HTV_{3\text{ hrs-F-MISO}}$  ( $>4.89\text{cc}$ ) with above median H-scores of HIF-1 $\alpha$  ( $>130$ ) resulted in significantly worse outcomes (5-year LRC: 33.3 vs. 66.7%,  $P = 0.005$ ; 5-year DFS: 0 vs. 45%,  $P < 0.0001$ ; and 5-year OS: 0 vs. 45%,  $P < 0.0001$ ) compared to lower than median H-scores. Similarly, the combination of high  $HTV_{3\text{ hrs-F-MISO}}$  ( $>4.89\text{cc}$ ) with above median H-scores of GLUT-1 ( $>95$ ) was also associated with significantly inferior results (5-year LRC: 0 vs. 66.7%,  $P < 0.0001$ ; 5-year DFS: 0 vs. 41.7%,  $P = 0.005$ , and 5-year OS: 0 vs. 41.7%,  $P = 0.044$ ) compared to patients with lower than median H-scores.

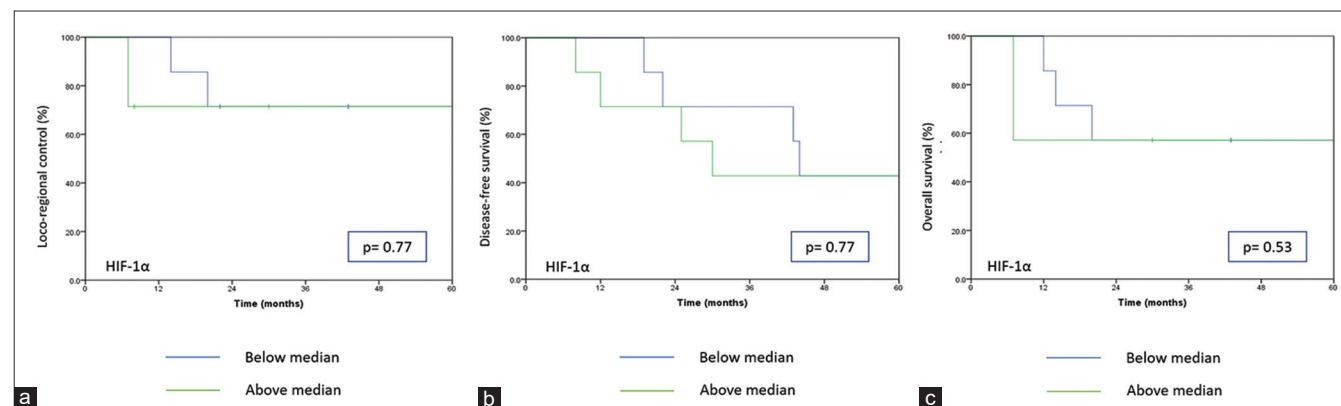
**Table 3: Correlation of imaging parameters with tissue biomarkers of hypoxia**

Imaging parameters	HIF-1 $\alpha$ H-score		CA-IX H-score		GLUT-1 H-score	
	Pearson’s coefficient (r)	P	Pearson’s coefficient (r)	P	Spearman’s coefficient ( $\rho$ )	P
GTV <sub>CT</sub>	0.030	0.920	0.174	0.780	−0.386	0.173
MTV <sub>FDG</sub>	0.060	0.838	0.488	0.404	−0.453	0.104
SUV <sub>Max-FDG</sub>	−0.316	0.271	−0.149	0.811	−0.198	0.496
SUV <sub>Mean-FDG</sub>	−0.216	0.459	−0.291	0.634	−0.290	0.314
HTV <sub>F-MISO-3 h</sub>	0.256	0.399	0.873	0.054	−0.466	0.109
SUV <sub>Max-F-MISO-3 h</sub>	−0.018	0.958	0.707	0.182	−0.111	0.746
SUV <sub>Mean-F-MISO-3 h</sub>	−0.252	0.384	0.034	0.956	−0.087	0.778
FHV <sub>CT-3 h</sub>	−0.044	0.898	0.824	0.086	−0.129	0.705

HIF-1 $\alpha$ : Hypoxia-inducible factor-1 alpha subunit; CA-IX: Carbonic anhydrase-IX; GLUT-1: Glucose transporter subunit-1; GTV: Gross tumor volume; CT: Computed tomography; MTV: Metabolic tumor volume; FDG: Fluoro-deoxy-glucose; SUV: Standardized uptake value; max: Maximum; HTV: Hypoxic tumor volume; F-MISO: Fluoro-misonidazole; FHV: Fractional hypoxic volume



**Figure 2: Representative images of immunohistochemistry (IHC) staining in HNSCC patients. (a) Strong intensity nuclear staining of hypoxia-inducible factor-1 alpha (HIF1 $\alpha$ ), (b) Strong intensity membranous staining of glucose transporter subunit 1 (GLUT1) and (c) Moderate intensity membranous staining of carbonic anhydrase IX (CAIX)**



**Figure 3: Kaplan–Meier curves dichotomized on median H-scores for hypoxia-inducible factor-1 alpha for locoregional control (a), disease-free survival (b), and overall survival (c)**

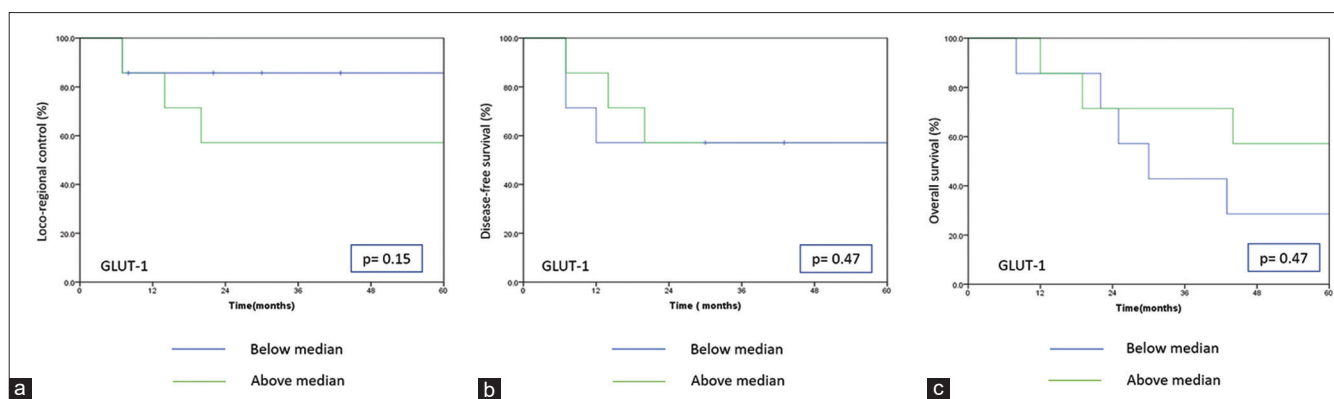


Figure 4: Kaplan–Meier curves dichotomized on median H-scores for glucose transporter subunit-1 for locoregional control (a), disease-free survival (b), and overall survival (c)

## DISCUSSION

Survival outcomes in locoregionally advanced HNSCC have plateaued in the last one decade, necessitating deeper insights into disease biology to identify intrinsic tumor characteristics which may be useful for treatment selection and optimization. Hypoxia is a well-characterized entity in this regard that interacts and negatively impacts on tumor microenvironment to regulate complex biological processes such as metabolism,<sup>[19]</sup> angiogenesis and invasion,<sup>[20]</sup> metastasis,<sup>[21]</sup> and suppression of antitumor immunity<sup>[22]</sup> with resultant detrimental impact on outcomes. The largest systematic review<sup>[23]</sup> of 40 studies investigating tissue-based hypoxia biomarkers in HNSCC reported the correlation of higher biomarker expression with adverse features (advanced stage disease and poorly differentiated tumors) suggesting more aggressive disease biology. Increased expression of all tested endogenous biomarkers of hypoxia (HIF-1 $\alpha$ , osteopontin, CA-IX, and GLUT-1) excepting HIF-2 $\alpha$  was associated with worse clinical outcomes in multiple studies across different settings, especially in studies wherein patients received single-modality treatment, recommending the need for combined-modality treatment including hypoxia modification. There is now unequivocal clinical evidence that hypoxic modification improves outcomes in several solid tumors including HNSCC,<sup>[24]</sup> particularly to radiotherapy.<sup>[25]</sup> However, it is increasingly being recognized that hypoxia is a complex phenomenon with plasticity between the static component (represented by tissue sampling) and dynamic component (represented by hypoxia imaging) which can differentially affect downstream signaling pathways.

The current report is our initial correlative analysis between endogenous tissue biomarkers of hypoxia (HIF-1 $\alpha$ , CA-IX, and GLUT-1) with quantitative metabolic (FDG-PET/CT) and hypoxia imaging parameters (F-MISO-PET/CT) and their association with long-term clinical outcomes in a prospective

cohort of patients of HNSCC treated with definitive radio(chemo) therapy. Unfortunately, we did not observe any statistically significant correlation between tissue and imaging biomarkers of hypoxia. A similar lack of association between H-scores of tissue biomarkers of hypoxia (Ku80, CA-IX, and CD44) and quantitative imaging parameters (tumor volume on FDG-PET/CT, hypoxic subvolume, and SUVmax on F-MISO-PET/CT) has been reported in a cohort of 16 patients with HNSCC.<sup>[26]</sup> Lack of such association could be partly ascribed to relatively small number of patients analyzed, but also to the intrinsic limitations of small biopsy samples and issues inherent to the preservation of tumor tissues in FFPE blocks. Conversely, another study<sup>[27]</sup> reported weak positive correlation between hypoxic volumes (derived from F-MISO-PET/CT) and HIF-1 $\alpha$  ( $r = 0.40$ ,  $P = 0.037$ ) and p53 expression ( $r = 0.47$ ,  $P = 0.012$ ) on IHC in 28 head and neck tumor samples. We also failed to demonstrate the negative impact of increased expression of any of the tissue biomarkers of hypoxia (dichotomizing on their H-scores) individually on disease-related outcomes. However, an exploratory subgroup analysis demonstrated that patients with “adverse hypoxic profile” defined as a combination of high HTV<sub>3</sub> hrs-F-MISO ( $>4.89$ cc) with above median H-scores (HIF-1 $\alpha$   $>130$  or GLUT-1  $>95$ ) did significantly worse with no long-term survivors. This finding does suggest that hypoxia at both the macroscopic and cellular/microscopic level can be quantified with the potential to determine a threshold above which patients are likely to have much worse outcomes making them candidates for treatment modification. Our findings also find support in recently published literature whereby the association between increased HIF-1 $\alpha$  and inferior outcomes could not be established.<sup>[28]</sup> However, the same study showed association between increased CA-IX expression and higher locoregional failure. In addition, increased expression of tissue biomarkers of hypoxia was associated with increased residual hypoxia on mid-treatment imaging and delayed resolution of hypoxia between weeks 2 and 5 of radiotherapy,

a phenomenon which has been shown to be associated with inferior LRC.<sup>[29]</sup> The published literature in this regard coupled with our own findings lends credence to the hypothesis that a combination of endogenous tissue-based and imaging biomarkers of hypoxia can predict treatment outcomes with the potential to guide and optimize therapeutic decision-making.

### Strengths and limitations

Our study has the innate strength of a prospective design with mature follow-up, conducted at a single-tertiary care institution with uniformity in terms of pretreatment anatomic and functional imaging; contouring and delineation of target volumes; radiotherapy treatment planning and delivery; posttreatment assessments and follow-up, and consistency in the technical performance of IHC protocol. Notwithstanding the findings and results, certain caveats and limitations remain. The biggest limitation being the small sample size (limited patient numbers) which impairs the robustness of any statistical analyses. Although the original study was designed and conducted as a prospective observational study, the present analysis correlating endogenous tissue biomarkers with quantitative imaging parameters was attempted retrospectively with inherent biases and limitations. Consequently, tumor tissues from FFPE blocks were available in only 14 of 20 patients who underwent biological imaging, further reducing the sample size for such correlative analyses. All these patients were treated with nonsurgical therapy, i.e., definitive radio(chemo) therapy; hence, the assessment of endogenous tissue biomarkers was limited to small pretreatment biopsy samples, which may not be entirely representative of the tumor heterogeneity in terms of hypoxia, proliferation, and metabolism. Since there was a long-time interval (over 5 years) from pretreatment biopsy to de-archival of the FFPE blocks for doing IHC, there could be doubts over retaining antigenicity for such analyses. It has been shown previously<sup>[30]</sup> that while cytoplasmic antigens do not lose their immunostaining intensity over time, membranous and nuclear antigens present reduced staining intensity in older blocks. The use of deep sectioning and lengthening of heat pretreatment as a solution to recover antigenicity has also been suggested, which was not done in our study. Nevertheless, we did achieve appropriate HIF-1 $\alpha$  staining and GLUT-1 staining in most of the tissue samples suggesting adequate tissue preservation and antigenicity. The lack of CA-IX staining in the majority of samples is likely related to the antibody clone rather than the technical performance of the test. Finally, all our analysis was limited to biopsy samples from the primary tumor alone without interrogating regional lymph nodes in the neck, the single most important prognostic factor

in HNSCC. Secondary analysis of a prospective hypoxia imaging study suggests that combined reading of hypoxia at the primary tumor plus lymph nodes in the neck using F-MISO-PET/CT adds valuable prognostic information.<sup>[31]</sup> Although most widely used for hypoxia imaging, it is well known that F-MISO has relatively poor uptake in hypoxic regions with resultant low tumor to background ratio (TBR) which could also be one of the reasons for lack of correlation of quantitative imaging parameters with tissue biomarkers of hypoxia in our study. Newer 2-nitroimidazole PET tracers such <sup>18</sup>F-flortanidazole (HX4), <sup>18</sup>F-fluoroazomycin arabinoside (FAZA), and <sup>18</sup>F-fluoroerythronitroimidazole with greater uptake and novel copper (Cu)-labeled analogs such as <sup>64</sup>Cu-diacetyl-bis(N4-methylthiosemi carbazon) (<sup>64</sup>Cu-ATSM) with higher retention in hypoxic areas result in much higher TBR and provide for better quantification of hypoxia which might improve correlation with tissue biomarkers.<sup>[32-34]</sup>

The adverse impact of significant hypoxia and the benefit of hypoxic modification is well established in locoregionally advanced HNSCC. Larger well-designed prospective studies incorporating both imaging and tissue biomarkers of hypoxia are likely to identify a cohort of patients who even after being balanced for stage are liable to do much worse on account of adverse hypoxia dynamics and be candidates for treatment modification and intensification. One strategy for the same could be radiotherapy dose escalation within the hypoxic fraction of the tumor. One such phase II randomized study NCT02352792<sup>[35]</sup> has completed accrual, whose results are eagerly awaited. The same concept is currently being tested in a larger pivotal phase III randomized controlled trial-ESCALOX study.<sup>[36]</sup> An alternative strategy could be the addition of hypoxic-cell sensitizers to definitive concurrent chemoradiotherapy, the contemporary standard of care in locoregionally advanced HNSCC. The Trans-Tasman Radiation Oncology Group (TROG) 02.02 Head START study<sup>[37]</sup> testing the addition of tirapazamine as hypoxic-cell sensitizer to definitive concurrent chemoradiotherapy could not demonstrate any meaningful improvement in outcomes. However, the TROG study did not use any hypoxia imaging to enrich its patient population or identify subgroups that would potentially benefit from such an approach. This strategy is now being explored in the DAHANCA 33 trial that uses <sup>18</sup>F-FAZA-PET to identify and quantify hypoxia for adding hypoxic-cell sensitizer nimorazole to hyperfractionated-accelerated radiotherapy with concurrent cisplatin-based chemotherapy.<sup>[38]</sup> The administration of HIF-1 $\alpha$  inhibitors postradiotherapy has been shown to mitigate the upregulation of HIF-1 $\alpha$  and arrest tumor growth<sup>[39]</sup> which may be worth testing as an adjuvant consolidation approach.

Oral topotecan has shown some efficacy as an inhibitor of HIF-1 $\alpha$  and is being currently tested for efficacy among refractory solid tumors with high HIF-1 $\alpha$  expression.<sup>[40]</sup> All such treatment intensification approaches are likely to benefit from precise identification of imaging and tissue biomarkers of hypoxia and our study provides some proof of principle in this regard, but mandates prospective validation in larger multiinstitutional cohorts.

## CONCLUSIONS

There is no significant correlation of endogenous tissue biomarkers of hypoxia (HIF-1 $\alpha$ , CA-IX, and GLUT-1) with quantitative imaging parameters (on F-MISO-PET/CT and FDG-PET/CT) or long-term outcomes in HNSCC. However, a combination of both can identify a subgroup of patients with adverse hypoxic profiles that may potentially benefit from treatment modification or intensification.

## Financial support and sponsorship

All functional imagings as well as IHC for assessment of tissue biomarkers on the study were funded through competitive intramural research grants from Tata Memorial Centre, Mumbai, India. The sponsor, however, had no role in the study design, conduct, data collection, analysis, or reporting of results.

## Conflicts of interest

There are no conflicts of interest.

## REFERENCES

- Pignon JP, le Maître A, Maillard E, Bourhis J, MACH-NC Collaborative Group. Meta-analysis of chemotherapy in head and neck cancer (MACH-NC): An update on 93 randomised trials and 17,346 patients. *Radiother Oncol* 2009;92:4-14.
- Pfister DG, Spencer S, Brizel DM, Burness B, Busse PM, Caudell JJ, *et al.* Head and neck cancers, Version 2.2014. Clinical practice guidelines in oncology. *J Natl Compr Canc Netw* 2014;12:1454-87.
- Michiels S, Le Maître A, Buyse M, Burzykowski T, Maillard E, Bogaerts J, *et al.* Surrogate endpoints for overall survival in locally advanced head and neck cancer: Meta-analyses of individual patient data. *Lancet Oncol* 2009;10:341-50.
- Leeman JE, Li JG, Pei X, Venigalla P, Zumsteg ZS, Katsoulakis E, *et al.* Patterns of Treatment failure and postrecurrence outcomes among patients with locally advanced head and neck squamous cell carcinoma after chemoradiotherapy using modern radiation techniques. *JAMA Oncol* 2017;3:1487-94.
- Brizel DM, Sibley GS, Prosnitz LR, Scher RL, Dewhirst MW. Tumor hypoxia adversely affects the prognosis of carcinoma of the head and neck. *Int J Radiat Oncol Biol Phys* 1997;38:285-9.
- Hammond EM, Asselin MC, Forster D, O'Connor JP, Senra JM, Williams KJ. The meaning, measurement and modification of hypoxia in the laboratory and the clinic. *Clin Oncol (R Coll Radiol)* 2014;26:277-88.
- Rajendran JG, Krohn KA. F-18 fluoromisonidazole for imaging tumor hypoxia: Imaging the microenvironment for personalized cancer therapy. *Semin Nucl Med* 2015;45:151-62.
- Chirla R, Marcu LG. PET-based quantification of statistical properties of hypoxic tumor subvolumes in head and neck cancer. *Phys Med* 2016;32:23-35.
- Peterle GT, Maia LL, Trivilin LO, de Oliveira MM, Dos Santos JG, Mendes SO, *et al.* PAI-1, CAIX, and VEGFA expressions as prognosis markers in oral squamous cell carcinoma. *J Oral Pathol Med* 2018;47:566-74.
- Beasley NJ, Wykoff CC, Watson PH, Leek R, Turley H, Gatter K, *et al.* Carbonic anhydrase IX, an endogenous hypoxia marker, expression in head and neck squamous cell carcinoma and its relationship to hypoxia, necrosis, and microvessel density. *Cancer Res* 2001;61:5262-7.
- Chatterjee A, Gupta T, Rangarajan V, Purandare N, Kunder S, Murthy V, *et al.* Optimal timing of fluorine-18-fluoromisonidazole positron emission tomography/computed tomography for assessment of tumor hypoxia in patients with head and neck squamous cell carcinoma. *Nucl Med Commun* 2018;39:859-64.
- Gupta T, Chatterjee A, Rangarajan V, Purandare N, Arya S, Murthy V, *et al.* Evaluation of quantitative imaging parameters in head and neck squamous cell carcinoma. *Q J Nucl Med Mol Imaging* 2019. DOI: 10.23736/S1824-4785.19.03179-0.
- Nandy S, Rajan MG, Korde A, Krishnamurthy NV. The possibility of a fully automated procedure for radiosynthesis of fluorine-18-labeled fluoromisonidazole using a simplified single, neutral alumina column purification procedure. *Appl Radiat Isot* 2010;68:1937-43.
- Bittner MI, Wiedenmann N, Bucher S, Hentschel M, Mix M, Weber WA, *et al.* Exploratory geographical analysis of hypoxic subvolumes using 18F-MISO-PET imaging in patients with head and neck cancer in the course of primary chemoradiotherapy. *Radiother Oncol* 2013;108:511-6.
- Calzada MJ, del Peso L. Hypoxia-inducible factors and cancer. *Clin Transl Oncol* 2007;9:278-89.
- Hilvo M, Baranauskiene L, Salzano AM, Scaloni A, Matulis D, Innocenti A, *et al.* Biochemical characterization of CA IX, one of the most active carbonic anhydrase isozymes. *J Biol Chem* 2008;283:27799-809.
- Semenza GL, Roth PH, Fang HM, Wang GL. Transcriptional regulation of genes encoding glycolytic enzymes by hypoxia-inducible factor 1. *J Biol Chem* 1994;269:23757-63.
- Bhosale PG, Pandey M, Desai RS, Patil A, Kane S, Prabhaskar K, *et al.* Low prevalence of transcriptionally active human papilloma virus in Indian patients with HNSCC and leukoplakia. *Oral Surg Oral Med Oral Pathol Oral Radiol* 2016;122:609-18.
- Minn H, Clavo AC, Wahl RL. Influence of hypoxia on tracer accumulation in squamous-cell carcinoma: *In vitro* evaluation for PET imaging. *Nucl Med Biol* 1996;23:941-6.
- Zimna A, Kurpisz M. Hypoxia-inducible factor-1 in physiological and pathophysiological angiogenesis: Applications and therapies. *Biomed Res Int* 2015;2015:549412.
- Nobre AR, Entenberg D, Wang Y, Condeelis J, Aguirre-Ghisso JA. The different routes to metastasis via hypoxia-regulated programs. *Trends Cell Biol* 2018;28:941-56.
- Noman MZ, Hasmim M, Messai Y, Terry S, Kieda C, Janji B, *et al.* Hypoxia: A key player in antitumor immune response. A review in the theme: Cellular responses to hypoxia. *Am J Physiol Cell Physiol* 2015;309:C569-79.
- Swartz JE, Pothan AJ, Stegeman I, Willems SM, Grolman W. Clinical implications of hypoxia biomarker expression in head and neck squamous cell carcinoma: A systematic review. *Cancer Med* 2015;4:1101-16.
- Overgaard J. Hypoxic modification of radiotherapy in squamous cell carcinoma of the head and neck-A systematic review and meta-analysis. *Radiother Oncol* 2011;100:22-32.
- Horsman MR, Overgaard J. The impact of hypoxia and its modification on the outcome of radiotherapy. *J Radiat Res* 2016;57:i90-8.
- Bittner MI, Wiedenmann N, Bucher S, Hentschel M, Mix M, Rücker G, *et al.* Analysis of relation between hypoxia PET imaging and tissue-based



- biomarkers during head and neck radiochemotherapy. *Acta Oncol* 2016;55:1299-304.
27. Norikane T, Yamamoto Y, Maeda Y, Kudomi N, Matsunaga T, Haba R, *et al.* Correlation of (18) F-fluoromisonidazole PET findings with HIF-1 $\alpha$  and p53 expressions in head and neck cancer: Comparison with (18) F-FDG PET. *Nucl Med Commun* 2014;35:30-5.
  28. Nicolay NH, Wiedenmann N, Mix M, Weber WA, Werner M, Grosu AL, *et al.* Correlative analyses between tissue-based hypoxia biomarkers and hypoxia PET imaging in head and neck cancer patients during radiochemotherapy-results from a prospective trial. *Eur J Nucl Med Mol Imaging* 2020;47:1046-55.
  29. Löck S, Perrin R, Seidlitz A, Bandurska-Luque A, Zschaecck S, Zöphel K, *et al.* Residual tumour hypoxia in head-and-neck cancer patients undergoing primary radiochemotherapy, final results of a prospective trial on repeat FMISO-PET imaging. *Radiother Oncol* 2017;124:533-40.
  30. Grillo F, Bruzzone M, Pigozzi S, Prosapio S, Migliora P, Fiocca R, *et al.* Immunohistochemistry on old archival paraffin blocks: Is there an expiry date? *J Clin Pathol* 2017;70:988-93.
  31. Bandurska-Luque A, Löck S, Haase R, Richter C, Zöphel K, Perrin R, *et al.* Correlation between FMISO-PET based hypoxia in the primary tumour and in lymph node metastases in locally advanced HNSCC patients. *Clin Transl Radiat Oncol* 2019;15:108-12.
  32. Marcu LG, Harriss-Phillips WM, Filip SM. Hypoxia in head and neck cancer in theory and practice: A PET-based imaging approach. *Comput Math Methods Med* 2014;2014:624642.
  33. Fleming IN, Manavaki R, Blower PJ, West C, Williams KJ, Harris AL, *et al.* Imaging tumour hypoxia with positron emission tomography. *Br J Cancer* 2015;112:238-50.
  34. Lapi SE, Lewis JS, Dehdashti F. Evaluation of Hypoxia with Cu-ATSM. *Semin Nucl Med* 2015;45:177-85.
  35. Hypoxia-based Dose Escalation with Radiochemotherapy in Head and Neck Cancer - Full Text View - ClinicalTrials.gov; 2020. Available from: <https://clinicaltrials.gov/ct2/show/NCT02352792>. [Last accessed on 2020 Feb 05].
  36. Pigorsch SU, Wilkens JJ, Kampfer S, Kehl V, Hapfelmeier A, Schläger C, *et al.* Do selective radiation dose escalation and tumour hypoxia status impact the loco-regional tumour control after radio-chemotherapy of head & neck tumours? The ESCALOX protocol. *Radiat Oncol* 2017;12:45.
  37. Rischin D, Peters LJ, O'Sullivan B, Giralt J, Fisher R, Yuen K, *et al.* Tirapazamine, cisplatin, and radiation versus cisplatin and radiation for advanced squamous cell carcinoma of the head and neck (TROG 02.02, HeadSTART): A phase III trial of the trans-tasman radiation oncology group. *J Clin Oncol* 2010;28:2989-95.
  38. Saksø M, Primdahl H, Johansen J, Nowicka-Matus K, Overgaard J. On behalf of DAHANCA. DAHANCA 33: Functional image-guided dose-escalated radiotherapy to patients with hypoxic squamous cell carcinoma of the head and neck (NCT02976051). *Acta Oncol* 2020;59:208-11.
  39. Harada H, Itasaka S, Zhu Y, Zeng L, Xie X, Morinibu A, *et al.* Treatment regimen determines whether an HIF-1 inhibitor enhances or inhibits the effect of radiation therapy. *Br J Cancer*. 2009;100:747-57.
  40. A Pilot Trial of Oral Topotecan for the Treatment of Refractory Advanced Solid Neoplasms Expressing HIF-1 $\alpha$  - Full Text View - ClinicalTrials.gov; 2020. Available from: <https://clinicaltrials.gov/ct2/show/NCT00117013>. [Last accessed on 2020 Feb 05].