

## Case Report

# False-positive prostate cancer bone metastases on magnetic resonance imaging correctly classified on gallium-68-prostate-specific membrane antigen positron emission tomography computed tomography

## ABSTRACT

Imaging in prostate cancer is important in defining the local extent of disease, nodal involvement, and identifying metastases. Bone scan is the most commonly used modality for identification of bone metastasis in prostate cancer despite its reported low sensitivity and specificity compared to magnetic resonance imaging (MRI) which is the imaging gold standard for bone metastasis. Gallium-68 prostate-specific membrane antigen positron emission tomography-computed tomography ( $^{68}\text{Ga}$  PSMA PET-CT) imaging is a relatively new addition to the imaging modalities in prostate cancer. This is a report of a patient with high-risk prostate cancer with features consistent with skeletal metastases on MRI but negative for skeletal metastases on bone scan and  $^{68}\text{Ga}$  PSMA PET CT. Histology confirmed the absence of skeletal metastases.

**Keywords:**  $^{68}\text{Ga}$  Gallium prostate-specific membrane antigen positron emission tomography-computed tomography, bone metastasis, magnetic resonance imaging, prostate cancer

## INTRODUCTION

Prostate cancer is a common cause of cancer death in men that is potentially curable when it has not metastasized. High-risk disease (clinical stage T2c, Gleason score  $>8$ , and prostate-specific antigen (PSA)  $>20$  ng/ml),<sup>[1]</sup> is more often associated with metastases especially to lymph nodes and bones.  $^{99\text{m}}\text{Tc}$ -MDP bone scan is the most commonly used modality to assess for skeletal metastases in prostate cancer. However, if magnetic resonance imaging (MRI) is done, usually for defining the local extent of disease, it is more sensitive and specific for bone metastases than bone scan.<sup>[2]</sup> Gallium-68 prostate-specific membrane antigen ( $^{68}\text{Ga}$ -PSMA) is a new positron emission tomography-computed tomography (PET-CT) tracer that has shown high sensitivity and specificity for local disease, lymph node metastases, and bone metastases. We present a case of high-risk prostate cancer with false positive skeletal metastases on MRI as confirmed by histology which was truly negative on bone scan and  $^{68}\text{Ga}$ -PSMA PET-CT.

## CASE REPORT

A 53-year-old man was referred from a peripheral hospital with high-risk prostate cancer, clinical stage T2c, Gleason 4 + 5, and PSA of 103 ng/ml. He had a  $^{99\text{m}}\text{Tc}$ -MDP bone scan which was negative for skeletal metastases [Figure 1]. He was considered for radical surgery and was, therefore, sent for pelvic MRI to define the local extent of disease and  $^{68}\text{Ga}$ -PSMA PET-CT to assess for distant metastases given the high PSA level. The MRI and  $^{68}\text{Ga}$ -PSMA PET-CT were

**SOFIULLAH OLAYINKA ABUBAKAR,  
YAW AMPEM AMOAKO, NAIMA TAG, TESSA KOTZE**

Division of Nuclear Medicine, Groote Schuur Hospital,  
University of Cape Town, Cape Town, South Africa


**Address for correspondence:** Dr. Sofiullah Olayinka Abubakar,  
Division of Nuclear Medicine, C3/C4, New Main Building,  
Groote Schuur Hospital and University of Cape Town, Cape Town,  
South Africa.

E-mail: abubakar.yinka@yahoo.com

This is an open access journal, and articles are distributed under the terms of the Creative Commons Attribution-NonCommercial-ShareAlike 4.0 License, which allows others to remix, tweak, and build upon the work non-commercially, as long as appropriate credit is given and the new creations are licensed under the identical terms.

**For reprints contact:** reprints@medknow.com

**How to cite this article:** Abubakar SO, Amoako YA, Tag N, Kotze T. False-positive prostate cancer bone metastases on magnetic resonance imaging correctly classified on gallium-68-prostate-specific membrane antigen positron emission tomography computed tomography. World J Nucl Med 2018;17:305-7.

Access this article online	
<b>Website:</b> www.wjnm.org	<b>Quick Response Code</b> 
<b>DOI:</b> 10.4103/wjnm.WJNM_89_17	

acquired about 1 week apart. MRI showed inhomogeneous marrow signal with numerous low signal lesions on T1- and T2-weighted images in the pelvic bones consistent with skeletal metastases [Figure 2]. There were no skeletal metastases on <sup>68</sup>Ga-PSMA PET-CT in the pelvis or any other bone [Figure 3]. Bone marrow biopsy was done because of the discordant finding on the MRI and <sup>68</sup>Ga-PSMA PET-CT. Histology showed normal bone marrow with no evidence of malignancy [Figure 4].

## DISCUSSION

Prostate cancer is the most common malignancy after middle age and the third-most common cause of cancer death in men.<sup>[3,4]</sup> Clinical risk stratification is based on findings on digital rectal examination, Gleason grade, and PSA level. The disease extent, localized or metastatic, is assessed with imaging. Metastatic disease is more common in high-risk patients. Prostatectomy in addition to other forms of treatment may be offered to patients with localized disease whereas patients with metastases are not offered

prostatectomy.<sup>[4,5]</sup> Bone is the second-most common site of prostate cancer metastases after lymph nodes, and <sup>99m</sup>Tc-MDP bone scintigraphy which is most commonly used for assessing skeletal metastases has a lower sensitivity and specificity compared to whole-body MRI (79% vs. 97% and 82% vs. 95%).<sup>[2]</sup> Whole body MRI is however often impracticable. In prostate cancer, MRI is used to define the local extent of disease and assess invasion into surrounding structures. <sup>68</sup>Ga-PSMA PET-CT is an emerging modality that enables imaging of PSMA which is overexpressed in the primary lesion and metastases.<sup>[6,7]</sup> The expression of PSMA at the primary site and in metastatic lesions is directly related to the aggressiveness of the prostate cancer.<sup>[8]</sup> <sup>68</sup>Ga-PSMA PET-CT is highly sensitive for nodal and skeletal metastases. The role of <sup>68</sup>Ga-PSMA PET-CT in prostate cancer is still evolving. Currently, it is recommended for localization of tumor following biochemical recurrent prostate cancer and in the staging of high-risk prostate cancer.<sup>[9]</sup>

Our patient had pelvic MRI to appropriately plan for prostatectomy and had <sup>68</sup>Ga-PSMA PET-CT so as to be absolutely sure there was no metastases particularly to pelvic and intra-abdominal nodes. Had a <sup>68</sup>Ga-PSMA PET-CT not been done, the finding of pelvic bone metastases on MRI would have superseded the negative bone scan and the patient would not have been considered for radical treatment. The florid nature of the pelvic metastases seen on MRI was however not in keeping

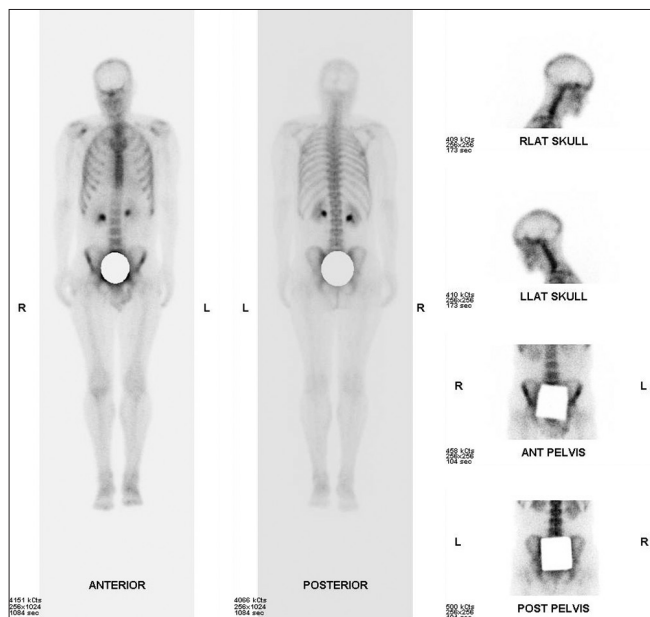


Figure 1: Bone scan shows no evidence of skeletal metastasis

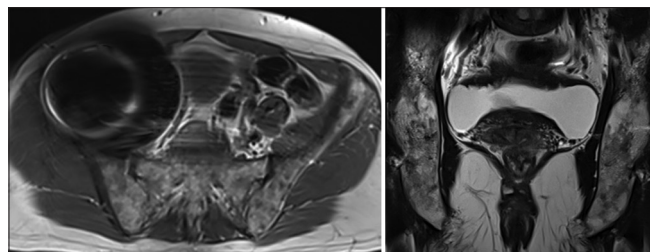


Figure 2: Transaxial T1-weighted and coronal T2-weighted magnetic resonance imaging images show numerous low signal lesions in the pelvic bones consistent with skeletal metastases

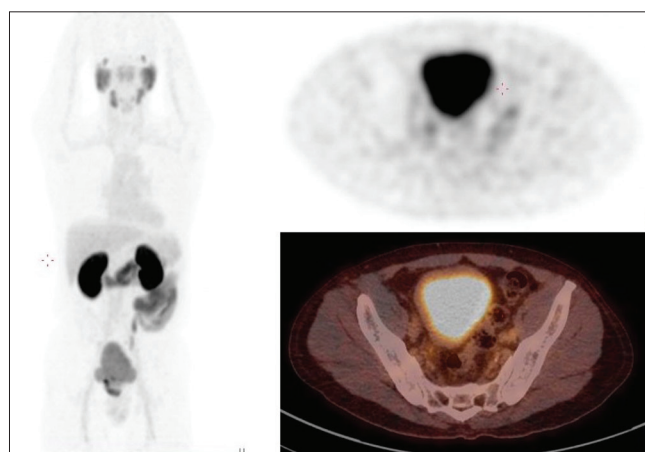


Figure 3: <sup>68</sup>Ga-PSMA PET-CT images show no evidence of skeletal metastasis

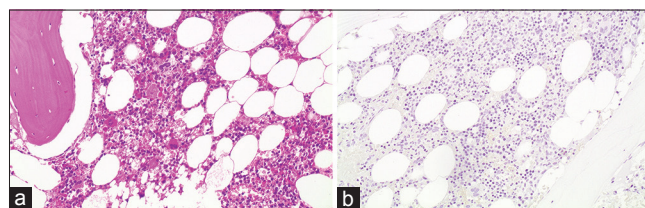


Figure 4: H and E, ×200 objective shows normal marrow (a). Negative AE 1/3 immunohistochemistry (b)

with a negative <sup>68</sup>Ga-PSMA PET-CT. We considered that the patient may have a second malignancy responsible for the bone marrow infiltration which is not <sup>68</sup>Ga-PSMA avid. Pelvic bone biopsy showed normal marrow with no evidence of malignancy.

MRI is more sensitive and specific than <sup>99m</sup>Tc-MDP bone scan for skeletal metastases and patients who have just these two investigations and show skeletal metastases on MRI would be classified as having skeletal metastases irrespective of the bone scan findings.<sup>[10]</sup> If <sup>68</sup>Ga-PSMA PET-CT is done and negative for skeletal metastases in the setting of a positive MRI, a histologic diagnosis may be needed to avoid wrong staging of the patient which will affect the type of treatment offered. This report contributes to the data on the value of <sup>68</sup>Ga-PSMA PET-CT in prostate cancer skeletal metastasis.

#### Declaration of patient consent

The authors certify that they have obtained all appropriate patient consent forms. In the form the patient(s) has/have given his/her/their consent for his/her/their images and other clinical information to be reported in the journal. The patients understand that their names and initials will not be published and due efforts will be made to conceal their identity, but anonymity cannot be guaranteed.

#### Acknowledgment

We would like to acknowledge Dr. Otto, MJ, Department of anatomical pathology for providing the histology slides.

#### Financial support and sponsorship

Nil.

#### Conflicts of interest

There are no conflicts of interest.

#### REFERENCES

1. Thompson I, Thrasher JB, Aus G, Burnett AL, Canby-Hagino ED, Cookson MS, *et al.* Guideline for the management of clinically localized prostate cancer: 2007 update. *J Urol* 2007;177:2106-31.
2. Shen G, Deng H, Hu S, Jia Z. Comparison of choline-PET/CT, MRI, SPECT, and bone scintigraphy in the diagnosis of bone metastases in patients with prostate cancer: A meta-analysis. *Skeletal Radiol* 2014;43:1503-13.
3. Humphrey P, Schuz J. *Cancers of the Male Reproductive Organs: World Cancer Report*. Lyon: World Health Organization; 2014. p. 453-64.
4. Damber JE, Aus G. Prostate cancer. *Lancet* 2008;371:1710-21.
5. Heidenreich A, Aus G, Bolla M, Joniau S, Matveev VB, Schmid HP, *et al.* EAU guidelines on prostate cancer. *Eur Urol* 2008;53:68-80.
6. Sweat SD, Pacelli A, Murphy GP, Bostwick DG. Prostate-specific membrane antigen expression is greatest in prostate adenocarcinoma and lymph node metastases. *Urology* 1998;52:637-40.
7. Hofman MS, Iravani A. Gallium-68 prostate-specific membrane antigen PET imaging. *PET Clin* 2017;12:219-34.
8. Kratochwil C, Afshar-Oromieh A, Kopka K, Haberkorn U, Giesel FL. Current status of prostate-specific membrane antigen targeting in nuclear medicine: Clinical translation of chelator containing prostate-specific membrane antigen ligands into diagnostics and therapy for prostate cancer. *Semin Nucl Med* 2016;46:405-18.
9. Fendler WP, Eiber M, Beheshti M, Bomanji J, Ceci F, Cho S, *et al.* <sup>68</sup>Ga-PSMA PET/CT: Joint EANM and SNMMI procedure guideline for prostate cancer imaging: Version 1.0. *Eur J Nucl Med Mol Imaging* 2017;44:1014-24.
10. Lecouvet FE, Geukens D, Stainier A, Jamar F, Jamart J, d'Othée BJ, *et al.* Magnetic resonance imaging of the axial skeleton for detecting bone metastases in patients with high-risk prostate cancer: Diagnostic and cost-effectiveness and comparison with current detection strategies. *J Clin Oncol* 2007;25:3281-7.