

Case Report

First case on fluorodeoxyglucose positron emission tomography/computerized tomography of a distant skip metastases to parotid node from esophageal adenocarcinoma

ABSTRACT

We are presenting the first case of a gastro-oesophageal junction adenocarcinoma with metastasis only to the intraparotid lymph node simulating Warthin's tumor. A 66-year-old man underwent an esophagogastroduodenoscopy that found circumferential ulcerated esophageal tumor beginning 40 cm from incisors resulting in stricture and two discrete erosions in the proximal third of esophagus. Biopsies from the stricture have demonstrated a poorly differentiated gastric adenocarcinoma. Computerized tomography (CT) confirmed the site of primary without evidence of distant metastasis. Positron emission tomography/CT showed high uptake in the known carcinoma in distal esophagus involving the gastro-oesophageal junction extending into the cardia of the stomach, the maximum standardized uptake value (SUV_{max}) 7.4. Furthermore, there was a focus of high-grade tracer activity, SUV_{max} 6.2, in the left intraparotid nodule which was initially thought to represent Warthin's tumor rather than metastasis; there was no evidence to suggest metastases elsewhere. Fine needle aspiration and biopsy from the enlarged intraparotid lymph node revealed that the histology was consistent with a poorly differentiated adenocarcinoma, metastasis from upper gastrointestinal tract.

Keywords: ^{18}F -fluorodeoxyglucose positron emission tomography/computerized tomography, gastro-oesophageal cancer, metastasis

INTRODUCTION

Gastric cancer is the fourth most commonly diagnosed cancer and the second most common cause of cancer-related death worldwide,^[1,2] and the prognosis of advanced gastric cancer remains poor. Adenocarcinomas arising from gastric epithelium are the most common malignancies of the stomach (90% of cases). The lymphatic drainage from the stomach is anatomically complex and hard to predict the pattern of lymph node metastases from gastric cancer. However, there are lymph node station metastases that are more frequently observed depending on the tumor location.^[3] Furthermore, the incidence of the regional nodal metastases depends on the location of the tumor and its depth of gastric wall invasion. The presence of lymph node metastases is related with a reduction of the 5-year survival rate, despite the integration of adjuvant therapy to the surgery.


CASE REPORT

A 66-year-old gentleman presented with a history of dysphagia for several months. Staging investigations confirmed a poorly differentiated adenocarcinoma involving the gastro-oesophageal junction and extending into the cardia of the stomach. ^{18}F -fluorodeoxyglucose

**VINCENZO MILITANO¹, SIVAKUMAR MUTHU¹,
NAHEED FAROOQ², RAKESH SAJJAN¹**

Departments of ¹Nuclear Medicine and ²General Surgery, Central Manchester University Hospitals NHS Foundation Trust, Manchester, United Kingdom

Address for correspondence: Dr. Vincenzo Militano, Department of Nuclear Medicine, Central Manchester University Hospitals NHS Foundation Trust, Oxford Road, Manchester, M13 9WL, United Kingdom.
E-mail: vinmilitano@gmail.com

Access this article online	
Website: www.wjnm.org	Quick Response Code 
DOI: 10.4103/wjnm.WJNM_82_17	

This is an open access journal, and articles are distributed under the terms of the Creative Commons Attribution-NonCommercial-ShareAlike 4.0 License, which allows others to remix, tweak, and build upon the work non-commercially, as long as appropriate credit is given and the new creations are licensed under the identical terms.

For reprints contact: reprints@medknow.com

How to cite this article: Militano V, Muthu S, Farooq N, Sajjan R. First case on fluorodeoxyglucose positron emission tomography/computerized tomography of a distant skip metastases to parotid node from esophageal adenocarcinoma. World J Nucl Med 2018;17:302-4.

positron emission tomography/computerized tomography (¹⁸F-FDG PET/CT) showed high uptake within the tumor [Figure 1c]. Maximum standardized uptake value (SUV_{max}) was 7.4. Focal activity was noted in the right mandible which was dental in origin [Figure 1b]. There was also a focus of high FDG activity (SUV_{max} 6.2) in the left intraparotid nodule. This was initially thought to represent a Warthin's tumor [Figure 1a]. Ultrasound-guided biopsy was performed to confirm the diagnosis; however, the histology was consistent with a poorly differentiated adenocarcinoma metastasizing from the upper gastrointestinal tract. Adenocarcinoma of esophagus usually metastasizes to intra-abdominal sites while squamous cell carcinoma to intrathoracic sites.^[4] Skipped metastasis can be observed in 60% of early esophageal cancer.^[5] The intraparotid lymph node metastases are frequent from head and neck cancers. However, metastasis from a distant primary is uncommon and usually arises from lung, kidney, and breast.^[6] Only a single case has been reported of gastric carcinoma with cervical lymph node metastases bypassing the Virchow's node^[7] as a parotid metastasis from a squamous cell adenocarcinoma^[8] and a parotid recurrence of disease, after surgery, in a gastric adenocarcinoma.^[9] We are presenting the first case of lower esophageal carcinoma with metastasis only to the intraparotid lymph node simulating Warthin's tumor. Unfortunately, the presence of cervical or supraclavicular lymph nodes indicates Stage IV disease, which is associated with 5-year survival of 4%.^[10]

DISCUSSION

The abdominal cancer, like gastric cancer, could skip mediastinal lymph nodes due to the lymphatic drainage

from the thoracic duct. The Virchow's node is the left supraclavicular node on the left side of the neck where the lymphatic drainage of most of the body (from the thoracic duct) enters the venous circulation through the left subclavian vein. The metastasis blocks the thoracic duct leading to regurgitation into the surrounding nodes. In that case, probably for some morphological variation, the metastasis skips the Virchow's node and goes to the intraparotid node. Parotid gland metastases can, also, be best explained by the paravertebral plexus hematogenous route. Tumor cells might have traveled through the Batson plexus which is postulated as a direct path to the head and neck region whereby the liver and lungs are bypassed.

CONCLUSION

This is a very rare finding and is the first time that a single parotid metastasis from an esophageal adenocarcinoma has been demonstrated with ¹⁸F-FDG PET/CT.

Declaration of patient consent

The authors certify that they have obtained all appropriate patient consent forms. In the form the patient(s) has/have given his/her/their consent for his/her/their images and other clinical information to be reported in the journal. The patients understand that their names and initials will not be published and due efforts will be made to conceal their identity, but anonymity cannot be guaranteed.

Financial support and sponsorship

Nil.

Conflicts of interest

There are no conflicts of interest.

REFERENCES

1. Parkin DM. International variation. *Oncogene* 2004;23:6329-40.
2. Ferlay J, Shin HR, Bray F, Forman D, Mathers C, Parkin DM, *et al.* Estimates of worldwide burden of cancer in 2008: GLOBOCAN 2008. *Int J Cancer* 2010;127:2893-917.
3. Rosa F, Costamagna G, Doglietto GB, Alfieri S. Classification of nodal stations in gastric cancer. *Transl Gastroenterol Hepatol* 2017;2:2.
4. Cho JW, Choi SC, Jang JY, Shin SK, Choi KD, Lee JH, *et al.* Lymph node metastases in esophageal carcinoma: An endoscopist's view. *Clin Endosc* 2014;47:523-9.
5. Sgourakis G, Gockel I, Lyros O, Hansen T, Mildnerberger P, Lang H, *et al.* Detection of lymph node metastases in esophageal cancer. *Expert Rev Anticancer Ther* 2011;11:601-12.
6. Shimoyama T, Horie N, Yamada T, Ide F. Parotid lymph node metastasis from adenocarcinoma of the urachus. *Dentomaxillofac Radiol* 2000;29:185-8.
7. Takashima T, Nakata B, Hatama M, Nomura S, Komoto M, Ishikawa T, *et al.* Gastric cancer with cervical lymph node metastasis as the first

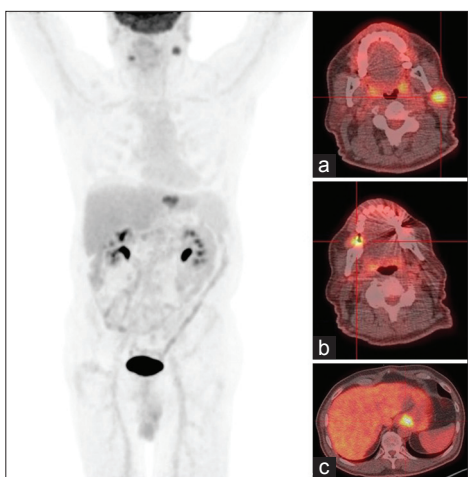


Figure 1: Maximum intensity projection with (a) intraparotid lymph node metastasis, (b) dental uptake, (c) primary esophagogastric lesion

- presentation: Report of a case. *Int Surg* 2008;93:295-9.
8. Hsieh TC, Wu YC, Sun SS, Yang CF, Kao CH. Parotid gland metastasis from squamous cell carcinoma of esophagus detected by FDG PET/CT. *Clin Nucl Med* 2012;37:1001-2.
 9. Schoneveld JM, Hesp WL, Teune TM. Parotid metastasis from a gastroesophageal carcinoma: Report of a case. *Dig Surg* 2007;24:68-9.
 10. Howlader N, Noone AM, Krapcho M, Miller D, Bishop K, Altekruse SF, *et al.* SEER Cancer Statistics Review, 1975–2008. Bethesda, MD: National Cancer Institute; 2011.