

Case Report

A case of dermatopathic lymphadenitis mimicking lymphoma on ^{18}F -fluorodeoxyglucose positron emission tomography/computed tomography imaging

ABSTRACT

This case report illustrates a rare case of dermatopathic lymphadenitis with interval ^{18}F -fluorodeoxyglucose positron emission tomography/computed tomography performed. The clinical presentation, imaging, and histological findings are described. We discuss the diagnostic challenges in this case.

Keywords: ^{18}F -fluorodeoxyglucose positron emission tomography/computed tomography, dermatopathic lymphadenitis, lymphoma, psoriasis

INTRODUCTION

Dermatopathic lymphadenitis (DL) is a distinctive entity of benign lymphoid hyperplasia associated with a variety of chronic skin diseases including pemphigus, psoriasis, eczema, neurodermatitis, and atrophia senilis.^[1] It is postulated to represent exaggerated immune response to persistent antigenic stimulation in the skin.^[2]

DL can cause a diagnostic challenge as the clinical and imaging findings mimic lymphoma.^[3] Caution should always be exercised in interpreting the image findings and taking into account the clinical context, in order to arrive at an appropriate diagnosis.

CASE REPORT

A 50-year-old Chinese female with a history of psoriasis and psoriatic arthritis over 10 years presented with rapidly enlarging multiple lymphadenopathies at the bilateral neck and groin regions for 1 month. She had no constitutional symptoms such as fever, night sweat, or weight loss. There was a family history of lymphoma in her mother and maternal aunt. On physical examination, the lymph nodes appeared nontender and

mobile and approximately 2 cm in size at the right groin. Blood tests including complete blood count, peripheral blood smear examination, and lactic dehydrogenase level were normal. The management of psoriasis was suboptimal with frequent flares and multiple joint deformities in the finger joints. The patient was only on topical steroids and nonsteroidal anti-inflammatory drugs (diclofenac) as she refused the use of disease-modifying agents such as methotrexate due to fear of side effects. The patient had not been put on any systemic immunosuppressant.

The patient was referred to gynecologist to look for gynecological malignancy as a possible explanation of the groin lymph nodes. The patient had regular menstrual cycles.

KOON KIU NG, YAN HO HUI, BOOM TING KUNG, TING KUN AU YONG

Nuclear Medicine Unit and Clinical PET Centre, Queen Elizabeth Hospital, Yau Ma Tei, Hong Kong

Address for correspondence: Dr. Koon Kiu Ng, Nuclear Medicine Unit, Lower Ground, Block K, Queen Elizabeth Hospital, 30 Gascoigne Road, Kowloon, Hong Kong.
E-mail: nkk667@ha.org.hk


Submitted: 05-Jun-2020, **Revised:** 21-Jul-2020,

Accepted: 22-Jul-2020, **Published:** 14-Sep-2020

This is an open access journal, and articles are distributed under the terms of the Creative Commons Attribution-NonCommercial-ShareAlike 4.0 License, which allows others to remix, tweak, and build upon the work non-commercially, as long as appropriate credit is given and the new creations are licensed under the identical terms.

For reprints contact: WKHLRPMedknow_reprints@wolterskluwer.com

How to cite this article: Ng KK, Hui YH, Kung BT, Au Yong TK. A case of dermatopathic lymphadenitis mimicking lymphoma on ^{18}F -fluorodeoxyglucose positron emission tomography/computed tomography imaging. World J Nucl Med 2021;20:205-7.

Access this article online	
Website: www.wjnm.org	Quick Response Code 
DOI: 10.4103/wjnm.WJNM_78_20	

Pelvic ultrasound did not reveal any significant findings in the gynecological organs. Fine-needle aspiration of the right groin node was performed and showed no evidence of granulomatous inflammation or metastatic malignancy. Finally, the patient was referred for ^{18}F -fluorodeoxyglucose positron emission tomography/computed tomography (^{18}F -FDG PET/CT) [Figure 1a], which showed enlarged markedly hypermetabolic lymphadenopathies in the bilateral cervical, bilateral axillary, right intramammary, intra-abdominal, and pelvic nodal basin [Figures 2 and 3]. The most FDG-avid right inguinal node measured SUV_{max} 20.1 and 25 mm \times 18 mm in size. There was also diffuse splenic hypermetabolism (SUV_{max} 5.7). Based on the image findings, differential diagnoses of benign or malignant lymphoproliferative disorders were given in the ^{18}F -FDG PET/CT report.

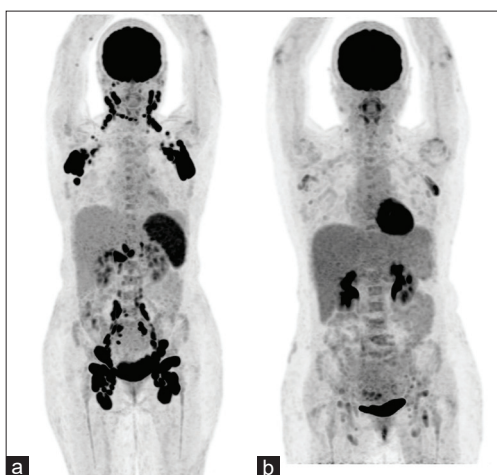


Figure 1: Comparison of the maximum intensity projection images of successive ^{18}F -fluorodeoxyglucose positron emission tomography/computed tomography performed three months apart. The first ^{18}F -fluorodeoxyglucose positron emission tomography/computed tomography (a) showed markedly fluorodeoxyglucose-avid bilateral cervical, bilateral axillary, abdominal, and pelvic (porta hepatis, paraaortic, paracaval, bilateral iliac and inguinal) lymphadenopathies. The second ^{18}F -fluorodeoxyglucose positron emission tomography/computed tomography (b) performed three months later showed interval metabolic improvement of the extensive lymphadenopathies

Excisional biopsy of the right groin lymph node was performed and showed reactive follicular hyperplasia with dermatopathic changes, giving the diagnosis of DL [Figure 4]. Immunohistochemical staining showed no evidence of lymphoma. The patient was monitored clinically. A follow-up ^{18}F -FDG PET/CT in 3 months' interval [Figure 1b] showed interval metabolic improvement of the lymph nodes, concurring with the benign disease nature.

DISCUSSION

In DL, axillary and inguinal nodes are most commonly affected, but other lymph node groups have also been reported, for example, intramammary node as in this case.^[4] The intramammary node appearance as a markedly FDG-avid breast nodule in ^{18}F -FDG PET/CT was of concern to the clinician in that biopsy was performed for exclusion of breast malignancy. Garces *et al.* reported a cohort of 42 patients with DL, where axillary and ipsilateral intramammary node involvement was detected in 7% of cases.^[4] This should be taken into consideration with suspected DL to avoid invasive investigation with potential harm to the patient.

The clinical features of progressively enlarging multiple lymph nodes, as well as PET/CT findings of hypermetabolic supradiaphragmatic and infradiaphragmatic lymphadenopathies, can be alarming and mimic lymphoma. In this reported case, the positive family history of lymphoma and medical history of autoimmune disorder are known risk factors for lymphoma.^[5] These caused diagnostic challenges to the clinician. Of note, in relation to the history of psoriasis, use of methotrexate would have been relevant as methotrexate-associated lymphoproliferative disorder has been reported and can show similar ^{18}F -FDG PET/CT findings of multiple hypermetabolic lymphadenopathies.^[6]

^{18}F -FDG PET/CT demonstrated its role in evaluating the lymph node distribution and guiding biopsy of the most

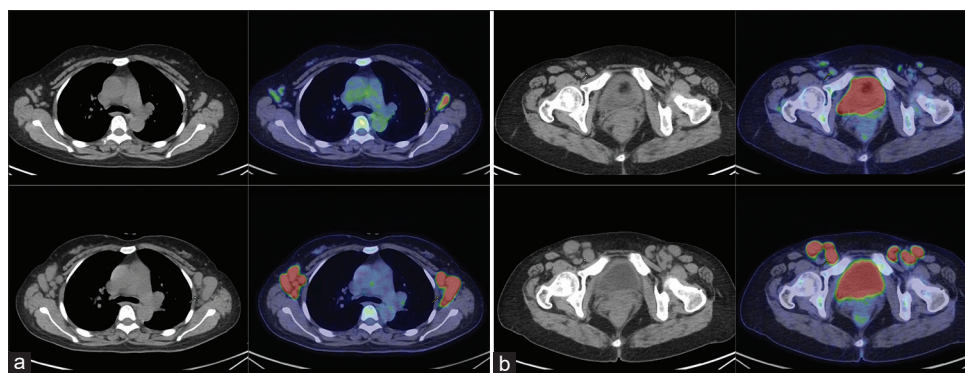


Figure 2: Transaxial computed tomography and positron emission tomography/computed tomography images showed the enlarged bilateral axillary (a) and inguinal (b) nodes in the first ^{18}F -fluorodeoxyglucose positron emission tomography/computed tomography

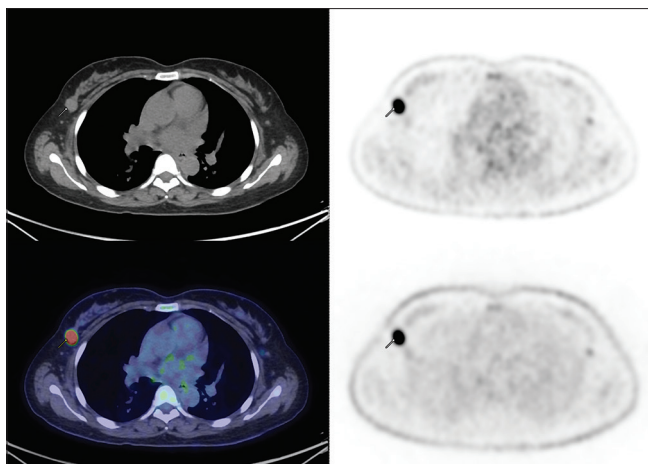


Figure 3: A hypermetabolic circumscribed oval nodule (SUV_{max} 14.9, 16 mm) at the upper outer quadrant of the right breast was detected, which raised concern for breast malignancy. Biopsy was performed and showed lymphoid hyperplasia with the presence of melanin, confirming a right intramammary node with features of dermatopathic lymphadenitis

metabolically active lymph node. Lymph node biopsy was essential in establishing the diagnosis of DL and differentiating from other benign lymphoproliferative disorders and lymphoma. ¹⁸F-FDG PET/CT was also useful for disease monitoring as the follow-up PET/CT in this case illustrated spontaneous improvement of the generalized hypermetabolic lymphadenopathies without active treatment, affirming the benign disease nature. In patients with generalized hypermetabolic lymphadenopathies, in particular with a history of chronic dermatopathy, the differential diagnosis of dermatopathic lymphadenitis should be kept in mind.

Declaration of patient consent

The authors certify that they have obtained all appropriate patient consent forms. In the form, the legal guardian has given his consent for images and other clinical information to be reported in the journal. The guardian understands that names and initials will not be published and due efforts will be made to conceal identity, but anonymity cannot be guaranteed.

Acknowledgment

The author would like to thank Dr. K L Liu, Department

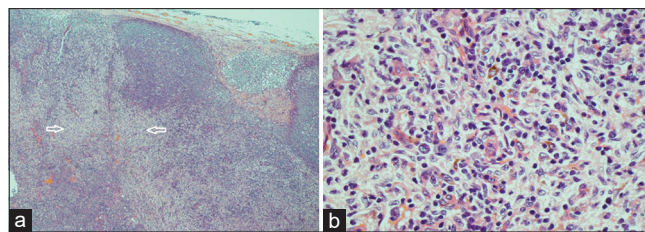


Figure 4: Histopathological images showed characteristic findings of dermatopathic lymphadenitis (a) paracortical expansion of the lymph nodes (pale areas indicated by white arrows) with increased interdigitating dendritic cells, Langerhans cells, and histiocytes containing melanin pigments. (b) High-power magnification showed the presence of melanin pigment (H and E, original magnification a, original magnification, $\times 100$; b, original magnification, $\times 200$)

of Pathology, Tuen Mun Hospital, and Dr. W Cheuk, Department of Pathology, Queen Elizabeth Hospital for their contribution of the histological slides and comments.

Financial support and sponsorship

Nil.

Conflicts of interest

There are no conflicts of interest.

REFERENCES

1. Good DJ, Gascoyne RD. Atypical lymphoid hyperplasia mimicking lymphoma. *Hematol Oncol Clin North Am* 2009;23:729-45.
2. Miranda RN, Khoury JD, Medeiros LJ. Dermatopathic Lymphadenopathy. *Atlas of Lymph Node Pathology*. New York, NY: Springer New York; 2013. p. 129-31.
3. Makis W, Hickeson M, Blumenkrantz M. Interesting image. Dermatopathic lymphadenitis: A pitfall for lymphoma evaluation by F-18 FDG PET/CT. *Clin Nucl Med* 2010;35:872-4.
4. Garces S, Yin CC, Miranda RN, Patel KP, Li S, Xu J, et al. Clinical, histopathologic, and immunoarchitectural features of dermatopathic lymphadenopathy: An update. *Mod Pathol* 2020;33:1104-21.
5. Vaengebjerger S, Skov L, Egeberg A, Loft ND. Prevalence, incidence, and risk of cancer in patients with psoriasis and psoriatic arthritis: A systematic review and meta-analysis. *JAMA Dermatol* 2020;156:421-9.
6. Shimizu H, Nishioka H. 18 F-FDG PET-CT in a patient with methotrexate-associated lymphoproliferative disorder. *J Gen Fam Med* 2018;19:34-5.