

Case Report

Hot-clot artifact in the lung parenchyma on ^{18}F -fluorodeoxyglucose positron emission tomography/computed tomography mimicking malignancy with a homolateral non-small cell lung cancer

ABSTRACT

^{18}F -fluorodeoxyglucose (^{18}F -FDG) positron emission tomography/computed tomography (CT) is an important tool widely used in the oncology to stage and restage various malignancies. Intense focal FDG uptake in the lung parenchyma associated with the absence of anatomical lesion detected on CT can be explained by a lung microembolism, known as hot-clot artifact. We report, to the best of our knowledge, the first case describing a single hot-clot artifact located in the same lung as a histologically proven non-small cell lung cancer.

Keywords: ^{18}F -fluorodeoxyglucose, hot-clot artifact, lung cancer, positron emission tomography

INTRODUCTION

^{18}F -fluorodeoxyglucose positron emission tomography/computed tomography (^{18}F -FDG PET/CT) is widely used in the oncology to stage and restage various malignancies. Even if most of the malignant cells show a high metabolic activity, some benign diseases can display FDG uptake, which may lead to false-positive ^{18}F -FDG PET/CT.^[1] Hot-clot artifact, caused by a lung microembolism, is another situation in which ^{18}F -FDG PET may lead to false positivity and inappropriate staging.^[2] Here, we report a case of an intense FDG focal uptake, located in the same lung as a non-small cell lung cancer, shown to be a hot-clot artifact by subsequent rescanning.

CASE REPORT

A 63-year-old man underwent ^{18}F -FDG PET/CT to characterize the metabolism and to stage a lung nodule in the left upper lobe. The study showed an intense hypermetabolism in the known nodule located in the left upper lobe with a maximum standardized uptake value (SUV_{max}) of 16.6 [Figure 1]. Furthermore, there was a focal and intense ^{18}F -FDG

uptake ($\text{SUV}_{\text{max}} = 26.1$) in the superior segment of the left lower lobe [Figure 2a]. The CT images disclosed no lesion at this spot. The scan was repeated 2 weeks later but this time, the ^{18}F -FDG uptake, above defined, was no longer visible [Figure 2b], demonstrating the diagnosis of ^{18}F -FDG hot-clot artifact and eliminating a homolateral lung metastasis. The patient underwent surgery of the hypermetabolic nodule in the left upper lobe by lobectomy, which confirmed the diagnosis of non-small cell lung cancer (adenocarcinoma).

YACINE EL YAAGOUBI, CAROLINE PRUNIER-AESCH, LAURENT PHILIPPE, PHILIPPE LAPLAIGE¹

Department of Nuclear Medicine, NCT+ Clinic, Saint-Cyr-Sur-Loire, ¹Department of Oncology, Blois Polyclinic, La Chaussée-Saint-Victor, France

Address for correspondence: Dr. Yacine El Yaagoubi, Médecine Nucléaire Tourangelle, Nouvelle Clinique Tours Plus, 1 Boulevard Alfred Nobel, 37540 Saint-Cyr-Sur-Loire, France. E-mail: eyacine2@hotmail.com

Submitted: 02-Jun-2020, **Revised:** 29-Jun-2020, **Accepted:** 30-Jun-2020, **Published:** 14-Sep-2020

This is an open access journal, and articles are distributed under the terms of the Creative Commons Attribution-NonCommercial-ShareAlike 4.0 License, which allows others to remix, tweak, and build upon the work non-commercially, as long as appropriate credit is given and the new creations are licensed under the identical terms.

For reprints contact: WKHLRPMedknow_reprints@wolterskluwer.com

How to cite this article: El Yaagoubi Y, Prunier-Aesch C, Philippe L, Laplaige P. Hot-clot artifact in the lung parenchyma on ^{18}F -fluorodeoxyglucose positron emission tomography/computed tomography mimicking malignancy with a homolateral non-small cell lung cancer. World J Nucl Med 2021;20:202-4.


Access this article online	
Website: www.wjnm.org	Quick Response Code 
DOI: 10.4103/wjnm.WJNM_75_20	

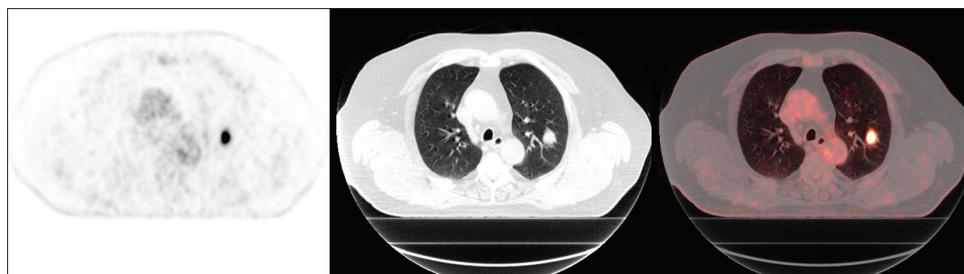

Figure 1: The ¹⁸F-fluorodeoxyglucose positron emission tomography/computed tomography and fusion positron emission tomography/computed tomography axial slices show an intense hypermetabolism in the known nodule located in the left upper lobe with a maximum standardized uptake value of 16.6

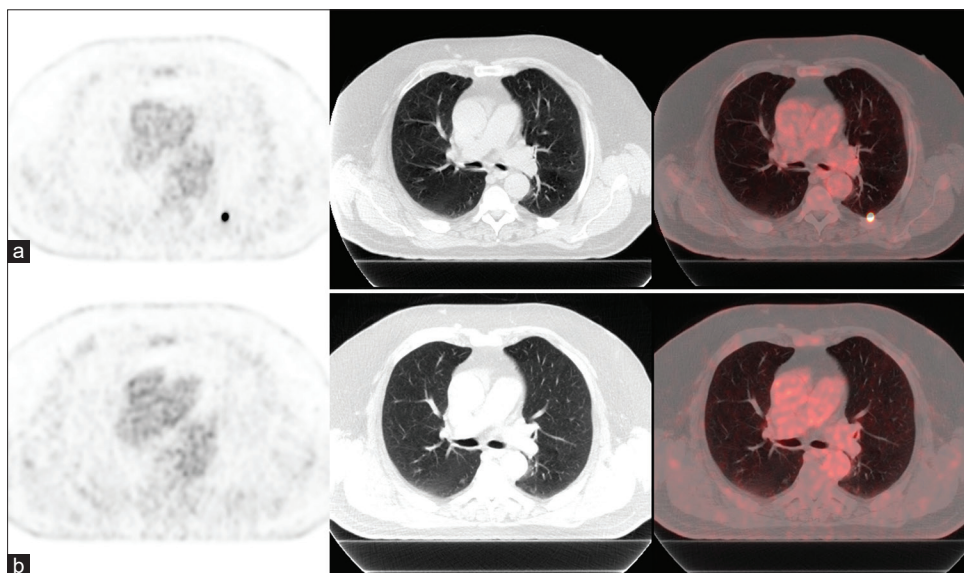


Figure 2: The ¹⁸F-fluorodeoxyglucose positron emission tomography/computed tomography and fusion positron emission tomography/computed tomography axial slices show a focal and intense ¹⁸F-fluorodeoxyglucose uptake ($SUV_{max} = 26.1$) located in the left lower lobe without anatomical alteration on computed tomography (a). The scan was repeated 2 weeks later and focal ¹⁸F-fluorodeoxyglucose uptake was resolved (b)

DISCUSSION

The absence of ¹⁸F-FDG uptake at lesions evident on CT imaging is recurrent and may be related to low FDG affinity or small nodular size (partial-volume effect). However, ¹⁸F-FDG focal uptake without any anatomical correlation on CT is a rare and confusing finding. After excluding a misalignment between PET and CT image planes, focal intense hypermetabolism in the lung with no structural lesion detected on CT should lead to search a ¹⁸F-FDG hot-clot artifact and if necessary, to repeat the study to find a disappearance of the uptake at rescanning.^[3] In the medical literature, only few publications are available regarding a high ¹⁸F-FDG uptake with no structural alteration on CT.^[2,4-6] Our initial thought was that the lesion responsible for the uptake was too small to be detected on CT (<3mm), but the intense ¹⁸F-FDG uptake ($SUV_{max} = 26.1$) led us to reconsider our hypothesis because such a size could not be fully detected by the system which has a spatial resolution of about 6 mm. In all reported cases, there was an intense ¹⁸F-FDG uptake and the ¹⁸F-FDG avid lesions without CT abnormality have showed a complete

resolution in the follow-up exams. The mechanism of ¹⁸F-FDG hot-clot artifact is the formation of a microcoagulation caused by vascular endothelium damage during ¹⁸F-FDG injection, responsible for pulmonary microembolisms. Microemboli happen more frequently during paravenous injection, speed injection, and blood aspiration into the injector.^[7-9] In the present case, the hot-clot artifact, located in left lower lobe, in the same lung as that of the tumor, could have been the cause of a diagnostic error. An exploratory thoracotomy was initially discussed to make a precise staging. This invasive exploration, first, would have been useless because it would not have revealed any other lesion, but, especially, would have delayed the curative surgery. To the best of our knowledge, this is the first case describing a single hot-clot artifact located in the same lung as a histologically proven non-small cell lung cancer.

CONCLUSION

Recognizing ¹⁸F-FDG hot-clot artifacts in ¹⁸F-FDG PET/CT imaging is crucial because an erroneous staging may be

the cause of an inadequate treatment in patients treated for oncological diseases. In case of suspicion of a hot-clot artifact, rescanning may be necessary to avoid false positivity.

Declaration of patient consent

The authors certify that they have obtained all appropriate patient consent forms. In the form, the patient(s) has/have given his/her/their consent for his/her/their images and other clinical information to be reported in the journal. The patients understand that their names and initials will not be published and due efforts will be made to conceal their identity, but anonymity cannot be guaranteed.

Financial support and sponsorship

Nil.

Conflicts of interest

There are no conflicts of interest.

REFERENCES

1. Shreve PD, Anzai Y, Wahl RL. Pitfalls in oncologic diagnosis with FDG PET imaging: Physiologic and benign variants. *Radiographics* 1999;19:61-77.
2. Karantanis D, Subramaniam RM, Mullan BP, Peller PJ, Wiseman GA. Focal F-18 fluoro-deoxyglucose accumulation in the lung parenchyma in the absence of CT abnormality in PET/CT. *J Comput Assist Tomogr* 2007;31:800-5.
3. Hartman T. Pearls and Pitfalls in Thoracic Imaging: Variants and Other Difficult Diagnoses. New York: Cambridge University Press; 2011. p. 198-201.
4. Sanchez-Sanchez R, Rodriguez-Fernandez A, Ramirez-Navarro A, Gomez-Rio M, Ramos-Font C, Llamas-Elvira JM. PET/CT: focal lung uptake of 18F-fluorodeoxyglucose on PET but no structural alterations on CT. *Rev Esp Med Nucl* 2010;29:131-4.
5. Farsad M, Ambrosini V, Nanni C, Castellucci P, Boschi S, Rubello D, *et al.* Focal lung uptake of 18F-fluorodeoxyglucose (18F-FDG) without computed tomography findings. *Nucl Med Commun* 2005;26:827-30.
6. Fathinul Fikri A, Lau W. An intense F-FDG pulmonary microfocus on PET without detectable abnormality on CT: A manifestation of an iatrogenic FDG pulmonary embolus. *Biomed Imaging Interv J* 2010;6:e37.
7. Ha JM, Jeong SY, Seo YS, Kwon SY, Chong A, Oh JR, *et al.* Incidental focal F-18 FDG accumulation in lung parenchyma without abnormal CT findings. *Ann Nucl Med* 2009;23:599-603.
8. Hany TF, Heuberger J, von Schulthess GK. Iatrogenic FDG foci in the lungs: A pitfall of PET image interpretation. *Eur Radiol* 2003;13:2122-7.
9. Ozdemir E, Poyraz NY, Keskin M, Kandemir Z, Turkolmez S. Hot-clot artifacts in the lung parenchyma on F-18 fluorodeoxyglucose positron emission tomography/CT due to faulty injection techniques: Two case reports. *Korean J Radiol* 2014;15:530-3.