

Original Article

Scintigraphic evaluation of colonic transit in children with constipation using ^{67}Ga -citrate

ABSTRACT

The aim of this study was to assess the colonic transit in children and teenagers with chronic constipation. Twenty patients from 1.5 to 16 years old were included (mean age = 6.9 years). Chronic constipation etiologies were as follows: congenital megacolon in 6; surgical treatment in 5 (imperforate anus 2, hip dysplasia 1, sacral teratoma 1, and paraspinal neuroblastoma 1); idiopathic chronic constipation in 5; sacral myelomeningocele in 3; and intestinal duplication in 1. Static images on the anterior projection of the abdomen were performed 1, 6, 24, 48, and 72 h after the radiotracer oral administration. Doses were 3.7 MBq of ^{67}Ga -citrate. The images were visually analyzed and classified by the observers as normal, diffuse slow transit, right slow transit, and left slow transit. Patients' dosimetric estimation was performed also. There were four cases of diffuse slow transit that responded well to the clinical treatment, 3 of them being chronic idiopathic constipation. From five patients with right slow transit, 4 were submitted to appendicostomy (Malone surgery) with good results. There were 11 cases of left slow transit (ten at the rectosigmoid level). Five of the 6 patients with congenital megacolon had left slow transit. Patients' dose estimation was 1.9 mSv to the whole body, 1.8 mSv to the ovaries, and 1.4 mSv to the testicular. This method is simple, safe, noninvasive, provides helpful functional information, and allows therapeutic decision regarding chronic constipation.

Keywords: ^{67}Ga Gallium scintigraphy, chronic constipation, colonic transit

INTRODUCTION

The movements of the gastrointestinal motility are regulated by a complex interplay between hormonal and neuronal stimuli. In the colonic walls, segmental contractions and reverse peristalsis mix promoting absorption. Intermittent propulsive and retropropulsive activities permit storage and mass movement. Scintigraphy can provide an effective and noninvasive method of assessing of gastrointestinal tract disorders.^[1]

Although the colonic transit valuation with ^{67}Ga -citrate has not been used for assessment in Brazil as well as in Europe and the United States of America neither for routine studies, ^{67}Ga is still of value, particularly in services that continues it and places where no positron emission tomography/computed tomography service is available.^[2] Normally, ^{111}In is the radiopharmaceutical of choice for evaluation in measure colonic and gastric empty, but high cost and unreliable availability may preclude regular use.^[3]


Colonic transit measurements have proven useful to confirming or excluding the presence of anatomic or functional abnormalities. Indeed, the test can be used to determine low frequency of bowel movements.^[4]

Gallium is produced by cyclotron and has a half-life of 78.26 h, decaying to stable ^{67}Zn by electron capture. For medical radiology, purposes are provided in the form of a

**JOSÉ ULISSES MANZZINI CALEGARO^{1,2},
JOÃO BATISTA MONTEIRO TAJRA¹, JANAÍNA FRANÇA
DE MAGALHÃES SOUTO², FLÁVIA RIBEIRO MARCIANO²,
DANIELLE CICARINI DE LANDA^{1,2}, SUNG BOON BAE¹,
HÉLIO BUZON FILHO¹**

¹Hospital de Base do Distrito Federal – Nuclear Medicine Service, ²Grupo Núcleos de Medicina Nuclear, Brasília, Brasil

Address for correspondence: Dr. José Ulisses Manzinni Calegare, AOS 6 – BI D- Ap 604 –CEP 70660-064 Brasília, Brazil. E-mail: jum.calegare@gmail.com

Access this article online	
Website: www.wjnm.org	Quick Response Code 
DOI: 10.4103/wjnm.WJNM_75_17	

This is an open access journal, and articles are distributed under the terms of the Creative Commons Attribution-NonCommercial-ShareAlike 4.0 License, which allows others to remix, tweak, and build upon the work non-commercially, as long as appropriate credit is given and the new creations are licensed under the identical terms.

For reprints contact: reprints@medknow.com

How to cite this article: Calegare JU, Tajra JB, Souto JF, Marciano FR, De Landa DC, Bae SB, *et al.* Scintigraphic evaluation of colonic transit in children with constipation using ^{67}Ga -citrate. World J Nucl Med 2018;17:249-52.

sterile solution of gallium citrate. The human body reacts to ⁶⁷Ga similarly to the way that it handles ferric iron, bind to transferrin glycoproteins, leukocyte lactoferrin, and inflammatory proteins if injected. When used orally, the gut does not absorb it.^[5]

The aim of this study was to evaluation the transit colonic with ⁶⁷Ga-citrate in a sample of children and teenagers with constipation in Hospital de Base do Distrito Federal, Brasília, Brazil. The Human Ethics Committee of Hospital de Base do Distrito Federal, Brasília, Brazil, approved the study.

MATERIALS AND METHODS

Subjects and data acquisition

Twenty patients with constipation were studied. The average age was 7.45 years for ten male patients and 9.5 years for ten female patients (range 1.5–15 year). The many diseases were congenital forms or showed up in the 1st year of life [Figure 1].

The participants were underwent colonic transit studies with ⁶⁷gallium citrate (100 uCi - 3.7 MBq) after oral ingestion with 100 ml of juice. The fasting for any foods was 3 h before the procedure. The ⁶⁷gallium was provided by Instituto de Pesquisas Energéticas, São Paulo, Brasil. The radionuclide protocols were performed in 1, 6, 12, 24, 48, and 72 h after oral ingestion of radiotracer. Rarely, were made late images (96, 120 h).

We used static pictures in predefined times, with 300.000 count each, in anterior abdomen projection using a gamma-camera with wide field of vision, medium-energy collimator, and 20% window centered in 92, 185, and 300 Kev photopeaks. The external anatomy landmarks for scanning were xiphoid appendix as superior measure and umbilical region in inferior measure. For this analysis, only qualitative pictures were recorded. In all participants, scan results measured were described in four behavior patterns: (1) normal intestinal transit patterns (intestinal excretory activity in 24 h), (2) diffuse intestinal stasis patterns (intestinal excretory activity in 3 days without segment stasis), (3) right

intestinal stasis patterns (intestinal excretory activity in segment bowel right until 3 days), and (4) left intestinal stasis patterns (intestinal excretory activity in segment bowel left until 3 days); this measured according to the method described by Notghi *et al.*^[6]

Radiation-absorbed dose

Radiation-absorbed doses were calculated based on published oral radiotracer for whole human body and gonads for MIRD system of the Society of Nuclear Medicine and others.^[7,8]

The static pictures were performed in anterior incidence because it is a child population (lower abdominal thickness) and was adopted the visual scale for purpose of this study although analogic picture studies were more accurate.^[9]

RESULTS

Studies were well tolerated in all participants and clear images were obtained. ⁶⁷Gallium-citrate measurement of gastric emptying was performed without gastroparesis in the 1st h. The scanning of lower right quadrant abdominal images was then obtained in 6 h on ileocecal valve. This time showed the oral-cecal transit.

The colonic transit shows right stasis in five cases [Figure 3], left stasis in ten cases [Figure 4] and diffuse stasis in five cases in this study [Figure 2]. The analysis forms were confirmed by visual inspection of images.

Constipated patients

The patients with idiopathic constipation showed two patterns: Diffuse stasis in four cases and left stasis in two cases. All the participants were treated with clinical procedures.

Congenital megacolon patients

The patients with congenital megacolon recorded segmental retention of ⁶⁷gallium in the left side (descending colon

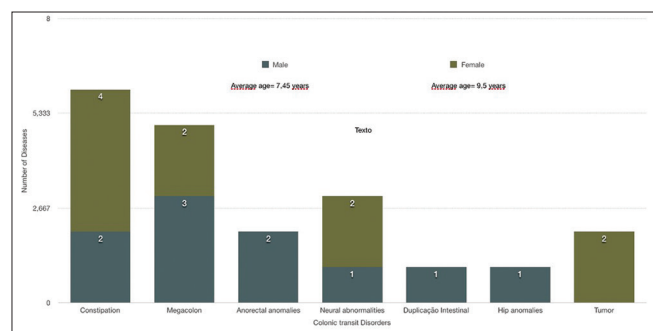


Figure 1: Colonic transit study disorders with ⁶⁷Ga-citrate scintigraphy

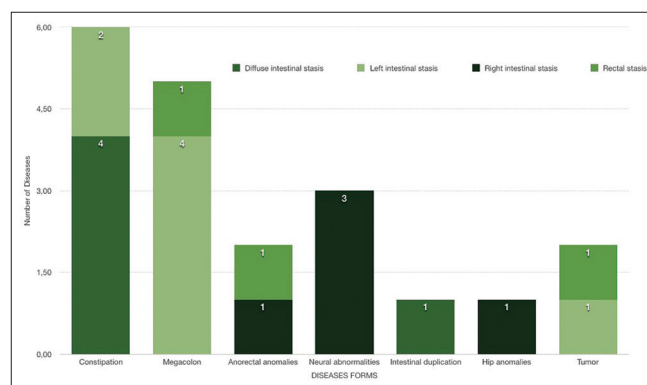


Figure 2: Colonic transit results for disease forms and intestinal stasis

and rectum). These cases were treated with surgical procedures.

Appendicostomy (Malone procedure)

From five patients with segmental retention in the right side, four performed the Malone procedure. The operation consists of connecting the appendix to the umbilicus and creating a valve mechanism that allows catheterization.^[10]

Tumor and abnormalities

Two patients with segmental retention in the left side were diagnosed with sympathetic neuroblastoma and sacrococcygeal teratoma treated for surgical procedure [Figure 5]. Another case with retention in the left side was imperforate anus.

Radiation dosimetry

The calculated total effective dose ⁶⁷Ga-citrate for whole body was 2.9 mSv. The irradiation to gonads was estimated in 1.8 mSv for ovaries and 1.4 mSv for testicles.

DISCUSSION

In Brazil, the assessment of colonic transit has been realized for ^{99m}Tc-pertechnetate in the routine; however, his short half-life (6 h) prevents longer studies.^[11] ⁶⁷Gallium-citrate has an improvement in this studies with a sufficiently half-life (78 h), no binding to the gut wall, low level of adsorption, good biologic stable form, and orocecal transit average in 6 h both in normal participants and constipated patients.^[12] Furthermore, the irradiation levels for the whole body and gonads were as low as two abdominal X-rays. In Europe and the United States of America, ¹¹¹indium Ligand DTPA has been used routinely for your good half-life (72 h), good biologic stable besides regular production in this region.^[10] In our country, ¹¹¹In-DPTA is less available, more expensive and needs manipulation in its preparation. Gallium and indium possess similar chemical properties and can be used in its liquid form in esophageal transit, gastric emptying studies, reflux esophageal, small bowel, and colonic transit studies; therefore, it is a common and readily available radiopharmaceutical in nuclear medicine departments.^[5,13]

In this study, we report twenty cases of chronic refractory constipation that may be referred for surgery based on this symptom. The aim was objective confirmation of disturbed colonic transit with such invasive measures and low cost. The scintigraphic study demonstrated a very important differentiation for surgical cases with five patients in congenital megacolon (left intestinal stasis), four patients for Malone procedure (right intestinal stasis), two patients with tumor, and one imperforate anus (60%). In the clinical cases

of idiopathic constipation, 20% showed diffuse intestinal stasis, been therefore, the most common presentation form.

CONCLUSION

The scintigraphic ⁶⁷Ga-citrate study of colonic transit in children is an alternative marker in nuclear medicine. The liquid form is safe, simple, noninvasive and allows functional

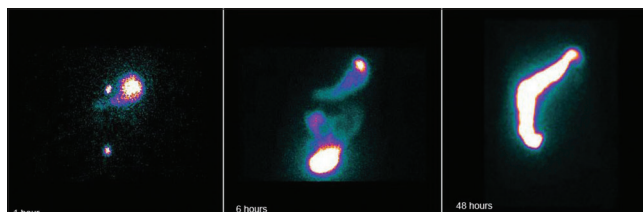


Figure 3: Example of right stasis (ascending and transverse colon)

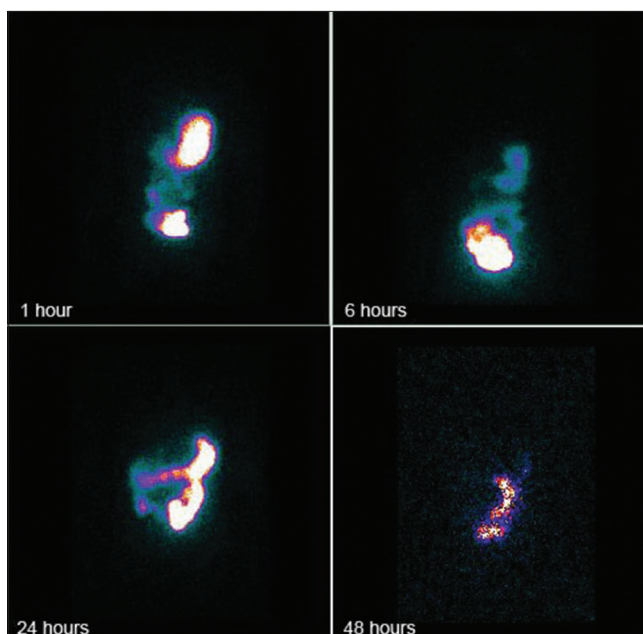


Figure 4: Typical left stasis (rectal ampulla)

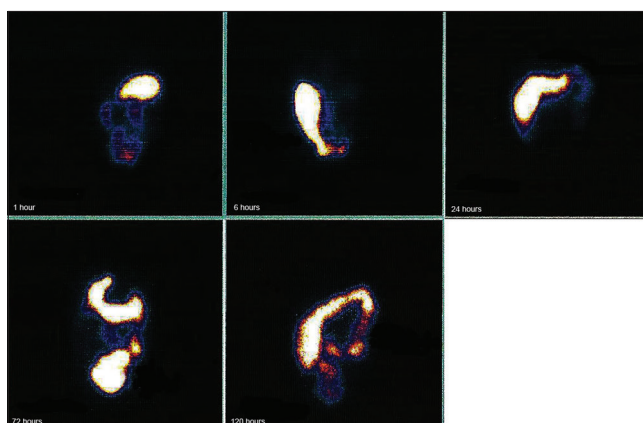


Figure 5: Retrograde transit: The ⁶⁷Ga-citrate was come back for ascending colon (120 h image) after evacuation

studies. Chronic constipated patients showed a good option in differentiating surgical cases. Furthermore, it is an economical and readily available marker for assessment of colonic transit.

Acknowledgments

The authors would like to thank the Fundação de Amparo à Pesquisa do Distrito Federal for the financial support given to the study.

Financial support and sponsorship

Nil.

Conflicts of interest

There are no conflicts of interest.

REFERENCES

1. Szarka LA, Camilleri M. Methods for the assessment of small-bowel and colonic transit. *Semin Nucl Med* 2012;42:113-23.
2. Al-Suqri B, Al-Bulushi N. Gallium-67 scintigraphy in the era of positron emission tomography and computed tomography: Tertiary centre experience. *Sultan Qaboos Univ Med J* 2015;15:e338-43.
3. Cheng KY, Tsai SC, Lin WY. Gallium-67 activated charcoal: A new method for preparation of radioactive capsules for colonic transit study. *Eur J Nucl Med Mol Imaging* 2003;30:907-11.
4. Asli IN, Ehsani MJ, Javadi H, Semnani S, Tabib SM, Assadi M, *et al.* Comparison of three with six regions of interest analyses in patients with idiopathic constipation undertaking colon transit scintigraphy using ⁶⁷Ga-citrate. *Eur Rev Med Pharmacol Sci* 2013;17:69-74.
5. Bellen JC, Chatterton BE, Penglis S, Tsopelas C. Gallium-67 complexes as radioactive markers to assess gastric and colonic transit. *J Nucl Med* 1995;36:513-7.
6. Notghi A, Hutchinson R, Kumar D, Tulley N, Harding LK. Use of geometric center and parametric images in scintigraphic colonic transit studies. *Gastroenterology* 1994;107:1270-7.
7. Mird-dose estimate report no 2. Summary of current radiation dose estimates to humans from ⁶⁶Ga-, ⁶⁸Ga-, and ⁷²Ga-citrate. *J Nucl Med* 1973;14:755-6.
8. Siegel JA, Wu RK, Knight LC, Zelac RE, Stern HS, Malmud LS, *et al.* Radiation dose estimates for oral agents used in upper gastrointestinal disease. *J Nucl Med* 1983;24:835-7.
9. Freedman PN, Goldberg PA, Fataar AB, Mann MM. A comparison of methods of assessment of scintigraphic colon transit. *J Nucl Med Technol* 2006;34:76-81.
10. Wilcox DT, Kiely EM. The Malone (antegrade colonic enema) procedure: Early experience. *J Pediatr Surg* 1998;33:204-6.
11. Carmo RL, Ribeiro AE, Lima MC, Etchebehere EC, Santos AD, *et al.* Estudo cintilográfico funcional de motilidade colônica em crianças com constipação refratária. *Alasbimn J* 2010;13:50.
12. Bartholomeusz D, Chatterton BE, Bellen JC, Gaffney R, Hunter A. Segmental colonic transit after oral ⁶⁷Ga-citrate in healthy subjects and those with chronic idiopathic constipation. *J Nucl Med* 1999;40:277-82.
13. Heyman S. Pediatric gastrointestinal motility studies. *Semin Nucl Med* 1995;25:339-47.