

Case Report

Fibromatosis with aggressive demeanor: Benign impersonator of malignancy

ABSTRACT

Fibromatosis or desmoid fibromatosis is a rare benign neoplasm and develops commonly in the abdominal wall, abdominal cavity, or extra-abdominal sites. The mainstay of treatment is surgery. Chemotherapy and radiotherapy are preferred in cases of inoperable/relapse or a multifocal disease. Hereby, we report a case of fibromatosis arising in the left popliteal fossa, proven by histopathology and immunohistochemistry. Local excision of the mass was performed. The patient was asymptomatic for 6 months, after which she complained of difficulty in walking. Clinical evaluation elicited recurrence in the surgical bed. In spite of the surgical excision with tumor-free margins, recurrence was seen within a span of 6 months. ¹⁸F-fluorodeoxyglucose (FDG) positron emission tomography-computed tomography (PET/CT) was done to rule out multifocal disease and to define the extent of relapse. Although magnetic resonance imaging provides an excellent soft-tissue resolution to delineate the disease, ¹⁸F-FDG PET/CT is an important and supplementary tool which aids in the management of fibromatosis.

Keywords: Desmoid tumor, fibromatosis, fluorodeoxyglucose positron emission tomography-computed tomography in fibromatosis, recurrent fibromatosis

INTRODUCTION

Desmoid fibromatosis is a rare benign neoplasm accounting for 3% of all soft-tissue tumors. Among extra-abdominal sites, the most common locations are the shoulder, followed by the chest wall, back, thigh, and head and neck. There is a proliferation of well-differentiated mesenchymal fibroblasts.^[1] Despite lacking metastatic potential, the tumor has a tendency to invade into the adjacent structures and the recurrence rates are high. Magnetic resonance imaging (MRI) and positron emission tomography-computed tomography (PET/CT) help in the localization of disease, but the penultimate diagnosis is given by the histopathology and immunohistochemistry.

CASE REPORT

A 13-year-old female child presented with the complaints of pain associated with swelling in the left popliteal region for 6 months, which gradually increased in size. There was no history of major trauma and no significant family history. MRI of the left knee joint was done, which showed a lobulated

mass in the posterior aspect of the left knee joint extending into the calf [Figure 1]. Biopsy of the lesion was suggestive of fibromatosis, confirmed by immunohistochemistry, which was positive for beta-catenin, smooth muscle actin, and vimentin and negative for S100 and desmin. The mass was excised, and histopathology confirmed as fibromatosis. It was an R0 resection with margins free of tumor.

She recovered well and was asymptomatic for 6 months, after which she presented with pain in the surgical bed while

**J. NAVEEN KUMAR, M. INDIRANI,
NIKITA SAMPATHIRAO, S. SHELLEY**

Department of Nuclear Medicine and PET CT, Apollo Hospitals, Chennai, Tamil Nadu, India

Address for correspondence: Dr. J. Naveen Kumar, Department of Nuclear Medicine, 21 Greams Lane, Off Greams Road, Chennai - 600 006, Tamil Nadu, India.
E-mail: jnaveen.nk@gmail.com


Submission: 17-Apr-2020
Accepted: 23-Aug-2020

Revised: 20-Aug-2020
Published: 12-Dec-2020

This is an open access journal, and articles are distributed under the terms of the Creative Commons Attribution-NonCommercial-ShareAlike 4.0 License, which allows others to remix, tweak, and build upon the work non-commercially, as long as appropriate credit is given and the new creations are licensed under the identical terms.

For reprints contact: WKHLRPMedknow_reprints@wolterskluwer.com

How to cite this article: Kumar JN, Indirani M, Sampathirao N, Shelley S. Fibromatosis with aggressive demeanor: Benign impersonator of malignancy. World J Nucl Med 2021;20:121-4.

Access this article online	
Website: www.wjnm.org	Quick Response Code 
DOI: 10.4103/wjnm.WJNM_55_20	

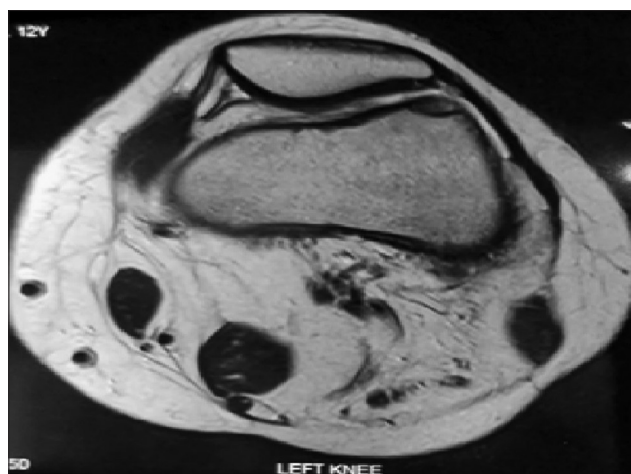


Figure 1: Magnetic resonance imaging of the left knee (presurgery) showing a large, lobulated, soft-tissue mass in the posterior aspect of the knee joint extending into the calf. The mass is inseparable from the medial head of gastrocnemius and popliteus muscle and is heterogeneously hyperintense on T2-weighted images. Popliteal vessels are displaced and are encased

walking. MRI of the left knee was done, which showed a soft-tissue mass in the popliteal fossa with intra-articular extension and encasing neurovascular bundles and was suggestive of disease recurrence [Figure 2].

She was referred for ¹⁸F-fluorodeoxyglucose (FDG) PET/CT scan to rule out multifocality of the disease. ¹⁸F-FDG PET/CT of the whole body from the skull till the toes was done in the Outpatient Department of Nuclear Medicine, Apollo Hospitals, 60 min postinjection of 5 mCi of ¹⁸F-FDG.

¹⁸F-FDG PET/CT scan showed a low-grade FDG-avid mass measuring 13 cm (craniocaudal) × 6.1 cm (transverse) × 4.4 cms (anteroposterior) in the left popliteal fossa involving the gastrocnemius (medial head and proximal part of the lateral head) and popliteus muscles with minimal intra-articular extension and encasing popliteal vessels with maximum standardized uptake value (SUV_{max}) of 2.9. No evidence of bone erosion was noted. No other focus of metabolically active disease was seen elsewhere [Figures 3-4].

As the recurrent mass was inoperable, the patient was advised for systemic chemotherapy with vinblastine and methotrexate.

DISCUSSION

Desmoid fibromatosis is a rare benign neoplasm. Although the etiology is unknown, some risk factors include a family history of desmoid tumor, pregnancy, use of contraceptives, trauma, genetic mutation, surgery, and familial adenomatous polyposis or Gardner syndrome. Sporadic fibromatosis accounts for 90% and the rest 10%

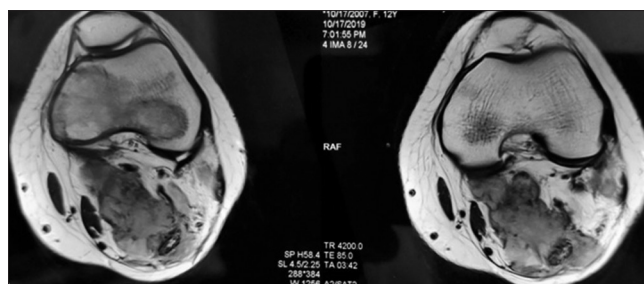


Figure 2: Magnetic resonance imaging of the left knee (postsurgery) showing a recurrent mass with heterogeneously hyperintense on T2-weighted images in the posterior aspect of the knee joint encasing popliteal vessels

are familial.^[1,2] There is a proliferation of well-differentiated mesenchymal fibroblasts in familial cases. Basu *et al.* and Alshaima *et al.* have reported the utility of ¹⁸F-FDG PET/CT in assessing the multifocality and extent of involvement in cases of syndromic fibromatosis.^[3] Despite lacking metastatic potential, the tumor has a tendency to invade into the adjacent structures and the recurrence rates are high.

MRI is a mandatory examination for desmoid tumors. The varying signal intensity and enhancement are due to the varying proportions of spindle cells and collagen of the lesions. On MRI, lesions demonstrate low signal intensity on T1-weighted images and high signal intensity on T2-weighted images. High signal intensity on T2-weighted images reflects increased cellularity, whereas low signal intensity areas correlate with abundant collagen.

¹⁸F-FDG PET/CT has been widely applied for clinical staging. It also helps to confirm the benign nature of tumor and extension. ¹⁸F-FDG uptake ranges from low to moderate and is usually heterogeneous. Areas with more uptake are likely to represent cellularity and high mitotic areas.^[4-6] As fibromatosis is 10% familial, ¹⁸F-FDG PET/CT can help rule out multifocal involvement or cutaneous involvement or intra-/extra-abdominal desmoids and look for colonic polyposis. It should be noted that the SUV values are not high in all malignant tumors and depend on many factors such as blood sugar, body mass index, dose injected, time between injection and scan, and tumor differentiation.

The ultimate diagnosis is confirmed by the histopathological and immunohistochemical examinations. It consists of uniform bundles of spindle cells separated by collagen fibers with positive nuclear beta-catenin staining. Beta-catenin nuclear positivity favors diagnosis, but it is not specific. Nearly 70% of the cases show nuclear expression of beta-catenin, encoded by gene at 3p21 (*CTNNB1*). These tumors also show patchy SMA expression, may show focal S100 protein expression, and is rarely reactive for desmin.^[7]

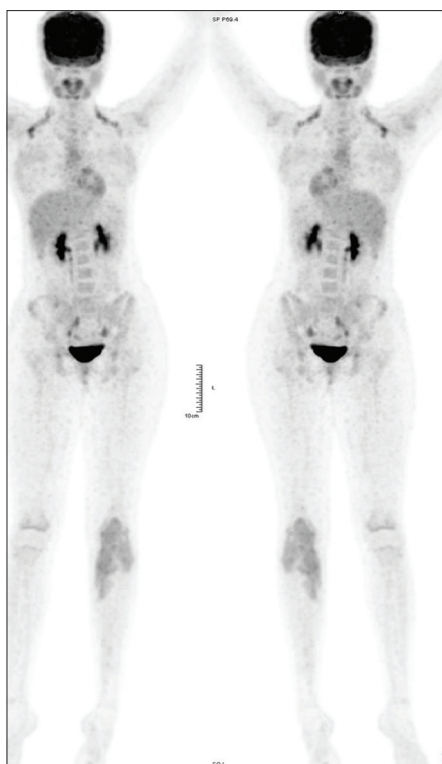


Figure 3: Maximum intensity projection in the anterior and posterior views showing physiological tracer uptake in the brown fat, thymus, breasts, heart, liver, spleen, kidneys, and bladder. Increased abnormal tracer uptake is seen posterior to the left knee joint

A comprehensive imaging assessment tumor is required for assessing the shape, size, location, density, margins, and anatomical association with neighboring tissues, providing useful information for diagnosis and treatment.

The treatment of choice is surgical resection of the tumor. Recurrence rate is high in desmoid fibromatosis even though margins are free. Systemic chemotherapy and radiotherapy are reserved for patients with high risk for surgery, for those tumors in unfavorable location, and to reduce recurrence rate.^[8]

CONCLUSION

Fibromatosis is a significant benign impersonator of malignancy involving the soft tissue, which is aggressive in its demeanor and has high recurrence rates. MRI with its superlative soft-tissue resolution is the mainstay of investigation to plan surgery, which is the definitive treatment. ¹⁸F-FDG PET/CT acts as an additional tool which supplements MRI in diagnosis and management planning. In inoperable cases, high- and low-grade uptake of these tumors correlates with the preponderance of cellular and stromal components, respectively. This bird's eye view of the otherwise inexplicit tumor heterogeneity helps in choosing

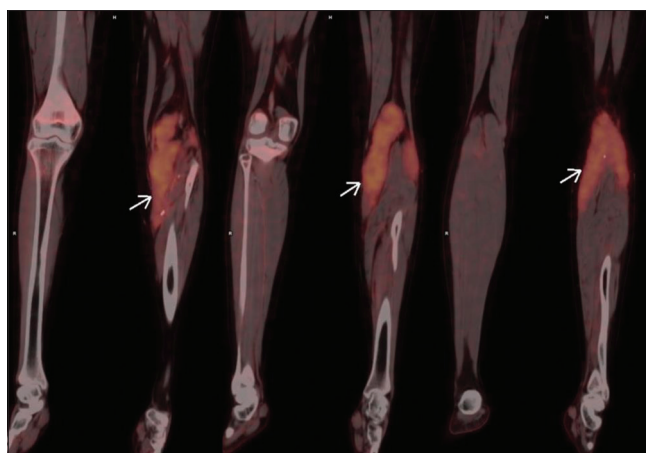


Figure 4: Coronal positron emission tomography-computed tomography-fused images showing mildly fluorodeoxyglucose-avid soft-tissue mass (white arrow) in the left popliteal fossa involving popliteus and gastrocnemius muscles

the best modality of treatment. Baseline ¹⁸F-FDG PET/CT can serve as a valuable tool during treatment monitoring, and might be an early indicator of treatment response. It aids as a one stop shop for whole-body imaging to look out for multifocality and overall staging of the disease, especially in cases of relapse.

Declaration of patient consent

The authors certify that they have obtained all appropriate patient consent forms. In the form, the legal guardian has given his consent for images and other clinical information to be reported in the journal. The guardian understands that names and initials will not be published and due efforts will be made to conceal identity, but anonymity cannot be guaranteed.

Financial support and sponsorship

Nil.

Conflicts of interest

There are no conflicts of interest.

REFERENCES

- Gourgiotis S, Gemenetzi G, Villias C. Pancreatic desmoid tumour: Extremely rare presentation in an elderly patient. *Hell J Surg* 2014;86:378-81
- Liu Q, Fang L, Li B. Desmoid fibromatosis in the foot: A case report and literature review. *Medicine (Baltimore)* 2018;97:e13109.
- Basu S, Nair N, Banavali S. Uptake characteristics of fluorodeoxyglucose (FDG) in deep fibromatosis and abdominal desmoids: Potential clinical role of FDG-PET in the management. *Br J Radiol* 2007;80:750-6.
- Duan M, Xing H, Wang K, Niu C, Jiang C, Zhang L, *et al.* Large and aggressive fibromatosis in the axilla: A rare case report and review of the literature. *Onco Targets Ther* 2018;11:3179-84.
- Alshammari A, Ashkanani R, Alabsi S, Ghanem M. Gardner syndrome with extra and intra-abdominal desmoid tumors and adrenal involvement:

- PET/CT findings. Case Rep Mol Imaging Radionucl Ther 2015;24 Suppl 1:38-41.
6. Braschi-Amirfarzan M, Keraliya AR, Krajewski KM, Tirumani SH, Shinagare AB, Hornick JL, *et al.* Role of imaging in management of desmoid-type fibromatosis: A primer for radiologists. Radiographics 2016;36:767-82.
 7. Garg P, Chufal SS, Gupta N, Pant P, Thapliyal NC. Multicentric aggressive mammary fibromatosis with cytological features and review of literature. J Clin Diagn Res 2014;8:FD01-3.
 8. Souza FF, Fennessy FM, Yang Q, van den Abbeele AD. Case report. PET/CT appearance of desmoid tumour of the chest wall. Br J Radiol 2010;83:e39-42.