

## Original Article

# Visual versus semiquantitative analysis of <sup>18</sup>F-fluorodeoxyglucose-positron emission tomography brain images in patients with dementia

## ABSTRACT

Various studies have reported to the superiority of semiquantitative (SQ) analysis over visual analysis in detecting metabolic changes in the brain. In this study, we aimed to determine the limitations of SQ analysis programs and the current status of <sup>18</sup>F-fluorodeoxyglucose (FDG)-positron emission tomography (PET) scan in dementia. <sup>18</sup>F-FDG-PET/computed tomography (CT) brain images of 39 patients with a history of dementia were analyzed both visually and semiquantitatively. Using the visually markedly abnormal <sup>18</sup>F-FDG-PET images as standard, we wanted to test the accuracy of two commercially available SQ analysis programs. SQ analysis results were classified as matching, partially matching and nonmatching with visually markedly abnormal studies. On visual analysis, <sup>18</sup>F-FDG-PET showed marked regional hypometabolism in 19 patients, mild abnormalities in 8 and was normal in 12 patients. SQ analysis-1 results matched with visual analysis in 8 patients (42.1%) and partially matched in 11. SQ analysis-2 findings matched with visual analysis in 11 patients (57.8%) and partially matched in 7 and did not match in 1. Marked regional hypometabolism was either on the left side of the brain or was more significant on the left than the right in 63% of patients. Preservation of metabolism in sensorimotor cortex was seen in various dementia subtypes. Reviewing images in color scale and maximum intensity projection (MIP) image was helpful in demonstrating and displaying regional abnormalities, respectively. SQ analysis provides less accurate results as compared to visual analysis by experts. Due to suboptimal image registration and selection of brain areas, SQ analysis provides inaccurate results, particularly in small areas and areas in close proximity. Image registration and selection of areas with SQ programs should be checked carefully before reporting the results.

**Keywords:** Brain imaging, dementia, <sup>18</sup>F-fluorodeoxyglucose-positron emission tomography, semiquantitative analysis, visual analysis

## INTRODUCTION


Dementia is a clinical syndrome with difficulties in memory, language, and behavior.<sup>[1]</sup> There are various subtypes of dementias with each one of them having different management, disease course, and outcomes.<sup>[2]</sup> Alzheimer's disease (AD) is the most common cause of dementia. The other subtypes of dementias include frontotemporal dementias (FTDs), diffuse Lewy body dementia (DLBD), multi-infarct dementia (MID), Parkinson's disease dementia, and Parkinson plus syndromes with dementia (progressive supranuclear palsy and cortical basal ganglionic degeneration). Mild cognitive impairment (MCI) is an intermediate stage between normal age-related cognitive decline and dementia.

**ISMET SARIKAYA, WALAA A. KAMEL<sup>1,2</sup>, KHATTAB KHALED ATEYAH<sup>3</sup>, NOORAESSA BIN ESSA<sup>4</sup>, SAMIRA ALTAILJI<sup>2</sup>, ALI SARIKAYA<sup>5</sup>**

Department of Nuclear Medicine, Faculty of Medicine, Kuwait University, <sup>1</sup>Department of Neurology, Faculty of Medicine, Beni-Suef University, Egypt, <sup>2</sup>Department of Nuclear Medicine, Ibn Sina Hospital, <sup>3</sup>Department of Nuclear Medicine, Adan Hospital, <sup>4</sup>Department of Nuclear Medicine, Mubarak Al-Kabeer Hospital, Kuwait City, Kuwait, <sup>5</sup>Department of Nuclear Medicine, Faculty of Medicine, Trakya University, Edirne, Turkey

**Address for correspondence:** Dr. Ismet Sarikaya, Department of Nuclear Medicine, Faculty of Medicine, Kuwait University, PO Box 24923, Safat 13110, Kuwait.  
E-mail: isarikaya99@yahoo.com

**Submitted:** 15-May-2018, **Revised:** 31-May-2018, **Accepted:** 19-Jul-2018, **Published:** 20-Jan-2021

Access this article online	
<b>Website:</b> www.wjnm.org	<b>Quick Response Code</b> 
<b>DOI:</b> 10.4103/wjnm.WJNM_53_18	

This is an open access journal, and articles are distributed under the terms of the Creative Commons Attribution-NonCommercial-ShareAlike 4.0 License, which allows others to remix, tweak, and build upon the work non-commercially, as long as appropriate credit is given and the new creations are licensed under the identical terms.

**For reprints contact:** WKHLRPMedknow\_reprints@wolterskluwer.com

**How to cite this article:** Sarikaya I, Kamel WA, Ateyah KK, Essa NB, AlTailji S, Sarikaya A. Visual versus semiquantitative analysis of <sup>18</sup>F-fluorodeoxyglucose-positron emission tomography brain images in patients with dementia. World J Nucl Med 2021;20:82-9.

In MCI, cognitive loss does not affect function and daily living activities.<sup>[1]</sup> Early diagnosis of dementias allows early and appropriate intervention with the use of specific medications for symptomatic treatment. Increasing evidence shows that dementia may be preventable which makes early diagnosis important.<sup>[1,3,4]</sup>

In the initial assessment of dementia, first potentially treatable diseases or reversible causes of the dementia, such as depression, thyroid diseases, and vitamin B-12 deficiency, are investigated.<sup>[1]</sup> Computed tomography (CT) and magnetic resonance imaging (MRI) is used to exclude structural abnormalities such as tumor and vascular diseases. Current MRI techniques can also help differentiate subtypes of dementia.<sup>[5]</sup> Radionuclide brain imaging studies are used to determine the subtype of dementia in doubtful cases. Various single-photon emission computed tomography (SPECT) and positron emission tomography (PET) studies are available and among these <sup>18</sup>F- fluorodeoxyglucose (<sup>18</sup>F- FDG)-PET scan is the most commonly used study.<sup>[6-11]</sup> The other available studies include brain perfusion SPECT, dopamine transporter (DAT) scan and amyloid PET scan. Oxygen-15 (O-15) water-brain perfusion and O-15 PET imaging are available only in limited centers and recently, tau ligands for PET imaging have been developed.<sup>[8,9]</sup>

In routine <sup>18</sup>F- FDG-PET studies, images are assessed visually and semiquantitative (SQ) analysis is also used in many centers. Over the years, various SQ analysis programs have been developed with the purpose of detecting mild abnormalities in the brain which are not apparent on visual inspection.<sup>[12-18]</sup> Various studies have reported the superiority of SQ analysis programs over visual analysis. It was reported that automated analysis of <sup>18</sup>F- FDG-PET had 93% sensitivity and specificity for detection of mild-to-moderate probable AD and 84% sensitivity and 93% specificity for detection of very mild probable AD.<sup>[13]</sup> SQ analysis improved the diagnostic accuracy, specificity, and confidence of <sup>18</sup>F- FDG-PET interpretation for evaluation of MCI or AD in another study.<sup>[14]</sup> Morbelli *et al.* suggested that visual <sup>18</sup>F- FDG-PET reads by an expert is the most accurate method but an automated, validated system may be particularly helpful to moderately-skilled readers because of high specificity and should be mandatory when even a moderately-skilled reader is unavailable.<sup>[12]</sup> However, in routine assessment of our <sup>18</sup>F- FDG brain PET images, we come across certain limitations of SQ analysis which is well recognized by well-experienced physicians but by less or inexperienced physicians or clinicians. In this article, we wanted to outline the certain limitations of SQ analyses programs by comparing them with visual assessment of images and presenting with figures and also review the

current status of <sup>18</sup>F- FDG-PET and other imaging studies for dementias.

## MATERIAL AND METHODS

In this retrospective study, <sup>18</sup>F- FDG-PET/CT brain images of 39 patients with a history of dementia were analyzed by visual and SQ analysis using two commercially available programs NeuroQ (Syntermed Inc., Atlanta, GA) and Hermes BRASS (Hermes Medical Solutions, Stockholm, Sweden).

<sup>18</sup>F- FDG-PET brain imaging studies were performed at Mubarak Al Kabeer Hospital. <sup>18</sup>F- FDG-PET/CT images were obtained at Phillips Gemini Time of Flight 64 PET/CT camera. Patients fasted 4–6 h before the study. Patients were placed in a quiet, dimly-lit room for at least 30 min before <sup>18</sup>F- FDG injection and in the subsequent uptake phase. Blood glucose were checked before <sup>18</sup>F- FDG administration. <sup>18</sup>F- FDG was injected when the blood glucose level was <150 mg/dL. 60 min following IV injection of 370 MBq (10 mCi) of <sup>18</sup>F- FDG, first a low-dose CT and then PET images (15 min) were obtained from the whole brain. Iterative reconstruction was used for image processing. Images were evaluated by two expert readers reviewing attenuation corrected and uncorrected PET, low-dose CT, and PET/CT fusion images in transaxial, sagittal, and coronal planes and maximum intensity projection (MIP) image. Low-dose CT images were also evaluated by a radiologist. <sup>18</sup>F- FDG-PET images were reviewed using both gray and color scales.

We used the following criteria to diagnose or differentiate subtypes of dementias by visual analysis.<sup>[19-23]</sup>

### Alzheimer's disease

In AD, characteristic findings on F-18 FDG-PET include hypometabolism in bilateral or unilateral parietal (lateral and also medial/precuneus) and temporal lobes and posterior cingulate cortex. Hypometabolism may also involve the frontal lobes. There is preserved metabolism in sensorimotor cortices, basal ganglia, occipital lobes, and cerebellum.

### Diffuse Lewy body dementia

In DLBD, there is hypometabolism in bilateral or unilateral occipital (primary visual cortex) which may also involve the parietal and temporal lobes. Preserved metabolism in the posterior cingulate cortex (cingulate island).<sup>[23]</sup>

### Frontotemporal dementias

Hypometabolism involves bilateral or unilateral frontal (mainly medial and anterior, also lateral) and temporal (anterior) lobes in FTD. Hypometabolism may also involve parietal lobes and subcortical structures.

### Multi infarct dementia

In MID, there are focal areas of hypometabolism corresponding to the area of infarctions in cortical and subcortical structures and cerebellum. Diffusely reduced uptake in the hemispheric contralateral to large area of infarct (crossed cerebellar diaschisis) may be seen.

### Mild cognitive impairment

In MCI, hypometabolism is mainly in posterior cingulate cortex and hippocampus (area medial to temporal lobe).

Using the visually markedly abnormal  $^{18}\text{F}$ -FDG-PET images as standard, we wanted to test the accuracy of commercially available SQ analysis programs. SQ analysis results were classified as matching (showing all the abnormalities seen on visual analysis with or without additional findings), partially matching (showing only some of the abnormalities seen on visual analysis with or without additional findings), and nonmatching (not showing any of abnormal findings on visual analysis) with visually markedly abnormal  $^{18}\text{F}$ -FDG-PET studies.

In Neuro Q, 20 iterations were used for reformatting. Control and patient values were normalized to the average pixel value among all regions in each scan. Hypometabolic areas were shown on a normal template (Blue: normal metabolism. Red, pink, and purple: hypometabolism, red  $> -3$  standard deviation (SD), pink  $> -2/-3$  SD, and purple  $> -1/-2$  SD). List of the areas assessed with this software included the right and left frontal lobe (superior, mid, inferior, and medial), Broca's region, sensorimotor cortex, temporal lobe (superolateral, inferolateral anterior, inferolateral posterior, anterior medial, and posterior medial), parietotemporal cortex, parietal lobe (superior and inferior), occipital lobe (primary visual cortex, and visual associative cortex), anterior cingulate cortex, posterior cingulate cortex, caudate nucleus, lentiform nucleus, thalamus, cerebellum, vermis, and midbrain.

In Hermes BRASS, image registration with templates was adjusted manually and brain areas were selected automatically by the program. The average counts per voxel were compared with control values in templates. Values  $> -2$  SD was considered abnormal and shown as red color in the results display. List of the areas assessed with this software included the right and left precentral cortex, orbitofrontal cortex, frontal lateral, frontal medial, insula, anterior cingulate, posterior cingulate, mesiotemporal lobe, mesio-occipital lobe, occipital cortex, postcentral cortex, superior parietal cortex, inferior parietal cortex, precuneus, caudate, putamen, pallidum, thalamus, superior temporal cortex, mid-temporal cortex, inferior temporal cortex, temporal pole, cerebellum, and vermis.

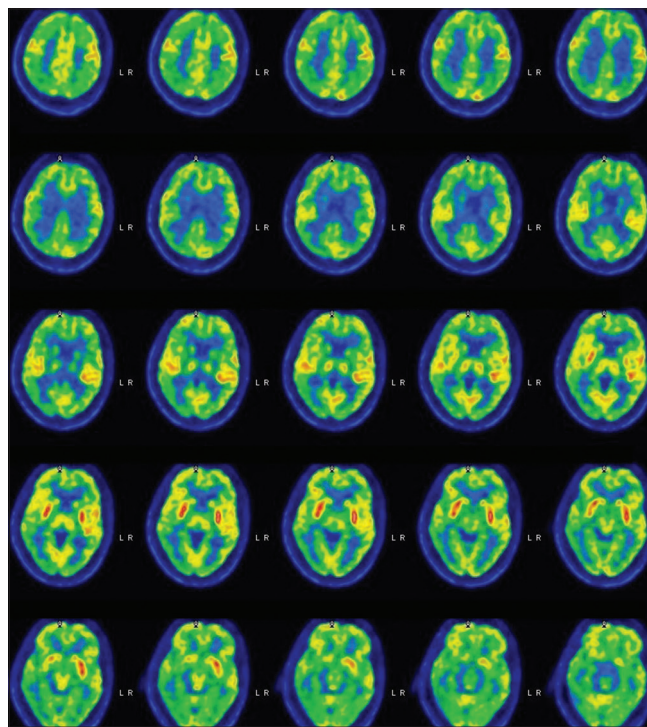
## RESULTS

Twenty-one patients were female and 18 were male (age range 38–85 years, mean age – 69.2 year). Duration of dementia ranged from 6 months to 10 years. In addition to memory loss, some patients also had various other symptoms such as visual or nonvisual hallucinations, bradykinesia, stiffness, behavioral, and personality changes.

Visual analysis of  $^{18}\text{F}$ -FDG-PET showed marked regional hypometabolism in 19 patients (AD in 12, FTD in 4, diffuse Lewy body disease (DLBD) in 2 patients, and MID in 1 patient), mild regional metabolism in 12 patients, and normal metabolism in 8. Figure 1 shows images of a patient with DLBD.

There was reduced uptake anterior and posterior to motor cortices with preservation of uptake in sensorimotor cortices in 11 of 19 patients with markedly reduced regional metabolism (8 patients with AD, 2 with FD, and 1 DLBD).

In 12 of 19 patients with marked abnormalities on  $^{18}\text{F}$ -FDG-PET, abnormalities were either on the left side of the brain or were more significant on the left than the right (63.1%).



**Figure 1:** An 80-year-old male with a history of visual hallucinations and cognitive decline with Parkinsonian feature, which was clinically suspicious for diffuse Lewy body dementia.  $^{18}\text{F}$ -fluorodeoxyglucose-positron emission tomography images demonstrated reduced metabolism in bilateral parietal, frontal, temporal, and occipital cortices. There was preservation of metabolic activity in bilateral sensorimotor cortices

In 12 patients with mild abnormalities, mildly reduced metabolism was seen either in parietal or parietotemporal lobes unilaterally or bilaterally which was questionable for early dementia. In 7 of these patients, findings were either on the left or more significant on the left than the right (58.3%).

In patients with visually markedly abnormal <sup>18</sup>F-FDG-PET, NeuroQ results matched with visual findings in 8 patients (42.1%) and partially matched in 11, and Hermes BRASS results matched with visual findings in 11 patients (57.8%), partially matched in 7 and did not match in 1 [Figures 2 and 3]. Both programs also showed additional areas of various degree of abnormalities in all patients which were not seen visually. Figure 2 shows <sup>18</sup>F-FDG-PET images and SQ analysis results of a 71-year-old female with known mental illness with progressive behavioral changes, Wernicke aphasia, and frontal lobe features which is clinically suspicious for AD versus FTD. <sup>18</sup>F-FDG-PET images demonstrate reduced metabolism

which is marked in bilateral parietal lobes, precuneus, posterior cingulate cortices, and frontal (mainly laterally) and temporal (mainly posterolaterally) lobes. There is preserved metabolism in motor cortices. Scintigraphic findings are consistent with AD. SQ analysis-1 results are partially matching with visual findings showing reduced metabolism in bilateral frontal and temporal lobes, and temporoparietal junctions, and left posterior cingulate cortex but not showing the reduced metabolism in bilateral superior and inferior parietal cortices. It also shows mild reduced metabolism in the right occipital cortex. SQ analysis-2 results demonstrating reduced metabolism in bilateral parietal, temporal, and frontal lobes, precuneus and posterior cingulate cortices which are matching with visual findings but also in occipital cortices. Reduced occipital metabolism with this analysis is probably due to the erroneous selection of region of interest including posterior temporal areas. Furthermore, there is also suboptimal selection of caudate head and thalami with SQ analysis-2.

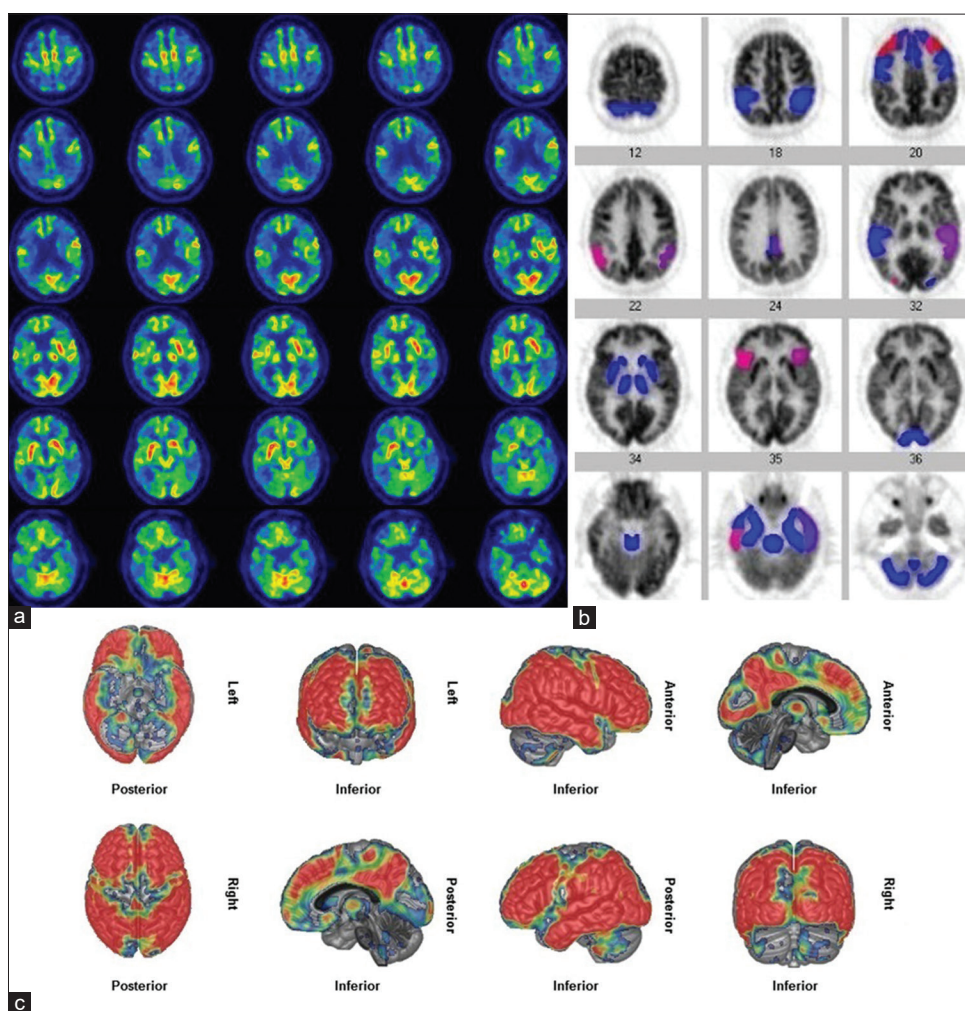


Figure 2: <sup>18</sup>F- fluorodeoxyglucose-positron emission tomography transaxial images of the brain (a), semiquantitative analysis-1 results (b), and semiquantitative analysis-2 results (c) in a patient with Alzheimer's disease demonstrating suboptimal results with semiquantitative analysis programs

Figure 3 shows <sup>18</sup>F- FDG-PET images and SQ analysis results of a 71-year-old female with the progressive cognitive decline and gait difficulty which is clinically suspicious for AD. <sup>18</sup>F- FDG-PET images demonstrate reduced metabolism in bilateral parietal, temporal and frontal lobes, suggestive of AD. There is preserved metabolism in the motor cortices, occipital lobes, and cerebellum. There is also questionable reduced uptake in the right thalamus. SQ analysis-1 shows reduced metabolism in the right inferior parietal, bilateral temporal, and frontal lobes but does not show the reduced metabolism in bilateral superior parietal and left inferior parietal regions and right thalamus. It also shows reduced metabolism in the right putamen and left caudate head. SQ analysis-2 shows reduced metabolism in bilateral parietal and temporal lobes and also in a lesser degree in frontal lobes. It also shows reduced metabolism in right occipital and bilateral inferior cerebellar regions which are not seen visually. There is also the suboptimal selection of caudate heads with this program.

SQ analysis showed various degree of regional abnormalities in the rest of the patients with visually mildly abnormal or normal <sup>18</sup>F- FDG-PET.

Visual inspection of image registration and automated selection of areas by Hermes BRASS programs showed varying degree of suboptimal results in all patients [Figures 2-4]. The brain areas did not fit well to templates either exceeding the boundaries of the templates or were inside but smaller than the template area. The small subcortical structures such as the caudate, putamen, and thalamus were usually suboptimally selected. In NeuroQ program, there was no option to check the accuracy of selection of brain areas in multiple slices.

Overall, reviewing images in color scale better demonstrated the hypometabolic regions as compared to grayscale in majority of the patients [Figure 5]. Three-dimensional (3D) MIP image helped better-presenting abnormalities in 3D display [Figure 6]. Careful analysis of low-dose CT images helped to determine certain abnormalities in some patients (left temporal infarct, widened sulci, cortical atrophy, and dilated ventricles) which helped accurately interpreting PET images [Figure 7].

## DISCUSSION

<sup>18</sup>F- FDG-PET scan is commonly used in the early and differential diagnosis of dementia. In addition to visual

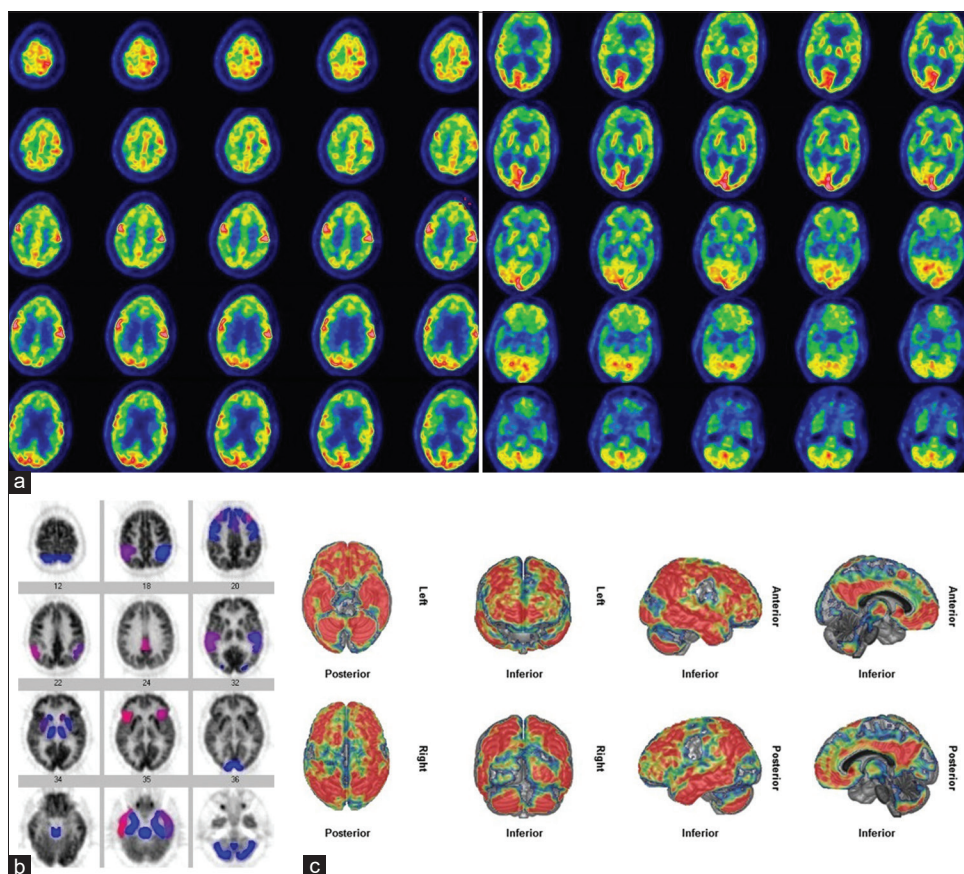
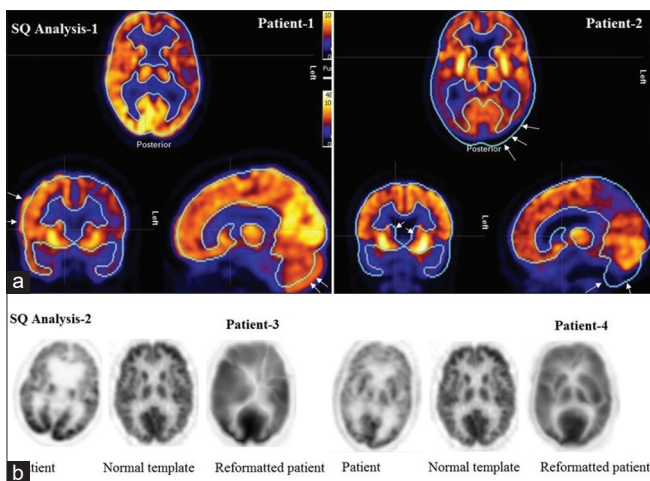
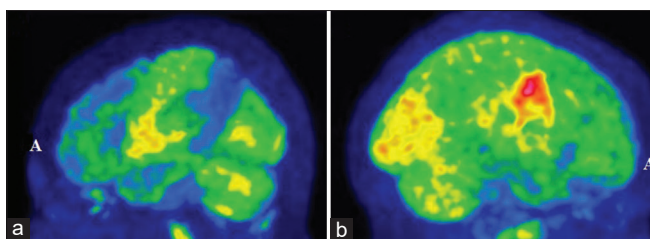


Figure 3: <sup>18</sup>F- fluorodeoxyglucose-positron emission tomography transaxial images of the brain (a), semiquantitative analysis-1 results (b), and semiquantitative analysis-2 results (c) in a patient with Alzheimer's disease demonstrating suboptimal results with semiquantitative analysis programs

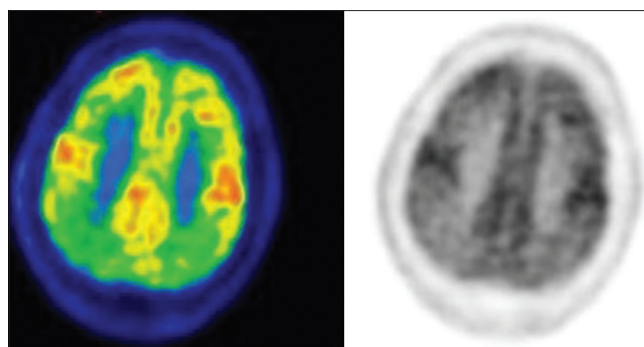


**Figure 4: Image registration and selection of areas with semiquantitative analysis-2 (a). Note the suboptimal selection of areas (arrows). Suboptimal reformatted patient images with semiquantitative analysis-1 (b)**

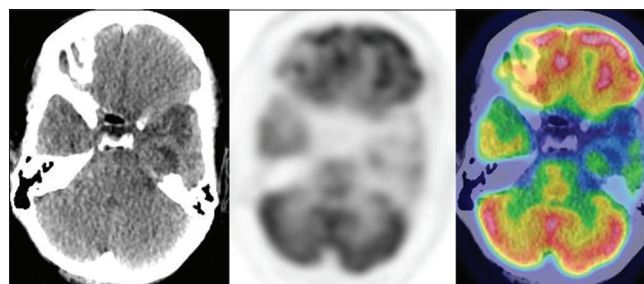


**Figure 6: Fluorodeoxyglucose-positron emission tomography maximum intensity projection images of patients in Figure 2 (a) and Figure 3 (b). Note that maximum intensity projection images better present abnormalities in a three-dimensional display**

assessment of the images commercially available SQ analysis programs are also commonly used in many centers. While expert nuclear medicine physicians mainly visually assess the images, inexperienced physicians usually need the help of SQ analysis. Accurate visual analysis requires expertise with a good knowledge of normal distribution of <sup>18</sup>F- FDG in the brain in various ages, characteristic distribution of metabolic abnormalities in various subtypes of dementias, and normal brain anatomy, and specific brain areas, and recognizing abnormal findings on low-dose CT scan and certain artifacts on PET/CT images. SQ analysis programs aim to determine if there is statistically significant difference between patient and normal values or between the right and left side of the brain (asymmetry index) by selecting brain areas automatically or manually. In the automatic selection of brain areas, global spatial normalization is used to match global spatial features of patient's brain (position, orientation, and dimensions) with a standard or brain atlas using various algorithms.<sup>[24]</sup> Most commonly used brain template is Talairach atlas (Co-Planar Stereotaxic Atlas of the Brain).<sup>[25]</sup> However, registering patient's image with a brain template/atlas and automatic selection of areas is usually suboptimal due to complex brain anatomy (differences in the gyral and sulcal pattern), various



**Figure 5: Selected transaxial fluorodeoxyglucose-positron emission tomography images in color and grayscale. Note that color scale better demonstrates hypometabolic regions in bilateral frontal and parietal lobes as compared to grayscale**



**Figure 7: Selected computed tomography, 18F- fluorodeoxyglucose-positron emission tomography and positron emission tomography/computed tomography fusion images of 57-year-old male with 2 years history of memory disturbance. Computed tomography image shows left temporal infarct. Positron emission tomography image shows reduced left temporal glucose metabolism due to old infarct**

size and shape of the brains as well as position of the head during image acquisition. These create inaccurate results for regional glucose metabolism in various parts of the brain, particularly in the small areas and areas in close proximity or assessing metabolism in a whole lobe or area.

In our study, using visually markedly abnormal PET images as standard, we tested the accuracy of commercially available SQ analysis programs. The SQ analysis programs matched with visual analysis findings only in approximately half of the patients. Commercially available SQ analysis programs have certain limitations and inexperienced physicians using SQ analysis results should be aware of these. Automatic or manual selection of brain areas is usually suboptimal. Before reporting SQ analysis results, particularly with SQ analysis programs automatically selecting areas, the accuracy of selected areas should be checked visually to provide accurate results. Suboptimal selection of the brain areas may cause inaccurate SQ results, particularly in small regions such as basal ganglia and regions in close proximity such as cingulate cortex, and when assessing uptake in whole lobe or a specific part of the lobe, and small specific areas such as Broca's area. <sup>18</sup>F- FDG-PET images coregistered with MRI or CT may help to

better select brain areas but also require knowledge of MRI and CT anatomy. Developing a software program to open up brain gyri into a large flat area/map and parceling it to specific brain areas may help better-locating areas in the brain.

In SQ analysis programs, images are normalized to whole-brain activity or a reference region such as cerebellum. Significant reductions in metabolic activity in the whole brain or reference region, will generate erroneous results. The other limitations of SQ analysis programs include suboptimal comparison with normal controls. SQ analysis results should be compared with age- and gender-matched controls and number of controls should be high enough to provide accurate results. Number of the normal controls is usually <50 in commercially available programs. In some commercially available programs control age range is wide, 25–80 years. Normal values may also show difference in different races.

Subtypes of dementia usually show characteristic regional metabolic abnormality, but they may also resemble each other on <sup>18</sup>F- FDG-PET images. Reduced occipital metabolism or hypoperfusion can be seen in atypical forms of AD, such as visual variant of AD or posterior cortical atrophy.<sup>[26]</sup> In a case with bilateral occipital reduced perfusion on Tc-99m hexamethylpropyleneamine oxime SPECT, neuropathological examination after death demonstrated established AD with particularly severe involvement of the visual occipital cortex.<sup>[26]</sup> In a report of eight patients who were diagnosed with behavioral variant FTD based on their clinical, neuropsychological, and neuroimaging (SPECT and MRI) findings, while cerebrospinal fluid biomarkers showed an AD biological profile, thus supporting a diagnosis of frontal variant of AD.<sup>[27]</sup> The other nuclear medicine studies such as DAT scan and amyloid imaging can help differentiate dementia subtypes when <sup>18</sup>F- FDG-PET scan is indeterminate.<sup>[28,29]</sup> In DLBD and other dementias with Parkinsonism, DAT scan shows reduced uptake in bilateral or unilateral corpus striatum. Extrapyramidal symptoms are also observed in FTD and reduced DAT binding has also been reported.<sup>[30]</sup> Amyloid PET imaging is also useful which is positive in majority of the patients with AD but usually negative in FTD.<sup>[31]</sup> However, positive amyloid PET can also be seen in normal older individuals, DLBD and cerebral amyloid angiopathy, and negative amyloid PET can be seen in rare forms of AD with unusual amyloid.<sup>[32-34]</sup>

Reduced frontal uptake due to depression in AD may resemble FTD if it is significant. Depressive symptoms in AD patients were associated with relative hypoperfusion in the prefrontal cortex when they were compared with AD patients without

depressive symptoms.<sup>[35]</sup> Hypoperfusion in the left frontal cortex was found in AD patients with depression.<sup>[36]</sup>

<sup>18</sup>F- FDG-PET images should be obtained in optimal condition by keeping the patient in a room with dim light during injection and uptake period of radiotracer. The uptake of <sup>18</sup>F- FDG when the patient's eyes are closed may cause hypometabolism in the occipital lobe which may mimic DLBD. Prominent light during radiotracer injection or uptake period may increase the uptake in the visual cortex and prevent the diagnosis of DLBD.

Sensorimotor cortex is spared not only in AD but also in DLBD and FTD.<sup>[22]</sup> In our 14 patients, sensorimotor uptake was prominent as compared to the areas of reduced metabolism.

Marked regional hypometabolism was either on the left side of the brain or was more significant on the left than the right in 63% of patients. In patients with AD, abnormalities were more marked on the left side of the brain on perfusion SPECT.<sup>[37]</sup>

## CONCLUSION

<sup>18</sup>F- FDG-PET imaging is useful in the diagnosis and differentiation of subtypes of dementia. In cases with marked abnormalities on visual analysis, SQ analysis does not add much. Current SQ analysis programs have certain limitations due to suboptimal selection of brain areas as well as erroneous uptake normalization procedure. SQ analysis programs with better area selection and comparison with higher number of age-matched normal control values are needed to more accurately assess metabolic changes in the brain. When using currently available SQ analysis programs, image registration and selection of areas should be checked carefully before reporting the results.

## Financial support and sponsorship

Nil.

## Conflicts of interest

There are no conflicts of interest.

## REFERENCES

1. Robinson L, Tang E, Taylor JP. Dementia: Timely diagnosis and early intervention. *BMJ* 2015;350:h3029.
2. Scott KR, Barrett AM. Dementia syndromes: Evaluation and treatment. *Expert Rev Neurother* 2007;7:407-22.
3. Matthews FE, Arthur A, Barnes LE, Bond J, Jagger C, Robinson L, et al. A two-decade comparison of prevalence of dementia in individuals aged 65 years and older from three geographical areas of England: Results of the cognitive function and ageing study I and II. *Lancet*

- 2013;382:1405-12.
4. Prince M, Bryce R, Ferri C. World Alzheimer Report 2011: The Benefits of Early Diagnosis and Intervention. London, UK: Alzheimer's Disease International; 2011.
  5. Murray AD. Imaging approaches for dementia. *AJNR Am J Neuroradiol* 2012;33:1836-44.
  6. Rice L, Bisdas S. The diagnostic value of FDG and amyloid PET in Alzheimer's disease-A systematic review. *Eur J Radiol* 2017;94:16-24.
  7. Donnemiller E, Heilmann J, Wenning GK, Berger W, Decristoforo C, Moncayo R, et al. Brain perfusion scintigraphy with 99mTc-HMPAO or 99mTc-ECD and 123I-beta-CIT single-photon emission tomography in dementia of the Alzheimer-type and diffuse Lewy body disease. *Eur J Nucl Med* 1997;24:320-5.
  8. Anderson KE, Brickman AM, Flynn J, Scarmeas N, Van Heertum R, Sackeim H, et al. Impairment of nonverbal recognition in Alzheimer disease: A PET O-15 study. *Neurology* 2007;69:32-41.
  9. Lowe VJ, Wiste HJ, Senjem ML, Weigand SD, Therneau TM, Boeve BF, et al. Widespread brain tau and its association with ageing, braak stage and Alzheimer's dementia. *Brain* 2018;141:271-87.
  10. Small GW, Ercoli LM, Silverman DH, Huang SC, Komo S, Bookheimer SY, et al. Cerebral metabolic and cognitive decline in persons at genetic risk for Alzheimer's disease. *Proc Natl Acad Sci U S A* 2000;97:6037-42.
  11. Tripathi M, Tripathi M, Damle N, Kushwaha S, Jaimini A, D'Souza MM, et al. Differential diagnosis of neurodegenerative dementias using metabolic phenotypes on <sup>18</sup>F- FDG PET/CT. *Neuroradiol J* 2014;27:13-21.
  12. Morbelli S, Brugnolo A, Bossert I, Buschiazzi A, Frisoni GB, Galluzzi S, et al. Visual versus semi-quantitative analysis of 18F-FDG-PET in amnesic MCI: An European Alzheimer's disease consortium (EADC) project. *J Alzheimers Dis* 2015;44:815-26.
  13. Herholz K, Salmon E, Perani D, Baron JC, Holthoff V, Frölich L, et al. Discrimination between Alzheimer dementia and controls by automated analysis of multicenter FDG PET. *Neuroimage* 2002;17:302-16.
  14. Lehman VT, Carter RE, Claassen DO, Murphy RC, Lowe V, Petersen RC, et al. Visual assessment versus quantitative three-dimensional stereotactic surface projection fluorodeoxyglucose positron emission tomography for detection of mild cognitive impairment and Alzheimer disease. *Clin Nucl Med* 2012;37:721-6.
  15. Gallivanone F, Della Rosa PA, Castiglioni I. Statistical voxel-based methods and [18F] FDG PET brain imaging: Frontiers for the diagnosis of AD. *Curr Alzheimer Res* 2016;13:682-94.
  16. Minoshima S, Frey KA, Koeppe RA, Foster NL, Kuhl DE. A diagnostic approach in Alzheimer's disease using three-dimensional stereotactic surface projections of fluorine-18-FDG PET. *J Nucl Med* 1995;36:1238-48.
  17. Yamane T, Ikari Y, Nishio T, Ishii K, Ishii K, Kato T, et al. Visual-statistical interpretation of (18)F-FDG-PET images for characteristic Alzheimer patterns in a multicenter study: Inter-rater concordance and relationship to automated quantitative evaluation. *AJNR Am J Neuroradiol* 2014;35:244-9.
  18. Partovi S, Yuh R, Pirozzi S, Lu Z, Couturier S, Grosse U, et al. Diagnostic performance of an automated analysis software for the diagnosis of Alzheimer's dementia with <sup>18</sup>F FDG PET. *Am J Nucl Med Mol Imaging* 2017;7:12-23.
  19. Shivamurthy VK, Tahari AK, Marcus C, Subramaniam RM. Brain FDG PET and the diagnosis of dementia. *AJR Am J Roentgenol* 2015;204:W76-85.
  20. Herholz K. Guidance for reading FDG PET scans in dementia patients. *Q J Nucl Med Mol Imaging* 2014;58:332-43.
  21. Bhogal P, Mahoney C, Graeme-Baker S, Roy A, Shah S, Fraioli F, et al. The common dementias: A pictorial review. *Eur Radiol* 2013;23:3405-17.
  22. Brown RK, Bohnen NI, Wong KK, Minoshima S, Frey KA. Brain PET in suspected dementia: Patterns of altered FDG metabolism. *Radiographics* 2014;34:684-701.
  23. McKeith IG, Boeve BF, Dickson DW, Halliday G, Taylor JP, Weintraub D, et al. Diagnosis and management of dementia with Lewy bodies: Fourth consensus report of the DLB consortium. *Neurology* 2017;89:88-100.
  24. Lancaster JL, Fox PT, Downs H, Nickerson DS, Hander TA, El Mallah M, et al. Global spatial normalization of human brain using convex hulls. *J Nucl Med* 1999;40:942-55.
  25. Talairach J, Tournoux P. Co-Planar Stereotaxic Atlas of the Human Brain. New York, NY: Thieme Medical Publishers; 1988.
  26. Galton CJ, Patterson K, Xuereb JH, Hodges JR. Atypical and typical presentations of Alzheimer's disease: A clinical, neuropsychological, neuroimaging and pathological study of 13 cases. *Brain* 2000;123 Pt 3:484-98.
  27. de Souza LC, Bertoux M, Funkiewiez A, Samri D, Azuar C, Habert MO, et al. Frontal presentation of Alzheimer's disease: A series of patients with biological evidence by CSF biomarkers. *Dement Neuropsychol* 2013;7:66-74.
  28. Brigo F, Turri G, Tinazzi M. 123I-FP-CIT SPECT in the differential diagnosis between dementia with Lewy bodies and other dementias. *J Neurol Sci* 2015;359:161-71.
  29. Kobylecki C, Langheinrich T, Hinz R, Vardy ER, Brown G, Martino ME, et al. 18F-florbetapir PET in patients with frontotemporal dementia and Alzheimer disease. *J Nucl Med* 2015;56:386-91.
  30. Sedaghat F, Gotzamani-Psarrakou A, Dedousi E, Arnaoutoglou M, Psarrakos K, Baloyannis I, et al. Evaluation of dopaminergic function in frontotemporal dementia using I-FP-CIT single photon emission computed tomography. *Neurodegener Dis* 2007;4:382-5.
  31. Engler H, Santillo AF, Wang SX, Lindau M, Savitcheva I, Nordberg A, et al. *In vivo* amyloid imaging with PET in frontotemporal dementia. *Eur J Nucl Med Mol Imaging* 2008;35:100-6.
  32. Fodero-Tavoletti MT, Cappai R, McLean CA, Pike KE, Adlard PA, Cowie T, et al. Amyloid imaging in Alzheimer's disease and other dementias. *Brain Imaging Behav* 2009;3:246-61.
  33. Rowe CC, Ellis KA, Rimajova M, Bourgeat P, Pike KE, Jones G, et al. Amyloid imaging results from the Australian imaging, biomarkers and lifestyle (AIBL) study of aging. *Neurobiol Aging* 2010;31:1275-83.
  34. Cairns NJ, Ikonovic MD, Benzinger T, Storandt M, Fagan AM, Shah AR, et al. Absence of Pittsburgh compound B detection of cerebral amyloid beta in a patient with clinical, cognitive, and cerebrospinal fluid markers of Alzheimer disease: A case report. *Arch Neurol* 2009;66:1557-62.
  35. Levy-Cooperman N, Burhan AM, Rafi-Tari S, Kusano M, Ramirez J, Caldwell C, et al. Frontal lobe hypoperfusion and depressive symptoms in Alzheimer disease. *J Psychiatry Neurosci* 2008;33:218-26.
  36. Kataoka K, Hashimoto H, Kawabe J, Higashiyama S, Akiyama H, Shimada A, et al. Frontal hypoperfusion in depressed patients with dementia of Alzheimer type demonstrated on 3DSRT. *Psychiatry Clin Neurosci* 2010;64:293-8.
  37. Imran MB, Kawashima R, Awata S, Sato K, Kinomura S, Ono S, et al. Tc-99m HMPAO SPECT in the evaluation of Alzheimer's disease: Correlation between neuropsychiatric evaluation and CBF images. *J Neurol Neurosurg Psychiatry* 1999;66:228-32.