

Case Report

Vas deferens infiltration by prostate cancer on prostate-specific membrane antigen-targeted ^{18}F -DCFPyL positron emission tomography/computed tomography: A unique visual pattern

ABSTRACT

New radiotracers for positron emission tomography imaging that target prostate-specific membrane antigen (PSMA) have emerged as important clinical tools for imaging prostate cancer (PCa). PSMA-targeted radiotracers have demonstrated high sensitivity and high specificity for detecting sites of PCa and are demonstrably superior to conventional imaging modalities such as computed tomography and bone scan. Vas deferens invasion is a rarely encountered poor prognostic feature of PCa. In this case report, we describe a novel pattern of radiotracer uptake in a patient with PCa imaged with PSMA-targeted ^{18}F -DCFPyL positron emission tomography/computed tomography that is consistent with diffuse vas deferens involvement.

Keywords: ^{18}F -DCFPyL, positron emission tomography/computed tomography, prostate cancer, prostate-specific membrane, vas deferens

INTRODUCTION

Prostate cancer (PCa) is the most common noncutaneous malignancy in men and is a leading cause of cancer-related deaths. A number of prognostic features of primary PCa can portend the possibility of treatment failure including high Gleason score, elevated prostate-specific antigen (PSA) level, and direct extension of the tumor beyond the confines of the prostate into the periprostatic soft tissues (pT3a) or the seminal vesicles (pT3b). Although rare, invasion of the vasa deferentia, the paired tubular structures that carry sperm from the epididymis to the urethra, is also a poor prognostic feature of PCa and also falls under the pT3b classification.^[1]

In recent years, the ability to image PCa has improved dramatically as a result of the development of multiple targeted radiotracers for positron emission tomography (PET) imaging. These agents localize to PCa by taking advantage of the metabolic properties of the tumor cells (e.g. 1-amino-3-fluorine 18-fluorocyclobutane-1-carboxylic acid) or by interactions with cell surface receptors that are overexpressed in

PCa (e.g. prostate-specific membrane antigen [PSMA]-targeted radiotracers such as ^{68}Ga -PSMA-11 and ^{18}F -DCFPyL and

**YAFU YIN^{1,2}, CHANNING J. PALLER³,
MARTIN G. POMPER^{1,3,4}, KENNETH J. PIENTA^{3,4},
MICHAEL A. GORIN^{1,3,4}, STEVEN P. ROWE^{1,4}**

¹The Russell H. Morgan Department of Radiology and Radiological Science, Johns Hopkins University School of Medicine, ³Department of Oncology, The Sidney Kimmell Comprehensive Cancer Center, Johns Hopkins University School of Medicine, ⁴Department of Urology, The James Buchanan Brady Urological Institute, Johns Hopkins University School of Medicine, Baltimore, MD, USA, ²Department of Nuclear Medicine, The First Hospital of China Medical University, Shenyang, China


Address for correspondence: Dr. Steven P. Rowe, The Russell H. Morgan Department of Radiology and Radiological Science, Division of Nuclear Medicine and Molecular Imaging, Johns Hopkins University School of Medicine 600 N. Wolfe St., Baltimore, MD 21287, USA.
E-mail: srowe8@jhmi.edu

Submission: 09-05-2018 **Accepted:** 30-05-2018 **Published:** 18-12-2019

This is an open access journal, and articles are distributed under the terms of the Creative Commons Attribution-NonCommercial-ShareAlike 4.0 License, which allows others to remix, tweak, and build upon the work non-commercially, as long as appropriate credit is given and the new creations are licensed under the identical terms.

For reprints contact: reprints@medknow.com

How to cite this article: Yin Y, Paller CJ, Pomper MG, Pienta KJ, Gorin MA, Rowe SP. Vas deferens infiltration by prostate cancer on prostate-specific membrane antigen-targeted ^{18}F -DCFPyL positron emission tomography/computed tomography: A unique visual pattern. *World J Nucl Med* 2019;18:424-7.

Access this article online	
Website: www.wjnm.org	Quick Response Code 
DOI: 10.4103/wjnm.WJNM_50_18	

gastrin-releasing peptide receptor-targeted compounds such as ⁶⁸Ga-RM2). To date, the PSMA-targeted agents have been the most extensively studied and have been found to have very high sensitivities for the detection of suspected sites of PCa.^[2,3] Due to these high sensitivities, the PSMA PCa literature now includes reports of a number of unusual sites of recurrent or residual PCa in the pelvis.^[4-6] Herein, we report an as yet undescribed pattern of disease involvement of the vas deferens in which curvilinear radiotracer uptake outlining the intrapelvic course of the vas deferens was visualized with PSMA-targeted ¹⁸F-DCFPyL PET/computed tomography (CT).

CASE REPORT

The patient was a 71-year-old man who was diagnosed with PCa after presenting with a PSA level of 5.5 ng/mL 5 years before undergoing PSMA-targeted imaging. A prostate biopsy at that time revealed PCa with a Gleason score of 4 + 3 = 7. The patient subsequently underwent a radical retropubic prostatectomy confirming PCa with vasa deferentia invasion, bilateral seminal vesicle invasion, multifocal extraprostatic extension, and lymphovascular invasion. In addition, the patient was found to have positive resection margins at the bilateral vas deferens and seminal vesicles. Initial PSA following prostatectomy was 0.2 ng/mL. The patient was then treated with salvage external beam radiotherapy with 8 months of combined androgen blockade. At that time, his PSA became transiently undetectable. Two years after surgery, the patient experienced a biochemical recurrence with his PSA rising to 12.2 ng/mL.

Workup for his elevated PSA included magnetic resonance imaging of the pelvis and a Na¹⁸F PET/CT scan, neither of which demonstrated a site of disease. He was then treated on a clinical trial with degarelix and his PSA again became undetectable. However, following completion of degarelix therapy, the patient's PSA again rose to 4.1 ng/mL. This prompted an additional workup with conventional imaging including a contrast-enhanced CT of the chest, abdomen, and pelvis as well as a ^{99m}Tc-MDP bone scan, neither of which revealed radiographic evidence of disease. The patient was then enrolled in a prospective trial evaluating the clinical utility of PSMA-targeted ¹⁸F-DCFPyL PET/CT. The patient signed written informed consent prior to imaging. ¹⁸F-DCFPyL PET/CT was conducted under a Food and Drug Administration Investigational New Drug application (IND #121064) with an imaging protocol as previously described.^[7]

The uptake of ¹⁸F-DCFPyL in this patient was in a pattern not previously reported. The entire intrapelvic course

of the left vas deferens was outlined with abnormal intense (maximum lean body mass-corrected standardized uptake value of 11.8) radiotracer uptake [Figures 1 and 2]. The uptake was in a curvilinear distribution extending from the left inguinal canal, through the left side of the pelvis, and ending in the left prostate bed, presumably at the site of the left vas deferens positive margin. A small focus of uptake was also present on the contralateral side and may have been related to the positive right vas deferens margin. Otherwise, no other sites of abnormal radiotracer uptake to suggest additional sites of disease were appreciated on the scan.

DISCUSSION

The increasingly widespread availability of molecular imaging for the detection of sites of PCa has brought to light new patterns of recurrent, residual, and metastatic disease. It is imperative for both imaging specialists and clinicians to be aware of these patterns and to recognize their features. In this report, we describe a novel pattern of ¹⁸F-DCFPyL uptake outlining the entire intrapelvic course of the left vas deferens in a patient with history of prior prostatectomy. The curvilinear morphology of this apparent site of disease is a unique appearance that has not previously been reported. Recognition of this pattern of radiotracer uptake and its significance is important as the unusual configuration could be mistaken for an imaging artifact. Indeed, the correct interpretation of this finding can only be made in the context of an understanding of the cross-sectional anatomy of the vas deferens.

While pathologic confirmation of disease in the patient's left vas deferens is necessary to confirm the diagnosis of PCa, PSMA-targeted agents have been repeatedly shown to have exceedingly high specificities.^[8,9] In addition, many of

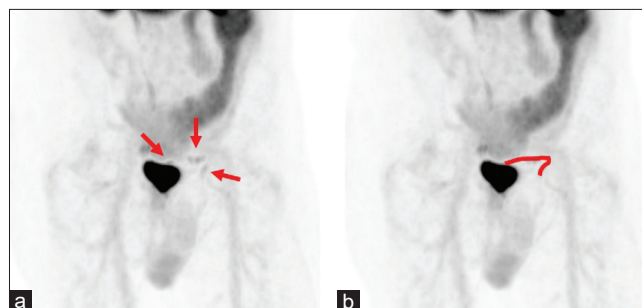

Figure 1: (a) Right anterior oblique maximum intensity projection of the pelvis from a ¹⁸F-DCFPyL PET scan in the 71-year-old male patient with prior history of prostatectomy and previous treatment with androgen deprivation who is described in this case report. Note the curvilinear distribution of radiotracer in the left pelvis (red arrows) that outlines the expected intrapelvic course of the left vas deferens. (b) The same maximum intensity projection as in (a) but with a red line demarcating the approximate location of the intrapelvic left vas deferens

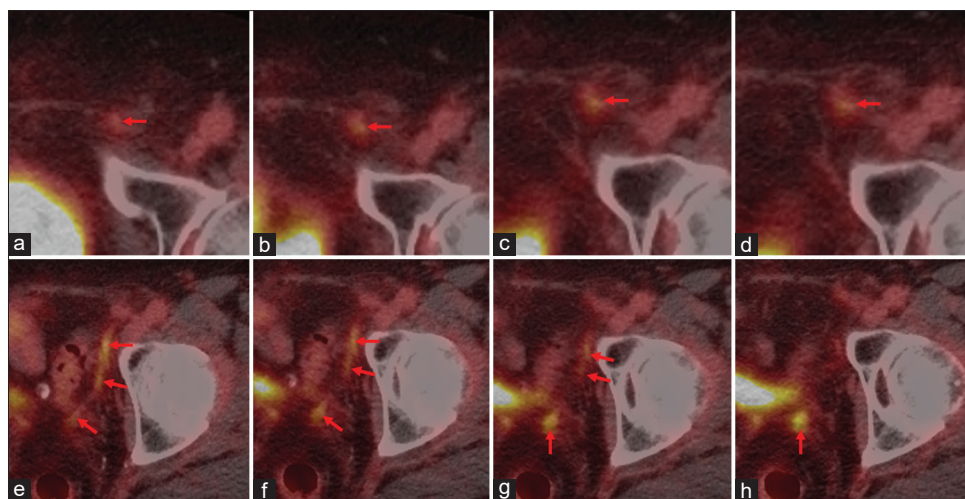


Figure 2: (a-h) Axial fused ¹⁸F-DCFPyL positron emission tomography/computed tomography images of the left pelvis arranged from inferior to superior (a-d) and from superior to inferior (e-h). The uptake in the left vas deferens was in a curvilinear distribution extending from the left inguinal canal (red arrows in [a-d]), through the left side of the pelvis (red arrows in e-g), and ending in the left prostate bed (red arrow in h), presumably at the site of the left vas deferens positive margin

the potential pitfalls for interpretation of these scans have been extensively described.^[10] As such, the possibility of a false positive, in light of the patient's known history of a positive left vas deferens surgical margin, is quite low. In the future, further careful examination of patients undergoing PSMA-targeted PET imaging for a variety of PCa-related indications will ensure that other heretofore unknown patterns of radiotracer uptake will be well described and widely known to those interpreting these scans.

Declaration of patient consent

The authors certify that they have obtained all appropriate patient consent forms. In the form the patient(s) has/have given his/her/their consent for his/her/their images and other clinical information to be reported in the journal. The patients understand that their names and initials will not be published and due efforts will be made to conceal their identity, but anonymity cannot be guaranteed.

Financial support and sponsorship

We gratefully acknowledge funding from Progenics Pharmaceuticals Inc., The Prostate Cancer Foundation Young Investigator Award, and National Institutes of Health grants CA134675 and CA183031.

Conflicts of interest

M.G.P. is a co-inventor on a US patent covering ¹⁸F-DCFPyL and as such is entitled to a portion of any licensing fees and royalties generated by this technology. This arrangement has been reviewed and approved by the Johns Hopkins University in accordance with its conflict of interest policies. M.A.G. has served as a consultant to Progenics Pharmaceuticals, the licensee of ¹⁸F-DCFPyL. K.J.P., M.G.P., M.A.G., and S.P.R. have all

received research funding from Progenics Pharmaceuticals. No other authors have declared any relevant conflicts of interest.

REFERENCES

- Jang WS, Yoon CY, Kim KH, Kang YJ, Shin SJ, Cho NH, *et al.* Prognostic significance of vas deferens invasion after radical prostatectomy in patients with pathological stage T3b prostate cancer. *Ann Surg Oncol* 2017;24:1143-9.
- Rowe SP, Mana-Ay M, Javadi MS, Szabo Z, Leal JP, Pomper MG, *et al.* PSMA-based detection of prostate cancer bone lesions with ¹⁸F-DCFPyL PET/CT: A Sensitive alternative to (^{99m}Tc-MDP bone scan and Na¹⁸F PET/CT? *Clin Genitourin Cancer* 2016;14:e115-8.
- Rowe SP, Macura KJ, Mena E, Blackford AL, Nadal R, Antonarakis ES, *et al.* PSMA-based [(18)F]DCFPyL PET/CT is superior to conventional imaging for lesion detection in patients with metastatic prostate cancer. *Mol Imaging Biol* 2016;18:411-9.
- Rowe SP, Gorin MA, Chu LC, Pienta KJ, Pomper MG, Ross AE, *et al.* An unusual case of penile prostate cancer uncovered by multiparametric MRI and PSMA-targeted ¹⁸F-DCFPyL PET/CT. *Clin Nucl Med* 2017;42:e441-3.
- Polverari G, Ceci F, Graziani T, Cozzarini C, Castellucci P, Fanti S, *et al.* A rare case of epididymal metastasis after radical prostatectomy detected by ⁶⁸Ga-PSMA PET/CT. *Clin Genitourin Cancer* 2017;15:e525-7.
- Phillips RM, Gorin MA, Rowe SP, Pomper MG, Pienta KJ, Ross AE, *et al.* Complete biochemical response after stereotactic ablative radiotherapy of an isolated prostate cancer pelvic soft tissue recurrence detected by ¹⁸F-DCFPyL PET/CT. *Urol Case Rep* 2018;16:86-8.
- Rowe SP, Gorin MA, Hammers HJ, Som Javadi M, Hawasli H, Szabo Z, *et al.* Imaging of metastatic clear cell renal cell carcinoma with PSMA-targeted ¹⁸F-DCFPyL PET/CT. *Ann Nucl Med* 2015;29:877-82.
- Perera M, Papa N, Christidis D, Wetherell D, Hofman MS, Murphy DG, *et al.* Sensitivity, specificity, and predictors of positive ⁶⁸Ga-prostate-specific membrane antigen positron emission tomography in advanced prostate cancer: A systematic review and meta-analysis. *Eur Urol* 2016;70:926-37.
- Gorin MA, Rowe SP, Patel HD, Vidal I, Mana-Ay M, Javadi MS, *et al.*

Prostate specific membrane antigen targeted ¹⁸F-DCFPyL positron emission tomography/computerized tomography for the preoperative staging of high risk prostate cancer: Results of a prospective, phase II, single center study. *J Urol* 2018;199:126-32.

10. Sheikbahaei S, Afshar-Oromieh A, Eiber M, Solnes LB, Javadi MS, Ross AE, *et al.* Pearls and pitfalls in clinical interpretation of prostate-specific membrane antigen (PSMA)-targeted PET imaging. *Eur J Nucl Med Mol Imaging* 2017;44:2117-36.