

Case Report

Radiosynovectomy is a safe and an efficient alternative in the treatment of chronic, recurrent knee hemarthrosis

ABSTRACT

Chronic recurrent hemarthrosis, defined as repeated intra-articular hemorrhage, can lead to a disabling arthropathy. We herein report on a 26-year-old patient presenting with recurrent, postoperative, serious knee hemarthrosis refractory to conventional treatment, including systemic and intra-articular steroid injections as well as chemical synovectomy with osmic acid. The patient was finally treated with a twice performed knee radiosynovectomy with yttrium-90 and showed an extraordinary good clinical outcome with a symptom-free period of 4 years. In cases of refractory hemarthrosis, radiosynovectomy should have a place in the therapeutic armamentarium of the treating physician, as a minimally invasive, safe, and efficient therapeutic tool.

Keywords: Radiosynovectomy, refractory knee hemarthrosis, yttrium-90

INTRODUCTION

Chronic recurrent hemarthrosis, defined as repeated intra-articular hemorrhage, can lead to a disabling arthropathy. The most common cause of knee hemarthrosis is injury, followed by bleeding disorders, osteoarthritis, postoperative complications, neuropathic arthropathy, vascular disorders, and tumors.^[1] The treatment of hemarthrosis involves joint immobilization, nonsteroidal anti-inflammatory drugs (NSAIDs), and aspiration, until cause-specific interventions – if any – are employed.^[2]

Radiosynovectomy is a minimally invasive, low-cost procedure for the treatment of a range of refractory painful synovitis.^[3] In hemarthrosis, radiosynovectomy is safe and effective in the treatment of chronic, recurrent disease, mostly in the context of hemophilic arthropathy.^[4,5] We herein report a case of recurrent, postoperative knee hemarthrosis refractory to conventional treatment, but successfully treated with radiosynoviorthesis.

CASE REPORT

A 26-year-old male handworker with a history of surgically treated pigmented villonodular synovitis (PVNS) of the right

knee 2 years ago presented in the orthopedics clinic with right knee hemarthrosis. On initial examination, his knee showed an inability of full weight-bearing, and the range of motion was limited to 30°. After a joint aspiration of 120 ml of blood, the patient was treated with NSAIDs, which led to a symptom relief for 15 days. However, during the following 5 months, he experienced six more episodes of hemarthrosis, two of which required arthrocentesis. Microorganism culture was negative, while the cytological examination showed hemorrhagic items and chronic inflammatory response. In a search for potential bleeding disorders, the patient underwent a series of blood tests including complete

IOANNIS IAKOVOU, DIMITRIOS KOTROTSIOS, KONSTANTINOS MICHAÏLOS, CHRISTOS SACHPEKIDIS¹

Department of Nuclear Medicine, Papageorgiou Hospital, Aristotle University of Thessaloniki, Thessaloniki, Greece,

¹Department of Nuclear Medicine, Inselspital, Bern University Hospital, Bern, Switzerland


Address for correspondence: Prof. Ioannis Iakovou, Department of Nuclear Medicine, Papageorgiou Hospital, Aristotle University of Thessaloniki, Ring Road, Nea Efkarpia, Thessaloniki 56429, Greece.
E-mail: iiakovou@icloud.com

Submission: 28-Mar-19, **Accepted:** 17-Jul-19, **Published:** 17-Jan-20

This is an open access journal, and articles are distributed under the terms of the Creative Commons Attribution-NonCommercial-ShareAlike 4.0 License, which allows others to remix, tweak, and build upon the work non-commercially, as long as appropriate credit is given and the new creations are licensed under the identical terms.

For reprints contact: reprints@medknow.com

How to cite this article: Iakovou I, Kotrotsios D, Michailos K, Sachpekidis C. Radiosynovectomy is a safe and an efficient alternative in the treatment of chronic, recurrent knee hemarthrosis. World J Nucl Med 2020;19:165-7.

Access this article online	
Website: www.wjnm.org	Quick Response Code 
DOI: 10.4103/wjnm.WJNM_43_19	

blood count, platelet aggregation test, and bleeding time test, which were all negative. A knee magnetic resonance imaging (MRI) was performed after the 2nd arthrocentesis, which showed an anterior cruciate ligament graft tension relaxation and arthritis.

As a next diagnostic step, an arthroscopy was decided, during which synovial biopsy and synovial fluid analysis was performed. The results of the synovial biopsy revealed chronic synovitis and hemochromatosis. The patient remained symptom free for 1 month but relapsed again with a sudden episode of hemarthrosis during walking. Despite the performance of a joint aspiration of 100 ml of blood and the intra-articular injection of betamethasone, the symptoms persisted. In this context, a vascular dysplasia was suspected, but MRI angiography was negative. A second arthroscopy revealed no specific cause. Osmic acid synovectomy of the knee was performed, but after a short period of symptom alleviation, knee hemarthrosis relapsed [Figure 1].

After the failure of all the above-mentioned diagnostic and therapeutic approaches, a knee radiosynoviorthesis with the radioisotope yttrium-90 (⁹⁰Y) as symptomatic treatment was suggested. The aim of the therapy was to diminish the hemorrhagic synovium. The patient had a preradiosynovectomy three-phase bone scintigraphy, which confirmed increased ^{99m}Tc-MDP uptake in the blood pool phase, as a sign of inflammation [Figure 2].

The radiosynovectomy procedure was performed under strict aseptic conditions. After local lidocaine injection for analgesia, excess joint fluid was drained, and 5 mCi of ⁹⁰Y was injected intra-articularly into the knee joint followed by the administration of 20 mg of triamcinolone acetonide to diminish the risk of an acute inflammatory response and to prevent radiopharmaceutical skin contamination from the removal of the needle. Immediately after ⁹⁰Y application, static imaging of the ankle joint was performed to demonstrate the distribution of the radiopharmaceutical in the joint and exclude potential extra-articular leakage [Figure 3].

The patient was in stillness for the next 48 h and was instructed to avoid strenuous physical activity during the 1st day after treatment. Gradually, he followed a program of mobilization and empowerment with improvement of his symptoms as early as 1 month after the first radiosynovectomy. However, due to residual joint effusion, the second radiosynovectomy was performed 6 months later, following the same procedure. Soon after application of the second synovectomy, the patient's symptoms almost completely subsided, and he returned to his work. More than

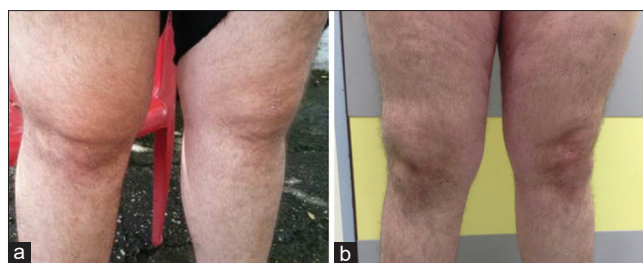

Figure 1: Image of the affected knee before (a) and after (b) radiosynovectomy. Before treatment, marked swelling due to hemarthrosis is demonstrated (a), which is substantially decreased after radiosynovectomy (b)

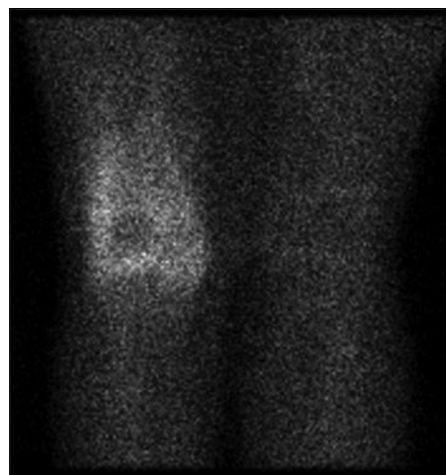


Figure 2: Blood pool imaging with ^{99m}Tc-MDP of the knee before radiosynovectomy, demonstrating increased tracer uptake in the affected right knee joint as a sign of inflammation

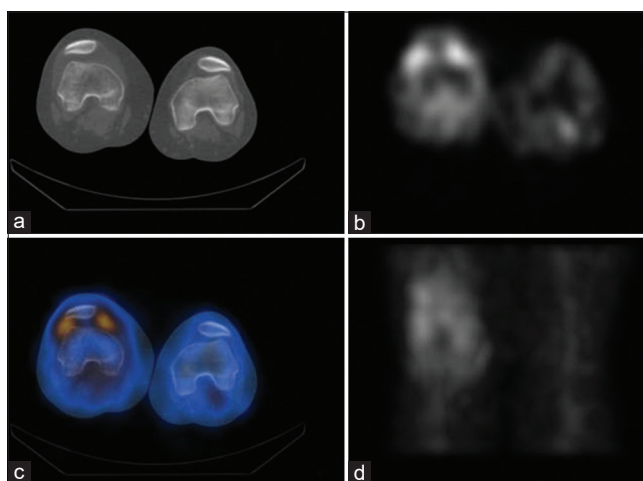


Figure 3: Static imaging of the knee joint performed immediately after yttrium-90 radiosynovectomy for the demonstration of radiopharmaceutical distribution in the right knee joint. Sagittal computed tomography (a), sagittal single-photon emission computed tomography (b), fused single-photon emission computed tomography/computed tomography (c), and coronal single-photon emission computed tomography (d) of the knee. Imaging excluded potential extra-articular leakage of yttrium-90. Due to the lack of gamma emission from the radiotracer yttrium-90, imaging was performed with coadministration of 5 mCi of ^{99m}Tc

4 years after of the radiosynovectomy, the patient remains symptom – free, functional and is working on a full-time

schedule [Figure 1]. No side effects were reported with both radiosynovectomy procedures.

DISCUSSION

We herein presented a case of repeated, severe knee hemarthrosis in a patient with surgically treated PVNS of the knee 2 years ago. These bleeding events occurred spontaneously or after minimal joint stress. In this context, a bleeding disorders investigation was initiated since spontaneous hemarthrosis is the most common manifestation of hemophilia.^[6] However, blood tests were negative for bleeding disorders; moreover, the investigation for other causes did not lead to a definitive cause for the hemarthrosis. The patient was treated with several interventions including blood aspirations, intra-articular steroid injections, NSAIDs, and an osmic acid synovectomy, which failed, however, to lead to a long-term symptom relief. The solution was finally given by a twice performed knee radiosynovectomy with ⁹⁰Y, leading to an extraordinary good clinical outcome with a symptom-free period of more than 4 years.

Radiosynovectomy is an established therapy for a series of inflammatory joint conditions including rheumatoid arthritis, undifferentiated arthritis characterized by synovitis, ankylosing spondylitis, psoriatic arthritis, hemophilic arthritis, PVNS, and osteoarthritis characterized by synovitis.^[7] Although not a first-line treatment, radiosynovectomy is considered nowadays a safe, minimally invasive, and an effective alternative for the treatment of hemarthrosis, mainly in hemophilic patients.^[4,5,8,9] The treatment is based on the intra-articular application of β -emitting radionuclides with a very short therapeutic range in the affected joint and their subsequent phagocytosis by macrophages and other inflammatory cells in the articular cavity. Radiation from the applied isotope results in fibrosis and necrosis of the superficial synovial layers, delaying joint destruction.^[10]

CONCLUSION

In this case, we show for the first time the safety and outstanding efficacy of a twice performed radiosynovectomy in a young patient with repeated, serious knee hemarthrosis, possibly due to the surgically treated PVNS 2 years ago and refractory to conventional treatment. Although not considered a cause-specific intervention, radiosynovectomy led to a very satisfying clinical response, including an

ongoing, symptom-free period of 4 years with substantial improvement of the patients' quality of life without any side effects. Thus, in cases of refractory hemarthrosis, this minimally invasive, safe, and low-cost treatment should have a place in the therapeutic armamentarium of the treating physician.

Declaration of patient consent

The authors certify that they have obtained all appropriate patient consent forms. In the form the patient(s) has/have given his/her/their consent for his/her/their images and other clinical information to be reported in the journal. The patients understand that their names and initials will not be published and due efforts will be made to conceal their identity, but anonymity cannot be guaranteed.

Financial support and sponsorship

Nil.

Conflicts of interest

There are no conflicts of interest.

REFERENCES

- Maffulli N, Binfield PM, King JB, Good CJ. Acute haemarthrosis of the knee in athletes. A prospective study of 106 cases. *J Bone Joint Surg Br* 1993;75:945-9.
- Nigrovic PA. Overview of hemarthrosis. In: Helfgott SM, Romain PL, editors, *Up To Date*; 2019. Available from: <https://www.uptodate.com/contents/overview-of-hemarthrosis>. [Last retrieved on 2019 Mar 22].
- Fellinger K, Schmid J. Local therapy of rheumatic diseases. *Wien Z Inn Med* 1952;33:351-63.
- Molho P, Verrier P, Stieltjes N, Schacher JM, Ounnoughène N, Vassilieff D, et al. A retrospective study on chemical and radioactive synovectomy in severe haemophilia patients with recurrent haemarthrosis. *Haemophilia* 1999;5:115-23.
- Raffini L, Manno C. Modern management of haemophilic arthropathy. *Br J Haematol* 2007;136:777-87.
- Lan HH, Eustace SJ, Dorfman D. Hemophilic arthropathy. *Radiol Clin North Am* 1996;34:446-50.
- Knut L. Radiosynovectomy in the therapeutic management of arthritis. *World J Nucl Med* 2015;14:10-5.
- Fernandez-Palazzi F, Caviglia H. On the safety of synoviorthesis in haemophilia. *Haemophilia* 2001;7 Suppl 2:50-3.
- Sabet A, Strauss AC, Schmolders J, Bornemann R, Sabet A, Oldenburg J, et al. Radiosynoviorthesis in hemophilic arthropathy: Pathologic blood pool imaging on pre-therapeutic bone scintigraphy is not a predictor of treatment success. *Eur J Nucl Med Mol Imaging* 2017;44:461-7.
- van der Zant FM, Boer RO, Moolenburgh JD, Jahangier ZN, Bijlsma JW, Jacobs JW, et al. Radiation synovectomy with (90)Yttrium, (186)Rhenium and (169)Erbium: A systematic literature review with meta-analyses. *Clin Exp Rheumatol* 2009;27:130-9.