

Case Report

Graves' disease: A rare fate of Hashimoto's thyroiditis

ABSTRACT

Hashimoto's thyroiditis is a known autoimmune disorder that leads to chronic inflammation of the thyroid gland, with a gradual decline in function and eventual hypothyroidism. Conversion of Hashimoto's thyroiditis to Graves' disease is unusual clinically and has been occasionally reported in the literature. Awareness of such a rare phenomenon is important for the physicians evaluating patients with autoimmune thyroid disorders. Close investigation of the patient's symptoms and biochemical status is crucial in the implementation of appropriate treatment.

Keywords: Autoimmune disorder, Graves' disease, Hashimoto's thyroiditis

INTRODUCTION

Hashimoto's thyroiditis is a common autoimmune thyroid disorder, with a preponderance in the female population.^[1] A combination of genetic and environmental factors are thought to be related to the formation of autoantibodies against thyroid antigens, specifically thyroid-stimulating hormone receptor (TSH-R), thyroperoxidase, and thyroglobulin (Tg); causing gradual destruction of the thyroid gland and concomitant decline in gland function. The consequential gland atrophy leads to hypothyroidism, which can be seen in about 20%–30% of affected cases.^[2] Graves' disease, in contrast, has a distinct pathological mechanism and is usually caused by antithyrotropin receptor antibodies, which overstimulate TSH-R resulting in hypertrophy and upsurge in the function of the thyroid gland. A potential transformation of Hashimoto's thyroiditis to Graves' disease is a rare and intriguing phenomenon. Herein, we present one such case of Hashimoto's thyroiditis, which transformed to Graves' disease within 5 years, requiring radioiodine ablation therapy.

CASE REPORT

A 32-year-old female presented with symptoms of low energy level, weight gain, cold intolerance, increased bowel movements, flaking, and itchy scalp in the year 2014. On examination, she was found to have a palpable goiter. Her family history was significant for thyroid disease affecting

her sibling. Neck ultrasound demonstrated diffusely enlarged thyroid with mild heterogeneous echotexture and left hypoechoic solid nodule measuring 0.75 cm [Figure 1]. Thyroid function test (TFT) was within the normal limits (TSH: 3.4 μ IU/mL and FT4: 1.1 ng/dL; normal laboratory values of TSH 0.350–4.940 uIU/mL and FT4: 0.7–1.5 ng/dL respectively) however, antithyroid peroxidase (1446.0 IU/ml; reference range 0.0–5.6 IU/ml) and Tg antibodies (95.4 IU/ml; reference range 0.0–4.1 IU/ml) were high. A diagnosis of euthyroid Hashimoto's disease was made, and the patient was followed up on ultrasound and TFT.

In the year 2016, the patient presented with irritability and anxiety. Repeat ultrasound showed status quo. However, there was a surge in thyroid antibodies and an increase in TSH levels (7.2 μ IU/mL). The clinical impression was consistent

RAHUL JADHAV, MOHAMMAD ALBERAWI¹, KHUSHBOO GUPTA¹

Rush University Medical Center, ¹Department of Diagnostic Radiology and Nuclear Medicine, Rush University Medical Center, Chicago, IL, USA


Address for correspondence: Dr. Khushboo Gupta, Department of Diagnostic Radiology and Nuclear Medicine, Rush University Medical Center, Chicago, IL 60612, USA. E-mail: Khushboo_Gupta@rush.edu

Submitted: 24-Mar-2020, **Revised:** 07-Jul-2020, **Accepted:** 26-May-2020, **Published:** 23-Oct-2020

This is an open access journal, and articles are distributed under the terms of the Creative Commons Attribution-NonCommercial-ShareAlike 4.0 License, which allows others to remix, tweak, and build upon the work non-commercially, as long as appropriate credit is given and the new creations are licensed under the identical terms.

For reprints contact: WKHLRPMedknow_reprints@wolterskluwer.com

How to cite this article: Jadhav R, Alberawi M, Gupta K. Graves' disease: A rare fate of Hashimoto's thyroiditis. World J Nucl Med 2021;20:102-4.

Access this article online	
Website: www.wjnm.org	Quick Response Code 
DOI: 10.4103/wjnm.WJNM_34_20	

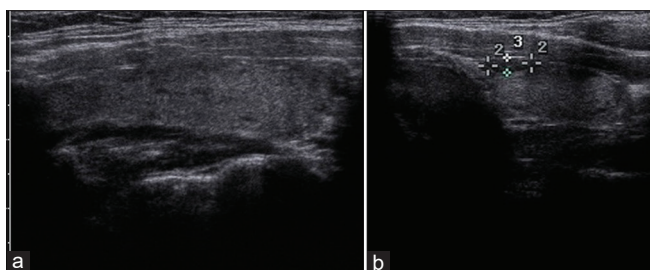


Figure 1: Ultrasound neck images (a: right lobe of thyroid and b: left lobe of thyroid) demonstrating diffusely enlarged thyroid gland with mild heterogeneous echotexture and 0.38 cm × 0.75 cm × 0.26 cm hypochoic solid nodule in left lobe

with Hashimoto's thyroiditis and the patient was started on low-dose thyroxine, which she tolerated well for 3 years. On yearly follow-up, there was a downtrend in thyroid antibodies, TSH returned to normal range, and findings on ultrasound remained stable.

In October 2019, the patient presented with syncopal episode. Evaluation of TFT demonstrated low TSH of 0.003 μ U/mL and raised FT4 of 2.4 ng/dL. The patient was asked to stop thyroxine tablets and to repeat TFTs in 4 weeks. Repeat TSH was <0.002 μ U/mL and FT4 of 2.6 ng/dL. I-123 thyroid uptake and the scan was performed, which demonstrated findings consistent with Graves' disease [Figure 2] with 24 h uptake of 63.6% (normal range 10%–25%). The patient was subsequently treated with 15.9 mCi of radioiodine (I-131). Follow-up in 6 weeks of radioiodine therapy, the patient was clinically stable.

DISCUSSION

The above case report demonstrated flipping of hormones from inhibitory to stimulatory within 5 years, a rarity which has been cited a few times in world literature. Multiple theories have been postulated explaining this phenomenon. Gavras' and Thomson documented two cases of Hashimoto's thyroiditis who converted to hyperthyroidism while on thyroxine therapy.^[3] Takasu *et al.* presented a case series of 8 patients and believed disturbed balance between stimulatory and inhibitory antibodies to be the cause of the unusual conversion.^[4] Furqan *et al.* hypothesized that recovery of the gland from Hashimoto's thyroiditis injury might gradually lead to an overt response to thyroid-stimulating antibodies, causing hyperfunctioning gland.^[5] Immunomodulation related to age, pregnancy status, or drugs such as Alemtuzumab are also considered contributory.^[6]

Both Hashimoto's thyroiditis and Graves' disease diffusely involve the parenchyma of the thyroid gland. Clinical

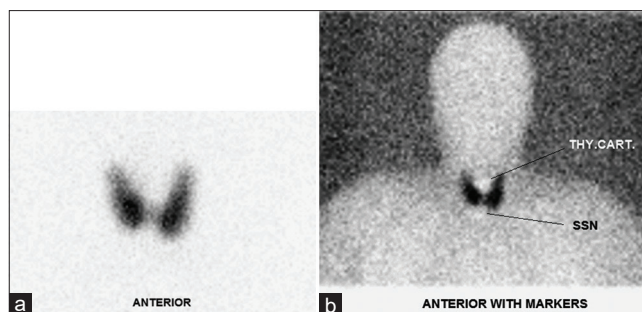


Figure 2: (a and b) Anterior planar image of I-123 thyroid uptake and scan demonstrating diffusely enlarged thyroid gland with homogeneous tracer uptake in both lobes of thyroid. 24-h uptake was measured at 63.6%

manifestations are enough to differentiate between the two diseases; however, clinicians often need diagnostic modalities to confirm the same. Biochemical test, ultrasound, and nuclear medicine exams aid in diagnosis, of which nuclear medicine examinations are of importance in therapy decision for this subset of patients. Demonstration of diffuse hyperfunctioning gland on I-123 thyroid uptake and scan is the hallmark of Graves' disease. The scan also forms a fundamental basis for the treatment of Graves' disease with I-131 radiopharmaceutical, the most recommended therapy for such disorders.

Screening for autoimmune thyroid disease has led to various new genetic tests for early determination of patients at risk.^[7] New imaging frontiers such as ¹⁸F-fluorodeoxyglucose positron emission tomography-computed tomography scans may assess thyroid lesions and are being evaluated for the management of autoimmune thyroid disease.^[8,9] Interestingly, the underlying pathophysiology of this autoimmune disorder and clinical conversion remains unresolved. Deeper insights into biochemical alterations, innovative diagnostic modalities, and extensive epidemiologic studies would be required to further comprehend this phenomenon and increase the quality of care.

Declaration of patient consent

The authors certify that they have obtained all appropriate patient consent forms. In the form the patient(s) has/have given his/her/their consent for his/her/their images and other clinical information to be reported in the journal. The patients understand that their names and initials will not be published and due efforts will be made to conceal their identity, but anonymity cannot bechrological order guaranteed.

Financial support and sponsorship

Nil.

Conflicts of interest

There are no conflicts of interest.

REFERENCES

1. Tunbridge WM, Evered DC, Hall R, Appleton D, Brewis M, Clark F, *et al.* The spectrum of thyroid disease in a community: The Wickham survey. *Clin Endocrinol (Oxf)* 1977;7:481-93.
2. McLeod DS, Cooper DS. The incidence and prevalence of thyroid autoimmunity. *Endocrine* 2012;42:252-65.
3. Gavras L, Thomson JA. Late thyrotoxicosis complicating autoimmune thyroiditis. *Acta Endocrinol* 1972;69:44-6.
4. Takasu N, Yamada T, Sato A, Nakagawa M, Komiya I, Nagasawa Y, *et al.* Graves' disease following hypothyroidism due to Hashimoto's disease: Studies of eight cases. *Clin Endocrinol* 1990;33:687-98.
5. Furqan S, Haque NU, Islam N. Conversion of autoimmune hypothyroidism to hyperthyroidism. *BMC Res Notes* 2014;7:489.
6. Kamath C, Young S, Kabelis K, Sanders J, Adlan MA, Furmaniak J, *et al.* Thyrotrophin receptor antibody characteristics in a woman with long-standing Hashimoto's who developed Graves' disease and pretibial myxoedema. *Clin Endocrinol (Oxf)* 2012;77:465-70.
7. Latif R, Yin X. New genetic insights from autoimmune thyroid disease. *J Thyroid Res* 2012;2012:623852.
8. Gupta K, Jadhav R, Prasad R, Virmani R, Singh J, Ali A, *et al.* Variable 18F FDG uptake patterns in thyroid disorders and its correlative imaging a case based pictorial review. *J Nucl Med* 2017;58:1003.
9. Małkowski B, Serafin Z, Glonek R, Suwała S, Łopatto R, Junik R. The role of 18F-FDG PET/CT in the management of the autoimmune thyroid diseases. *Front Endocrinol (Lausanne)* 2019;10:208.