

Case Report

Solitary late metastasis of primary renal cell carcinoid tumor to the extraocular muscles imaged with indium-111 octreotide

ABSTRACT

A 75-year-old male presented with right eye pain and proptosis. His history was significant for renal cell carcinoma treated with left nephrectomy 2 years previously. Computed tomography (CT) imaging demonstrated a 1.6-cm enhancing lesion in the right retrobulbar space. Surgical biopsy revealed a low-grade metastatic carcinoid tumor. At retrospective review, the primary renal lesion from 2 years prior was rediagnosed as consistent with a renal carcinoid tumor. Indium-111 octreotide single photon emission CT/CT imaging demonstrated a solitary metastasis within the right extraocular muscles. The patient subsequently developed additional metastases within the remaining right kidney and lung.

Keywords: Indium-111 octreotide, ocular metastasis, renal carcinoid tumor

INTRODUCTION

Carcinoid tumours are a type of neuroendocrine tumour that most commonly arise from the gastrointestinal tract. They are usually slow growing but may present with metastasis.^[1] This case details a carcinoid tumour arising from the kidney, which is an uncommon location, and presenting with a rare site of metastasis – the extraocular muscles.

CASE REPORT

A 75-year-old male presented with right eye pain and proptosis. His medical history was significant for left nephrectomy for “papillary renal cell carcinoma” (RCC) 2 years previously. Computed tomography (CT) at that time demonstrated a 9.5-cm mixed attenuation lesion in the left kidney consisting of a solid component and intralesional hemorrhage as an incidental finding during the investigation of an episode of acute diverticulitis. Left nephrectomy was performed, and histology was reported as a 2.5-cm papillary RCC with hemorrhagic component.

On this admission, contrast CT of the orbits demonstrated an enhancing 1.6-cm lesion in the right retrobulbar space

[Figure 1a and b]. Surgical biopsy revealed a metastatic low-grade neuroendocrine tumor. Immunohistochemistry was positive for chromogranin and synaptophysin with a proliferation index of 5%. Hydroxyindoleacetic acid was normal at 33 (normal range 2.5–50 $\mu\text{mol}/24\text{ h}$). Subsequent review of the initial left kidney histology with immunohistochemistry revealed a similar morphology to the metastatic deposit in the extraocular muscle, and this was retrospectively reclassified as a low-grade carcinoid tumor. Indium-111 (In-111) octreotide planar and single photon emission CT/CT imaging [Figure 1c-e] at 24 h demonstrated a solitary metastasis in the right retro-orbital soft tissues.

PHILIP JUDE DEMPSEY, MARTIN J O’CONNELL, FERDIA BOLSTER

Department of Radiology, Mater Misericordiae University Hospital, Dublin, Ireland


Address for correspondence: Dr. Philip Jude Dempsey, 1 Mater Misericordiae University Hospital, Eccles Street, Dublin 7, Ireland.
E-mail: philipjdempsey@gmail.com

Submitted: 17-Mar-2020, **Revised:** 07-Apr-2020,
Accepted: 01-May-2020, **Published:** 22-Jul-2020

This is an open access journal, and articles are distributed under the terms of the Creative Commons Attribution-NonCommercial-ShareAlike 4.0 License, which allows others to remix, tweak, and build upon the work non-commercially, as long as appropriate credit is given and the new creations are licensed under the identical terms.

For reprints contact: WKHLRPMedknow_reprints@wolterskluwer.com

How to cite this article: Dempsey PJ, O’Connell MJ, Bolster F. Solitary late metastasis of primary renal cell carcinoid tumor to the extraocular muscles imaged with indium-111 octreotide. World J Nucl Med 2021;20:99-101.

Access this article online	
Website: www.wjnm.org	Quick Response Code 
DOI: 10.4103/wjnm.WJNM_28_20	

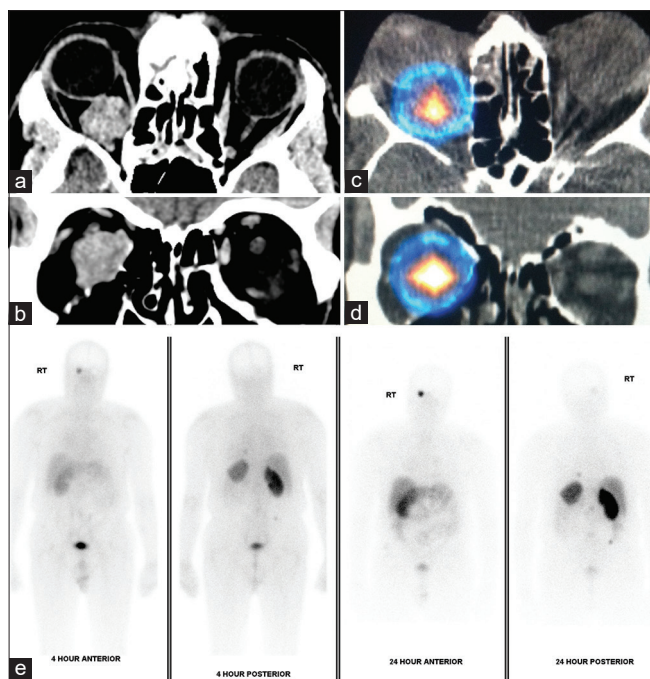


Figure 1: Image panel – Contrast-enhanced computed tomography identifies a mass in the right retrobulbar space on axial and coronal slices (left upper images, a and b). Single photon emission computed tomography/computed tomography and planar indium-111 octreotide demonstrates a solitary metastatic deposit (right upper and bottom row images, c-e)

As the patient was systemically well and histology identified a low-grade tumor, initial treatment was with radiotherapy to the orbital metastasis for symptomatic and local control. The patient remained well on 3-monthly surveillance; however, follow-up octreotide imaging 2 years later demonstrated the development of metastatic disease with avid right renal and pulmonary lesions [Figure 2], at which time systemic treatment with octreotide was commenced.

Carcinoid tumors of the renal origin are extremely rare. 28.6% of cases are diagnosed as an incidental finding in asymptomatic patients.^[1-4] In a relatively large series ($n = 56$), renal carcinoid was misdiagnosed initially as RCC in 15% of cases.^[2] A clinicopathological case series reported similar findings - for example, a renal carcinoid was initially diagnosed as papillary RCC due to a “pseudopapillary” appearance but subsequently reclassified after examination of a metastatic liver deposit.^[5] Carcinoid tumors occur mostly occur in the gastrointestinal tract or bronchial system of the lungs. Primary genitourinary carcinoids occur in <1%.^[2,6] Liver metastases are most common and can lead to carcinoid syndrome and right-sided valvular heart disease. While ⁶⁸gallium-labeled somatostatin analogs have become the current standard practice,^[7] In-111-labeled octreotide provided the sufficient information to establish a diagnosis in this case. To our knowledge, this is the first

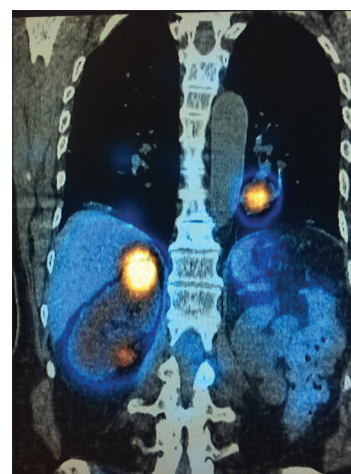


Figure 2: Follow-up single photon emission computed tomography/computed tomography imaging with indium-111-labeled octreotide demonstrates progression of metastatic disease, with two octreotide avid metastatic tumor deposits in the (contralateral) right kidney, which developed 2 years subsequently. An octreotide avid pulmonary metastasis is noted in the left lung

case to describe isolated extraocular muscle metastasis from a primary carcinoid tumor with In-111-labeled octreotide, or with ⁶⁸gallium-labeled somatostatin analogs.^[8] Metastases to the orbits have been reported as small case series or case reports but typically occur in the setting of advanced metastatic disease and affect more than one extraocular muscle.^[5,9,10]

Declaration of patient consent

The authors certify that they have obtained all appropriate patient consent forms. In the form the patient(s) has/have given his/her/their consent for his/her/their images and other clinical information to be reported in the journal. The patients understand that their names and initials will not be published and due efforts will be made to conceal their identity, but anonymity cannot be guaranteed.

Financial support and sponsorship

Nil.

Conflicts of interest

There are no conflicts of interest.

REFERENCES

- Intenzo CM, Jabbar S, Lin HC, Miller JL, Kim SM, Capuzzi DM, *et al.* Scintigraphic imaging of body neuroendocrine tumors. *Radiographics* 2007;27:1355-69.
- Romero FR, Rais-Bahrami S, Permpongkosol S, Fine SW, Kohanim S, Jarrett TW. Primary carcinoid tumors of the kidney. *J Urol* 2006;176:2359-66.
- Omiyale AO, Venyo AK. Primary carcinoid tumour of the kidney: A review of the literature. *Adv Urol* 2013;2013:579396-11.

4. Korkmaz T, Seber S, Yavuzer D, Gumus M, Turhal NS. Primary renal carcinoid: Treatment and prognosis. *Crit Rev Oncol Hematol* 2013;87:256-64.
5. Lane BR, Chery F, Jour G, Sercia L, Magi-Galluzzi C, Novick AC, *et al.* Renal neuroendocrine tumours: A clinicopathological study. *BJU Int* 2007;100:1030-5.
6. Matsuo T, Ichimura K, Tanaka T, Takenaka T, Nakayama T. Neuroendocrine tumor (carcinoid) metastatic to orbital extraocular muscle: Case report and literature review. *Strabismus* 2010;18:123-8.
7. Bergeret S, Charbit J, Ansquer C, Bera G, Chanson P, Lussey-Lepoutre C. Novel PET tracers: Added value for endocrine disorders. *Endocrine* 2019;64:14-30.
8. Naswa N, Sharma P, Kumar R, Malhotra A, Bal C. Usual and unusual neuroendocrine tumor metastases on (68)Ga-DOTANOC PET/CT: A pictorial review. *Clin Nucl Med* 2013;38:e239-45.
9. Gupta A, Chazen JL, Phillips CD. Carcinoid tumor metastases to the extraocular muscles: MR imaging and CT findings and review of the literature. *AJNR Am J Neuroradiol* 2011;32:1208-11.
10. Scarsbrook AF, Ganeshan A, Statham J, Thakker RV, Weaver A, Talbot D, *et al.* Anatomic and functional imaging of metastatic carcinoid tumors. *Radiographics* 2007;27:455-77.