

Interesting Cases

Contribution of radiobiphosphonates bone scan in multifocal tuberculous osteomyelitis

ABSTRACT

We share the case of a 86-year-old male patient, followed up for recent left hip pain. Interrogation revealed a fever, nocturnal shivering, and bone pains. Standard radiographs and computed tomography centered on both shoulders and pelvis showed osteoarthritis of the left hip and multiple lytic lesions in both humeral heads and clavicles, suggestive of chronic infectious, metabolic, or secondary disease. Bone scan with radiobiphosphonates showed intense and diffuse uptake in the clavicles, the two humeral heads, and at the cervical and dorsal spine. Biopsy of the left humeral head confirmed the diagnosis of tuberculous osteomyelitis, showing an aspect of caseo-follicular tuberculosis. Bone scan with radiobiphosphonates can be used in our context to search other localizations falling within the framework of a polystotic form, and also to guide nonrisk biopsy in such group of patients.

Keywords: Bone scan, multifocal osteomyelitis, tuberculous osteomyelitis

INTRODUCTION

Clavicular tuberculosis is one of the rare forms of tuberculous osteomyelitis, and has sometimes misleading radio-clinical aspects. Through this observation, authors highlight the diagnostic difficulties and the important role of radiobiphosphonates bone scan in the orientation diagnostic of this pathology.

CASE REPORT

We report the case of a 86-year-old male patient, followed up for recent left hip pain limiting flexion and extension movements, suggestive of hip osteoarthritis or osteonecrosis of the left femoral head. Interrogation revealed a fever, nocturnal shivering, and bone pains. Standard radiographics [Figure 1] and computed tomography [Figure 2] centered on both shoulders and pelvis showed osteoarthritis of the left hip and multiple lytic lesions in both humeral heads and both clavicles, suggestive of chronic infectious, metabolic, or secondary disease.

Bone scintigraphy showed, 2 h after intravenous injection of 740 MBq of methyl diphosphonates, an intense and diffuse

uptake in the clavicles, the two humeral heads, and at the cervical and dorsal spine [Figure 3].

Spinal magnetic resonance imaging showed spondylodiscitis suggestive of Pott's disease. Biopsy of the left humeral head confirmed the diagnosis, showing an aspect of caseo-follicular tuberculosis [Figure 4]. Our patient was put under antituberculous treatment according to the 2 RHZ/4 RH protocol with good clinical and radiological evolution.

SALAH OUERAGLI NABIH, OMAR AIT SAHEL, YASSIR BENAMEUR, ABDERRAHIM DOUDOUH

Department of Nuclear Medicine, Mohammed V Military Teaching Hospital, Rabat, Morocco


Address for correspondence: Dr. Salah Oueriagli Nabih, Department of Nuclear Medicine, Mohammed V Military Teaching Hospital, BP 1018, Rabat, Morocco.
E-mail: salah.nabihoueriagli@gmail.com

Submitted: 05-Mar-2020, **Revised:** 20-Apr-2020, **Accepted:** 10-May-2020, **Published:** 11-Jun-2020

This is an open access journal, and articles are distributed under the terms of the Creative Commons Attribution-NonCommercial-ShareAlike 4.0 License, which allows others to remix, tweak, and build upon the work non-commercially, as long as appropriate credit is given and the new creations are licensed under the identical terms.

For reprints contact: reprints@medknow.com

How to cite this article: Nabih SO, Sahel OA, Benameur Y, Doudouh A. Contribution of radiobiphosphonates bone scan in multifocal tuberculous osteomyelitis. World J Nucl Med 2020;19:184-6.

Access this article online	
Website: www.wjnm.org	Quick Response Code 
DOI: 10.4103/wjnm.WJNM_20_20	

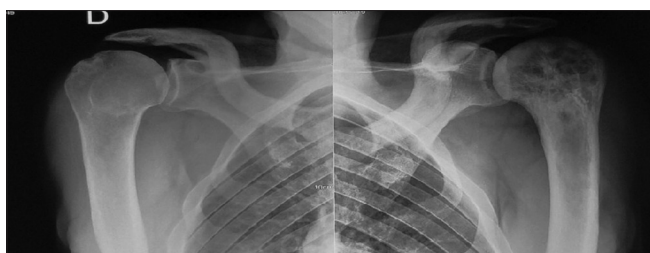


Figure 1: Standard radiographs of the two shoulders showing lacunar lesions in both humeral heads and both clavicles, suggestive of chronic infectious, metabolic, or secondary disease

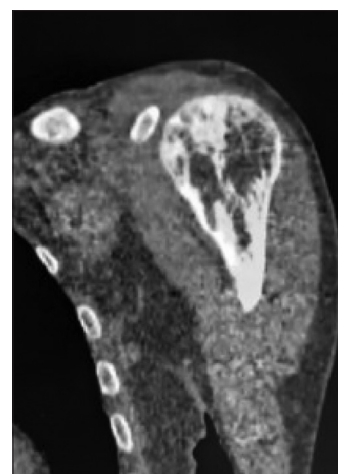


Figure 2: Computed tomography in the coronal section centered on the left shoulder showing multiple lytic lesions in the left humeral head

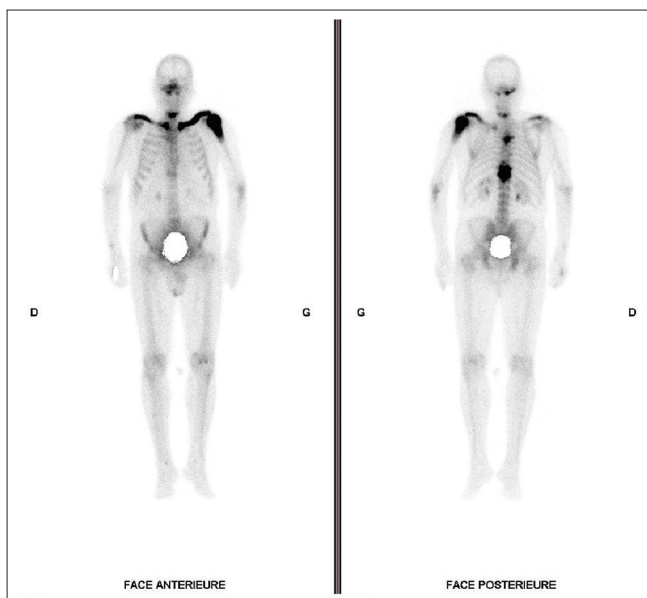

Figure 3: Whole-body bone scan with radiobiphosphonates showing intense and diffuse uptake in the clavicles, the two humeral heads, and the cervical and dorsal spine

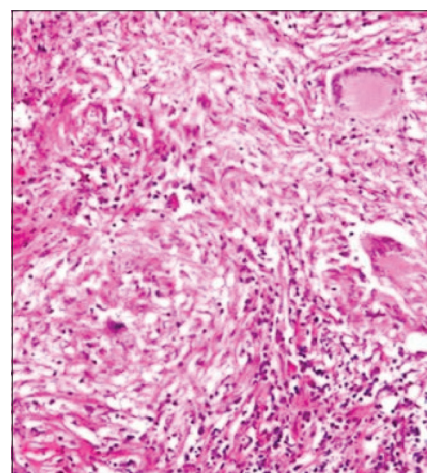


Figure 4: Tuberculous osteomyelitis confirmed after biopsy of the left humeral head, showing caseo-follicular tuberculosis aspect

DISCUSSION

Clavicular tuberculosis is a very rare form of osteoarticular tuberculosis, representing <5% of its localizations. Young adults are most often affected with a slight male predominance.^[1]

The involvement is often linked to a hematogenous dissemination of tubercle bacilli from a primitive visceral focus, most often with pulmonary origin.^[2]

Bone scan with radiobiphosphonates can be used to search other localizations falling within the framework of a polystotic form. However, it does not distinguish between an infectious and tumoral origin, and 35% of evolutionary lesions do not have an uptake of the radioactive tracer because of their avascular or purely osteolytic nature.^[3] However, bone scintigraphy can guide nonrisk biopsy in such group of patients with multifocal disease.^[2,3]

In front of nonspecific bone lesion in radiological exploration, the surgical approach may be necessary, especially because the differential diagnosis of benign (eosinophilic granuloma), primary malignancy (Ewing's sarcoma, osteosarcoma), secondary, myelomatous, or infectious origin, is still not established.

The diagnosis of tuberculous osteomyelitis is based especially on the bacteriological samples at the level of an abscess or fistulas, or on a histological examination following a percutaneous bone biopsy.^[1]

Antituberculous treatment according to the 2RHZ/4RH protocol must be considered in our context, with the objective of the possibility of surgical resection in the case of failed medical treatment.^[4,5]

CONCLUSION

Clavicular tuberculosis is considered a rare form of tuberculous osteomyelitis. Radiobiphosphonate bone scintigraphy is very sensitive for the diagnosis of multifocality, but the diagnosis in these rare forms with tuberculous origin is especially based on bacteriological samples or on a histological examination following a percutaneous bone biopsy.

Declaration of patient consent

The authors certify that they have obtained all appropriate patient consent forms. In the form, the patient has given his consent for his images and other clinical information to be reported in the journal. The patient understands that his name and initial will not be published, and due efforts will be made to conceal identity, but anonymity cannot be guaranteed.

Financial support and sponsorship

Nil.

Conflicts of interest

There are no conflicts of interest.

REFERENCES

1. Chang DS, Rafii M, McGuinness G, Jagirdar JS. Primary multifocal tuberculous osteomyelitis with involvement of the ribs. *Skeletal Radiol* 1998;27:641-5.
2. Pertuiset E. Tuberculose osseuse et articulaire des membres. *EMC Rhumatol Orthopéd* 2004;1:463-86.
3. Adil A, El Ouafi N, El Wady N, Lahlou K, Kadiri R. Les ostéites et les ostéoarthrites tuberculeuses périphériques. *Radiol JCEPUR* 2000;20:137-45.
4. Agrawal V, Joshi MK, Jain BK, Mohanty D, Gupta A. Tuberculous osteomyelitis of rib – A surgical entity. *Interact Cardiovasc Thorac Surg* 2008;7:1028-30.
5. Voohra R, Kang HS, Dogra S, Saagar RD, Sharma R. Tuberculous osteomyelitis. *J Bone Joint Surg* 1997;79B:562-6.