

Case Report

Serendipitous actinomycosis infection mimicking malignant lesion in carcinoma of unknown primary

ABSTRACT

Actinomycosis is a bacterial infection caused by *Actinomyces* species that are commensal in the human oral cavity, digestive tract, and genital tract. The present case highlights actinomycosis of the hypopharynx, mimicking malignancy in ^{18}F -fluorodeoxyglucose positron emission tomography-computed tomography.

Keywords: Actinomycosis of hypopharynx, carcinoma of unknown primary, false positive, head and neck malignancy, positron emission tomography-contrast enhanced computed tomography

INTRODUCTION

Actinomycosis is a bacterial infection caused by *Actinomyces* species, a type of filamentous, Gram-positive, nonacid-fast, anaerobic-to-microaerophilic bacteria, which are commensals in the human oral cavity, digestive tract, and genital tract.^[1] Cervicofacial actinomycosis is the most common type (about 60%) followed by thoracic actinomycosis (15%–20%).^[1] ^{18}F -fluorodeoxyglucose (FDG) is a tracer widely used for imaging malignancy; however, it also localizes in the sites of infection and inflammation. Here, we describe a rare occurrence of FDG-positive actinomycotic lesion mimicking malignancy in a known case of carcinoma of unknown primary.

CASE REPORT

A 50-year-old man presented with progressive bilateral neck swelling of 3 months. Biopsy from right level V node revealed metastatic squamous cell carcinoma. Whole-body FDG positron emission tomography-contrast enhanced computed tomography (PET-CECT) was done but could not detect a primary site of malignancy. The patient was treated with bilateral modified neck dissection, followed by adjuvant concurrent chemo-radiotherapy. Whole-body FDG PET-CECT was done 12 weeks after the completion

of radiotherapy for response evaluation. It showed hypermetabolic soft-tissue thickening involving the right pyriform fossa (PFS) with maximum standard uptake value of 9.01 [Arrows in Figure 1a-c]. This appeared suspicious for a malignant etiology. Direct laryngoscopic examination revealed mucosal bulge in the right PFS. Subsequent histopathology revealed ulcerated squamous mucosa with necrosis and gram-positive actinomycotic colonies with abundant sulfur granules, with no evidence of malignancy [Figure 1d-g]. The patient was put on anti-chondronecrosis treatment afterward.

DISCUSSION

Actinomycosis is a chronic granulomatous infection that can often present as a mass-like lesion and mimic malignancy.^[2]

SAYAK CHOUDHURY, ARCHI AGRAWAL, SWARNIL RANE¹, V. RANGARAJAN

Departments of Nuclear Medicine and Molecular Imaging and ¹Pathology, Tata Memorial Hospital, Mumbai, Maharashtra, India


Address for correspondence: Dr. Archi Agrawal, Department of Nuclear Medicine and Molecular Imaging, Tata Memorial Hospital, E. Borges Road, Parel, Mumbai - 400 012, Maharashtra, India.
E-mail: drarchi23@gmail.com

Submission: 02-12-2018 **Accepted:** 15-12-2018 **Published:** 18-12-2019

This is an open access journal, and articles are distributed under the terms of the Creative Commons Attribution-NonCommercial-ShareAlike 4.0 License, which allows others to remix, tweak, and build upon the work non-commercially, as long as appropriate credit is given and the new creations are licensed under the identical terms.

For reprints contact: reprints@medknow.com

How to cite this article: Choudhury S, Agrawal A, Rane S, Rangarajan V. Serendipitous actinomycosis infection mimicking malignant lesion in carcinoma of unknown primary. World J Nucl Med 2019;18:413-5.

| Access this article online | |
|---|---|
| Website: www.wjnm.org | Quick Response Code  |
| DOI: 10.4103/wjnm.WJNM_108_18 | |

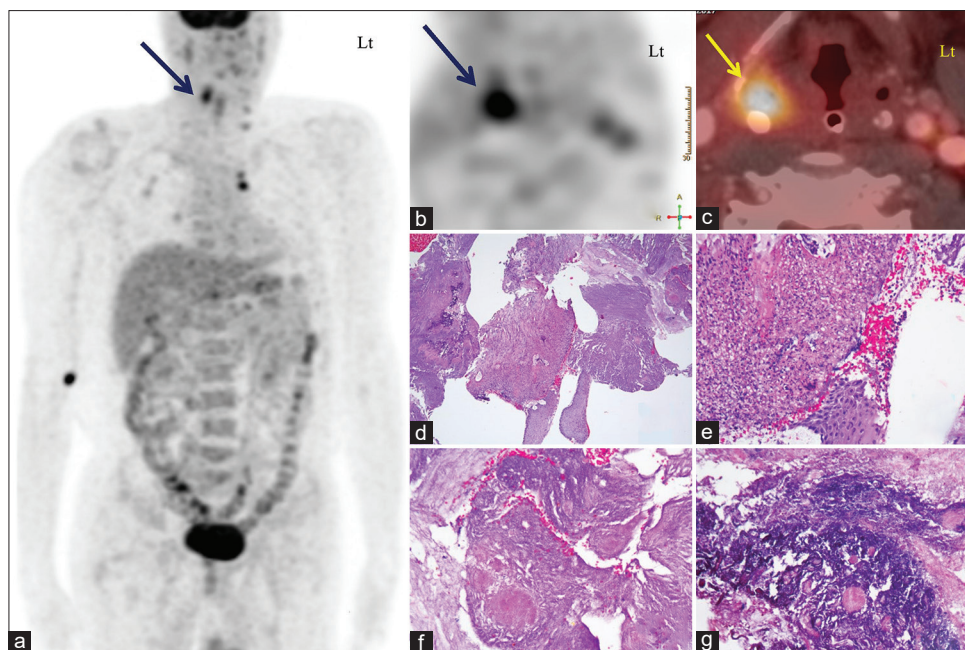


Figure 1: Panel of maximum intensity projection and transaxial positron emission tomography images show focally increased uptake in the right neck region (indicated with blue arrows in images a and b, respectively). Fused positron emission tomography-computed tomography image localizes the uptake in right pyriform fossa (yellow arrow in c). Photomicrographs of biopsy from lesion showing a necroinflammatory tissue (d), with an ulcerated squamous mucosa (e) and abundant bacterial colonies with sculpture granules (f) (H and E stain). In Gram stain, the bacteria are filamentous and are gram-positive (g)

With improving oral hygiene, the actinomycosis incidence is going down in developed countries, in developing countries; however, it still poses a problem.^[3] Most of the literature on actinomycosis simulating malignancy are case reports of pulmonary actinomycosis.^[4-6] Rarer still is literature describing FDG PET/CT findings of actinomycotic infection. We could find only two retrospective studies of small number of patients that tried to evaluate the role of FDG PET/CT in pulmonary actinomycosis. Their findings indicate that FDG PET/CT is of limited value in differentiating actinomycosis from malignancy.^[2,7] FDG concentrating actinomycosis of other organs can also easily be confused with malignant lesions as evidenced by the hand full of case reports published.^[8-10] Actinomycosis of head and neck region mimicking malignant tumor has also been described in some case reports;^[8-10] however, we could not find any case reports describing FDG PET CT findings of actinomycosis of the hypopharynx. Our case report is unique in that regard. In conclusion, such FDG-avid lesions pose quite a diagnostic challenge in a known or suspected case of malignancy and can easily confuse the clinician and should always be correlated with a proper histopathological and microbiological evaluation.

Declaration of patient consent

The authors certify that they have obtained all appropriate patient consent forms. In the form the patient(s) has/have given his/her/their consent for his/her/their images and other clinical information to be

reported in the journal. The patients understand that their names and initials will not be published and due efforts will be made to conceal their identity, but anonymity cannot be guaranteed.

Financial support and sponsorship

Nil.

Conflicts of interest

There are no conflicts of interest.

REFERENCES

1. Valour F, Sénéchal A, Dupieux C, Karsenty J, Lustig S, Breton P, *et al.* Actinomycosis: Etiology, clinical features, diagnosis, treatment, and management. *Infect Drug Resist* 2014;7:183-97.
2. Sun XF, Wang P, Liu HR, Shi JH. A retrospective study of pulmonary actinomycosis in a single institution in China. *Chin Med J (Engl)* 2015;128:1607-10.
3. Wong VK, Turmezei TD, Weston VC. Actinomycosis. *BMJ* 2011;343:d6099.
4. Qiu L, Lan L, Feng Y, Huang Z, Chen Y. Pulmonary actinomycosis imitating lung cancer on (18)F-FDG PET/CT: A case report and literature review. *Korean J Radiol* 2015;16:1262-5.
5. Nagao M, Fukuda A, Matsumura T, Kimura T, Seno H. Pulmonary actinomycosis mimicking a lung metastasis from esophageal cancer; a case report. *BMC Pulm Med* 2018;18:39.
6. Weisshaupt C, Hitz F, Albrich WC, Omlin A. Pulmonary actinomycosis and Hodgkin's disease: When FDG-PET may be misleading. *BMJ Case Rep* 2014;2014. pii: bcr2014206034.
7. Choi H, Lee H, Jeong SH, Um SW, Kwon OJ, Kim H, *et al.* Pulmonary

- actinomycosis mimicking lung cancer on positron emission tomography. *Ann Thorac Med* 2017;12:121-4.
8. Mok GS, Choi FP, Chu WC. Actinomycosis imitating parotid cancer with metastatic lymph nodes in FDG PET/CT. *Clin Nucl Med* 2011;36:309-10.
 9. Singla S, Singh H, Mukherjee A, Karunanithi S, Bal C, Kumar R, *et al.* Cervical and thoracic actinomycosis on (18) F-FDG PET/CT. *Clin Nucl Med* 2014;39:623-4.
 10. Yoshihama K, Kato Y, Baba Y. Vocal cord actinomycosis mimicking a laryngeal tumor. *Case Rep Otolaryngol* 2013;2013:361986.