

Clinical outcome study of crizotinib in immunohistochemistry-proven echinoderm microtubule-associated protein-like 4-anaplastic lymphoma kinase fusion gene among Indian patients with adenocarcinoma lung

Ullas Batra, Mohit Aggarwal, Parveen Jain, Pankaj Goyal, Abhishek Yadav, Udip Maheshwari, Anurag Mehta

Abstract

Aims: The anaplastic lymphoma kinase (ALK) Break Apart FISH Probe Kit and Ventana anti-ALK (D5F3) CDx immunohistochemistry (IHC) assay are the Food and Drug Administration-approved companion diagnostic for targeted therapy with the ALK inhibitor crizotinib in lung cancers. The aim of this study was to assess the efficacy and safety of twice daily crizotinib tablet (250 mg) in IHC-proven echinoderm microtubule-associated protein-like 4 (EML4)-ALK fusion gene among Indian patients with adenocarcinoma lung in the routine clinical practice. **Subjects and Methods:** Patients with nonsmall cell lung cancer (NSCLC), adenocarcinoma histology, whose tumors were found to be positive for EML4-ALK fusion gene using IHC, were considered for this study. IHC analysis was performed using a Ventana automated immunostainer (Benchmark XT). Detection was performed using Optiview DAB detection and amplification kit. **Results:** A total of 25 NSCLC adenocarcinoma patients were included in the study. There were 14 (56%) women and 10 (44%) men with a median age of 53 years. All patients had Stage IV disease at the time of initiation of crizotinib therapy. One patient achieved complete response and 20 achieved response rate (PR) for an overall PR of 84%. The median progression-free survival (PFS) was 11.8 months and median overall survival (OS) was 20.6 months. Two (8%) patients experienced severe hepatotoxicity requiring permanent discontinuation of crizotinib therapy. **Conclusions:** A very high PR, PFS, and OS achieved in our study population indicates that IHC can accurately identify EML4-ALK fusion gene mutations in lung adenocarcinoma patients who are responsive to ALK inhibitors such as crizotinib. IHC should be considered as a cost-effective alternative to FISH, especially in low-resource countries.

Key words: Echinoderm microtubule-associated protein-like 4-anaplastic lymphoma kinase, epidermal growth factor receptor, nonsmall cell lung cancer, small cell lung cancer

Introduction

The introduction of targeted therapies has unveiled a new era of personalized treatment in nonsmall cell lung cancer (NSCLC). Although the newer therapies have improved the survival in NSCLC patients, it still remains a leading cause of cancer-related deaths worldwide.^[1] The overall 5-year survival rate of 15% in NSCLC hints toward the need of a more accurate diagnosis of the disease at the molecular level so that it can be managed with appropriate strategies. It has been shown in various studies that majority of NSCLC patients harbor one or more activated pathways with mutations in various genes such as Kirsten RAS gene or epidermal growth factor receptor (EGFR) gene or the fusion gene between echinoderm microtubule-associated protein-like 4 (EML4) and the intracellular domain of anaplastic lymphoma kinase (ALK), named as EML4-ALK.^[2-7]

Various studies have reported the incidence of EGFR mutations in NSCLC in the range of 10% to 51.8% across different ethnicity.^[8-15] Similarly, the incidence of ALK gene rearrangements in NSCLC has been reported in the range of 3%–13%.^[4,5,16,17] While patients with activating mutations of EGFR gene show a better response to EGFR tyrosine kinase inhibitors (TKIs),^[2,3] the tumors harboring ALK rearrangements respond better to crizotinib which is an oral ATP-competitive TKIs of ALK and c-MET.^[18] In a Phase 3 trial comparing crizotinib with chemotherapy in ALK-positive lung cancer patients, crizotinib has demonstrated an impressive response rate (PR) of 65% and progression-free survival (PFS) of 7.7 months as compared to 20% and 3 months in the chemotherapy group ($P < 0.001$).^[19] Crizotinib therapy has also demonstrated a very high 1- and 2-year overall survival (OS)

of 77% and 64%, respectively, in patients with advanced NSCLC.^[20]

The ALK Break Apart FISH Probe Kit became the first Food and Drug Administration (FDA)-approved companion diagnostic for targeted therapy with crizotinib in lung cancers. However, due to practical limitations of FISH technique, recent studies have investigated the immunohistochemistry (IHC) for ALK protein expression using an antibody D5F3 and signal amplification kit OptiView by Ventana Roche for high sensitivity and specificity as compared to FISH.^[21-23] The US FDA has approved Ventana anti-ALK (D5F3) CDx assay in June 2015 for the selection of ALK-rearranged lung adenocarcinoma patients eligible to receive crizotinib therapy. However, Indian data on efficacy of crizotinib in IHC-positive NSCLC patients are lacking. The present study was carried out to assess the efficacy and safety of twice daily crizotinib tablet (250 mg) in IHC-proven EML4-ALK fusion gene among Indian patients with adenocarcinoma lung in the routine clinical practice.

Subjects and Methods

Patients with NSCLC, adenocarcinoma histology, whose tumors were found to be positive for EML4-ALK fusion gene using IHC, were considered for this study. Permission was obtained from the Ethics Committee before the start of the study. Clinical characteristics and treatment details were collected from the patient's medical records. ALK gene rearrangement was detected by IHC using a Ventana automated immunostainer (Ventana Medical Systems, Illkirch Graffenstaden, France). IHC was assayed on 4 μ m neutral

This is an open access article distributed under the terms of the Creative Commons Attribution-NonCommercial-ShareAlike 3.0 License, which allows others to remix, tweak, and build upon the work non-commercially, as long as the author is credited and the new creations are licensed under the identical terms.

For reprints contact: reprints@medknow.com

How to cite this article: Batra U, Aggarwal M, Jain P, Goyal P, Yadav A, Maheshwari U, *et al.* Clinical outcome study of crizotinib in immunohistochemistry-proven echinoderm microtubule-associated protein-like 4-anaplastic lymphoma kinase fusion gene among Indian patients with adenocarcinoma lung. Letter to the Editor. South Asian J Cancer 2018;7:61-4.

Access this article online

Quick Response Code:



Website: www.sajc.org

DOI: 10.4103/sajc.sajc_215_17

Rajiv Gandhi Cancer Institute and Research Center,
New Delhi, India

Correspondence to: Dr. Ullas Batra,

E-mail: ullasbatra@gmail.com

buffered formalin fixed; paraffin-embedded tumor tissues using a primary rabbit monoclonal ALK antibody (mAb) clone D5F3 obtained from Ventana USA. IHC staining was performed using a Ventana benchmark XT immunostainer. The slides were dried at 60°C for 1 h, deparaffinized using EZ Prep at 75°C for 4 min, and incubated with the primary mAb at a dilution of 1:50 for 1 h at 37°C. Detection was performed using a multimer technology system with the UltraView Universal DAB detection kit.

The primary endpoint of this study was PR. The width of the resultant confidence intervals (CIs) for parameters to be estimated was constructed with a significance level of 0.05, i.e., a 95% CI. OS and PFS were analyzed with the use of Kaplan–Meier survival analysis and estimates were provided with 95% CIs. Statistical analysis was performed using SAS 8.02 (SAS Institute Inc.).

Results

A total of 25 NSCLC adenocarcinoma patients were included in the study. There were 14 (56%) women and 10 (44%) men with a median age of 53 years. Eleven (44%) patients were nonsmokers and Eastern Cooperative Oncology Group performance status of 1 and 2 was present in 18 (72%) and 7 (28%) patient, respectively. Baseline patient characteristics are presented in Table 1. All the patients were positive for EML4-ALK fusion gene and none of the patient was positive for EGFR mutations. All patients had Stage IV disease at the time of initiation of crizotinib therapy. One patient achieved complete response and twenty achieved PR for an overall PR of 84%. The median PFS was 11.8 months [95% CI: 5.3–17.3 months; Figure 1]. The median OS was 20.6 months [95% CI: 12.8–34.1 months; Figure 2]. Common toxicity criteria (CTC) Grade 1 and 2 adverse events were vomiting, anemia, cough, thrombocytopenia, hyponatremia, anorexia, and diarrhea that did not require any dose modification. Two (8%) patients experienced severe hepatotoxicity requiring discontinuation of crizotinib therapy [Table 2].

Discussion

The discovery of ALK was made more than 17 years ago as a fusion oncogene with nucleophosmin in a subset of anaplastic large cell lymphomas. The activity of ALK tyrosine kinase is significant for its oncogenicity. In NSCLC, ALK gene rearrangements were primarily reported in the year 2007.^[24] Studies on Caucasian and East Asian NSCLC population have reported the incidence of ALK gene rearrangements in the range of 3% to 13% using the FISH technique.^[4,5,16,17] Studies on Indian ethnicity have reported the incidence of ALK gene rearrangement in NSCLC in the range of 2.7%–3% using the FISH technique.^[25,26] Till date, there is only one published report from India on the incidence of ALK gene rearrangement in NSCLC using the IHC assay.^[27] The 13.5% incidence in this Indian study is several folds higher than the previous studies and indicates that a new ALK clone, 5A4, and D5F3 from Leica and cell signaling technology can accurately identify ALK gene rearrangement in NSCLC as compared to FISH.

The use of oral ATP, competitive TKI of ALK and c-MET, has shown a good PR of 65% in advanced NSCLC.^[19] Ever since its approval in the year 2011, crizotinib has become a personalized treatment option in NSCLC tumors harboring

Table 1: Summary of patient demographic and tumor characteristics (n=25)

Characteristics	N=25
Median age (years; range)	53 (30-80)
Gender	
Male	11 (44)
Female	14 (56)
Performance status	
1	18 (72)
2	7 (28)
Smoking	
Smokers	6 (24)
Never smokers	11 (44)
Unknown	8 (32)
Stage	
IV	25 (100)

Table 2: Common toxicity criteria all grade toxicities

Toxicity	Grade 1, n (%)	Grade 2, n (%)	Grade 3, n (%)	Grade 4, n (%)
Vomiting	-	7 (28)	-	-
Anemia	4 (20)	2 (8)	-	-
Cough	5 (20)	-	-	-
Thrombocytopenia	2 (8)	-	-	-
Hyponatremia	2 (8)	-	-	-
Anorexia	2 (8)	-	-	-
Diarrhea	2 (8)	-	-	-
Hepatotoxicity	-	-	-	2 (8)

ALK rearrangements. A systematic review of nine studies including 729 patients revealed a 1-year OS of 77.1% and PFS of 9.17 months along with an improved objective PR with crizotinib therapy as compared to chemotherapy group.^[28]

The ALK Break Apart FISH Probe Kit (Abbott Molecular, Des Plaines, IL, USA) was the first FDA-approved companion diagnostic for targeted therapy with crizotinib in lung cancers. The reagent of this test comprised of a Spectrum Orange (red) labeled 250 kb probe to the 3' end of ALK along with Spectrum Green (green) labeled 300 kb probe to the 5' end of ALK. The signals for each probe are evaluated under a fluorescent microscope using an oil immersion objective. Two patterns of ALK rearrangement are observed, first the break-apart where the red and green signals gets splitted and the second where the green signal is lost and only isolated or single red signals (3' ALK) are observed.^[25]

Although the FISH technique is widely practiced, it has a limitation of a very high inter-reader variability along with false negatives and false positives.^[29] Furthermore, lack of technical expertise, requirement of specialized fluorescence microscopy equipment, and higher operational costs are other limitations of FISH technique in low-resource countries.

Due to practical limitations of FISH technique, IHC for ALK protein expression in NSCLC has been explored as a faster, economical, and less operator-dependent alternative. Data from recent studies have established that staining of sections on Ventana immunostainer (benchmark XT) using an antibody D5F3 and labeling as well as signal amplification kit OptiView by Ventana Roche have a high sensitivity and specificity as compared to FISH.^[21-23] The Ventana anti-ALK (D5F3) CDx assay has received the US FDA approval in June 2015 for the selection of ALK-rearranged

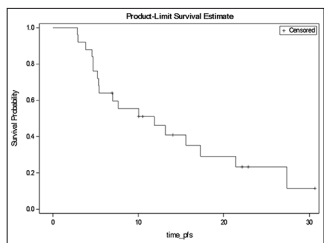


Figure 1: Kaplan–Meier survival analysis for progression-free survival

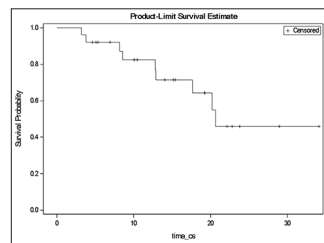


Figure 2: Kaplan–Meier survival analysis for overall survival

lung adenocarcinoma patients. In a study by Ma *et al.*, six ALK-positive lung adenocarcinoma patients who tested Ventana IHC positive and FISH negative showed a very high objective PR of 66.7% with crizotinib therapy.^[30] Similarly, in other studies comparing IHC using D5F3 antibody with FISH, the sensitivity and specificity of IHC has always exceeded 90%.^[21,31,32] Several studies have also advocated the screening of NSCLC patients for EML4-ALK gene fusions by IHC technique and applying FISH only in cases found positive by IHC.^[33-35] In addition to FISH and IHC, next-generation sequencing (NGS) is another diagnostic assay that has been explored for the detection of EML4-ALK gene fusions in lung adenocarcinoma patients.^[36] In a retrospective study of 51 consecutive patients with lung adenocarcinoma, four of the five cases that were IHC positive/FISH negative were found to be positive by the NGS assay, whereas a single case that was IHC negative/FISH positive was found to be negative for ALK rearrangement by NGS.^[23]

The overall PR of 84% in our study is higher to the previously published reports. Similarly, the median PFS of 11.8 months (95% CI: 5.3–17.3 months) and median OS of 20.6 months (95% CI: 12.8–34.1 months) in our study is also higher to the previously published reports. The higher PR, PFS, and OS achieved in our study demonstrate the high sensitivity and specificity of IHC as compared to FISH technique. Further, it establishes the clinical utility of IHC as a cost-effective alternative to FISH for the selection of ALK-rearranged lung adenocarcinoma patients that will benefit from crizotinib therapy. Crizotinib therapy was very well tolerated by our study population, and none of the patients required dose modifications. Two (8%) patients who experienced CTC Grade 4 hepatotoxicity were discontinued from the crizotinib therapy as per the clinical judgment of the treating physician.

Conclusions

Our study reports the first Indian data on the clinical outcome of Crizotinib in IHC-proven EML4-ALK-rearranged lung adenocarcinoma patients. The encouraging PR, PFS, and OS achieved in our study population indicate that IHC can accurately identify EML4 ALK fusion gene mutations in lung adenocarcinoma patients who are responsive to ALK inhibitors such as Crizotinib. IHC should be considered as a cost-effective alternative to FISH for the detection of EML4-ALK gene fusions, especially in low-resource countries.

Financial support and sponsorship

Nil.

Conflicts of interest

There are no conflicts of interest.

References

- Jemal A, Siegel R, Ward E, Hao Y, Xu J, Murray T, *et al.* Cancer statistics, 2008. *CA Cancer J Clin* 2008;58:71-96.
- Okamoto I, Mitsudomi T, Nakagawa K, Fukuoka M. The emerging role of epidermal growth factor receptor (EGFR) inhibitors in first-line treatment for patients with advanced non-small cell lung cancer positive for EGFR mutations. *Ther Adv Med Oncol* 2010;2:301-7.
- Tsao AS, Papadimitrakopoulou VA. The future of NSCLC: Molecular profiles guiding treatment decisions. *Oncology (Williston Park)* 2011;25:607, 614.
- Soda M, Choi YL, Enomoto M, Takada S, Yamashita Y, Ishikawa S, *et al.* Identification of the transforming EML4-ALK fusion gene in non-small-cell lung cancer. *Nature* 2007;448:561-6.
- Zhang X, Zhang S, Yang X, Yang J, Zhou Q, Yin L, *et al.* Fusion of EML4 and ALK is associated with development of lung adenocarcinomas lacking EGFR and KRAS mutations and is correlated with ALK expression. *Mol Cancer* 2010;9:188.
- Sequist LV, Heist RS, Shaw AT, Fidias P, Rosovsky R, Temel JS, *et al.* Implementing multiplexed genotyping of non-small-cell lung cancers into routine clinical practice. *Ann Oncol* 2011;22:2616-24.
- Kris MG, Johnson BE, Kwiatkowski DJ. Identification of driver mutations in tumor specimens from 1,000 patients with lung adenocarcinoma: the NCI's Lung Cancer Mutation Consortium (LCMC). *J Clin Oncol* 2011;29:Abstr CRA7506.
- Sahoo R, Harini VV, Babu VC, Patil Okaly GV, Rao S, Nargund A, *et al.* Screening for EGFR mutations in lung cancer, a report from India. *Lung Cancer* 2011;73:316-9.
- Chougule A, Prabhakar K, Noronha V, Joshi A, Thavamani A, Chandrani P, *et al.* Frequency of EGFR mutations in 907 lung adenocarcinoma patients of Indian ethnicity. *PLoS One* 2013;8:e76164.
- Doval DC, Azam S, Batra U, Choudhury KD, Talwar V, Gupta SK, *et al.* Epidermal growth factor receptor mutation in lung adenocarcinoma in India: A single center study. *J Carcinog* 2013;12:12.
- Lynch TJ, Bell DW, Sordella R, Gurubhagavatula S, Okimoto RA, Brannigan BW, *et al.* Activating mutations in the epidermal growth factor receptor underlying responsiveness of non-small-cell lung cancer to gefitinib. *N Engl J Med* 2004;350:2129-39.
- Cortes-Funes H, Gomez C, Rosell R, Valero P, Garcia-Giron C, Velasco A, *et al.* Epidermal growth factor receptor activating mutations in Spanish gefitinib-treated non-small-cell lung cancer patients. *Ann Oncol* 2005;16:1081-6.
- Wu SG, Gow CH, Yu CJ, Chang YL, Yang CH, Hsu YC, *et al.* Frequent epidermal growth factor receptor gene mutations in malignant pleural effusion of lung adenocarcinoma. *Eur Respir J* 2008;32:924-30.
- Usui K, Ushijima T, Tanaka Y, Tanai C, Noda H, Abe N, *et al.* The frequency of epidermal growth factor receptor mutation of nonsmall cell lung cancer according to the underlying pulmonary diseases. *Pulm Med* 2011;2011:290132.
- Huang YS, Yang JJ, Zhang XC, Yang XN, Huang YJ, Xu CR, *et al.* Impact of smoking status and pathologic type on epidermal growth factor receptor mutations in lung cancer. *Chin Med J (Engl)* 2011;124:2457-60.
- Kim DW, Ahn MJ, Shi Y, Yang PC, Liu X, De Pas TM, *et al.* Updated results of a global phase II study with Crizotinib in advanced ALK-positive Non-Small Cell Lung Cancer (NSCLC). *Ann Oncol* 2012; 23:Abstr 1230 PD.
- Wong DW, Leung EL, So KK, Tam IY, Sihoe AD, Cheng LC, *et al.* The EML4-ALK fusion gene is involved in various histologic types of lung cancers from nonsmokers with wild-type EGFR and KRAS. *Cancer* 2009;115:1723-33.
- Kwak EL, Bang YJ, Camidge DR, Shaw AT, Solomon B, Maki RG, *et al.* Anaplastic lymphoma kinase inhibition in non-small-cell lung cancer. *N Engl J Med* 2010;363:1693-703.
- Shaw AT, Kim DW, Nakagawa K, Seto T, Crinó L, Ahn MJ, *et al.* Crizotinib versus chemotherapy in advanced ALK-positive lung cancer. *N Engl J Med* 2013;368:2385-94.
- Shaw AT, Yeap BY, Solomon BJ, Riely GJ, Iafrate AJ, Shapiro G, *et al.* Impact of crizotinib on survival in patients with advanced, ALK positive NSCLC compared with historical controls. *J Clin Oncol* 29: 2011 (Suppl; abstr7507).
- Marchetti A, Di Lorito A, Pace MV, Iezzi M, Felicioni L, D'Antuono T, *et al.* ALK protein analysis by IHC staining after recent regulatory changes: A Comparison of two widely used approaches, revision of the literature, and a new testing algorithm. *J Thorac Oncol* 2016;11:487-95.
- von Laffert M, Warth A, Penzel R, Schirmacher P, Kerr KM, Elmberger G, *et al.* Multicenter immunohistochemical ALK-testing of non-small-cell lung cancer shows high concordance after harmonization of techniques and interpretation criteria. *J Thorac Oncol* 2014;9:1685-92.

23. Pekar-Zlotin M, Hirsch FR, Soussan-Gutman L, Ilouze M, Dvir A, Boyle T, *et al.* Fluorescence *in situ* hybridization, immunohistochemistry, and next-generation sequencing for detection of EML4-ALK rearrangement in lung cancer. *Oncologist* 2015;20:316-22.
24. Shaw AT, Engelman JA. ALK in lung cancer: Past, present, and future. *J Clin Oncol* 2013;31:1105-11.
25. Desai SS, Shah AS, Prabhash K, Jambhekar NA. A year of anaplastic large cell kinase testing for lung carcinoma: Pathological and technical perspectives. *Indian J Cancer* 2013;50:80-6.
26. Doval D, Prabhash K, Patil S, Chaturvedi H, Goswami C, Vaid A, *et al.* Clinical and epidemiological study of EGFR mutations and EML4-ALK fusion genes among indian patients with adenocarcinoma of the lung. *Onco Targets Ther* 2015;8:117-23.
27. Mehta A, Batra U. Molecular epidemiological study of microtubule-associated protein-like 4-anaplastic lymphoma kinase fusion gene using immunohistochemistry as a cost effective alternative to fluorescence *in situ* hybridization for Indian patients with adenocarcinoma lung. *Asian J Oncol* 2017;3:45-9.
28. Wang M, Wang G, Ma H, Shan B. Crizotinib versus chemotherapy on ALK-positive NSCLC: A systematic review of efficacy and safety. *Curr Cancer Drug Targets*. 2017 Jun 23. [Epub ahead of print] PubMed PMID: 28669346.
29. Wallander ML, Geiersbach KB, Tripp SR, Layfield LJ. Comparison of reverse transcription-polymerase chain reaction, immunohistochemistry, and fluorescence *in situ* hybridization methodologies for detection of echinoderm microtubule-associated proteinlike 4-anaplastic lymphoma kinase fusion-positive non-small cell lung carcinoma: Implications for optimal clinical testing. *Arch Pathol Lab Med* 2012;136:796-803.
30. Ma D, Wang Z, Yang L, Mu X, Wang Y, Zhao X, *et al.* Responses to crizotinib in patients with ALK-positive lung adenocarcinoma who tested immunohistochemistry (IHC)-positive and fluorescence *in situ* hybridization (FISH)-negative. *Oncotarget* 2016;7:64410-20.
31. Ying J, Guo L, Qiu T, Shan L, Ling Y, Liu X, *et al.* Diagnostic value of a novel fully automated immunochemistry assay for detection of ALK rearrangement in primary lung adenocarcinoma. *Ann Oncol* 2013;24:2589-93.
32. Lantuejoul S, Rouquette I, Blons H, Le Stang N, Ilie M, Begueret H, *et al.* French multicentric validation of ALK rearrangement diagnostic in 547 lung adenocarcinomas. *Eur Respir J* 2015;46:207-18.
33. McLeer-Florin A, Moro-Sibilot D, Melis A, Salameire D, Lefebvre C, Ceccaldi F, *et al.* Dual IHC and FISH testing for ALK gene rearrangement in lung adenocarcinomas in a routine practice: A French study. *J Thorac Oncol* 2012;7:348-54.
34. Paik JH, Choe G, Kim H, Choe JY, Lee HJ, Lee CT, *et al.* Screening of anaplastic lymphoma kinase rearrangement by immunohistochemistry in non-small cell lung cancer: Correlation with fluorescence *in situ* hybridization. *J Thorac Oncol* 2011;6:466-72.
35. Thunnissen E, Bubendorf L, Dietel M, Elmberger G, Kerr K, Lopez-Rios F, *et al.* EML4-ALK testing in non-small cell carcinomas of the lung: A review with recommendations. *Virchows Arch* 2012;461:245-57.
36. Ali SM, Hensing T, Schrock AB, Allen J, Sanford E, Gowen K, *et al.* Comprehensive genomic profiling identifies a subset of crizotinib-responsive ALK-rearranged non-small cell lung cancer not detected by fluorescence *in situ* hybridization. *Oncologist* 2016;21:762-70.