

Review Article

Antroduodenal Stenting for Malignant Gastric Outlet Obstruction: Technique and Outcome

Uday C. Ghoshal, Vinay Kumar

Department of
Gastroenterology, Sanjay
Gandhi Post Graduate
Institute of Medical Sciences,
Lucknow, Uttar Pradesh,
India

ABSTRACT Gastric outlet obstruction (GOO) is usually a late presentation of gastric cancer, pancreaticobiliary malignancy, and extrinsic lymph nodal compression. Presenting symptoms are abdominal pain, postprandial epigastric fullness, and recurrent vomiting, which lead to severe malnutrition and dehydration and poor quality of life (QoL). Endoscopic enteral stent placement has become the acceptable alternative modality for palliation of malignant GOO because it is safe, minimally invasive, and a cost-effective procedure. In addition, endoscopic stent placement leads to shorter time to resume oral diet and shorter hospital stay in comparison to surgical bypass. Endoscopic stent placement is associated with high technical as well as clinical success rates and improvement in QoL, but no survival improvement. Recurrence of symptoms occurs due to stent occlusion, or stent migration, which can be successfully managed with repeat endoscopic stent placement. Perforation and bleeding are serious but rare complications.

KEYWORDS: Enteral nutrition, enteral stent, gallbladder cancer, gastric cancer, gastric outlet obstruction, vomiting

INTRODUCTION

Gastric outlet obstruction (GOO) is usually a late presentation of gastric cancer, pancreaticobiliary malignancy, and extrinsic lymph nodal compression.^[1,2] Presenting symptoms are abdominal pain, postprandial epigastric fullness, and recurrent vomiting, which lead to severe malnutrition, dehydration and poor quality of life (QoL).^[1,3] All these factors result in diminished life expectancy. Once GOO is developed, mean life expectancy ranges from 7 to 20 weeks.^[4,5] Treatment of malignant GOO is mainly palliative. Surgical bypass is considered as a traditional measure of palliation of gastric outlet obstruction in these groups of patients.^[6,7] However, in these patients, surgical risk is high with perioperative complication rate of 25%–35% and mortality of up to 2%.^[7,8] Endoscopic enteral stent placement is an acceptable alternative of surgical management. Endoscopic treatment is shown to be associated with lower morbidity and mortality, shorter hospitalization, and earlier symptoms relief.^[9]

This article reviews the etiology of gastric outlet obstruction, outcomes, predictors of treatment failure, and QoL after endoscopic enteral stent placement.

ETIOLOGY AND SITE OF MALIGNANT GASTRIC OUTLET OBSTRUCTION

GOO is usually a late complication of various pancreaticobiliary and gastroduodenal malignancies. Etiological spectrum of malignant GOO is variable depending on demography. One large multicenter study included 176 patients with malignant GOO. Pancreatic cancer (48%) was the most common cause of GOO, followed by metastases, gastric cancer, cholangiocarcinoma, papillary cancer, and gallbladder cancer. Duodenum was the most common site of obstruction.^[10] Other studies also showed pancreatic cancer as the most common cause while gastric cancer was the most common etiology in some other studies.^[11–15] Indian studies showed that cancers of the gallbladder, pancreas, and stomach were among the most common causes of

Address for correspondence: Prof. Uday C. Ghoshal,
Department of Gastroenterology, Sanjay Gandhi Postgraduate
Institute of Medical Science, Lucknow - 226 014,
Uttar Pradesh, India.
E-mail: udayghoshal@gmail.com

This is an open access journal, and articles are distributed under the terms of the Creative Commons Attribution-NonCommercial-ShareAlike 4.0 License, which allows others to remix, tweak, and build upon the work non-commercially, as long as appropriate credit is given and the new creations are licensed under the identical terms.

For reprints contact: reprints@medknow.com

How to cite this article: Ghoshal UC, Kumar V. Antroduodenal stenting for malignant gastric outlet obstruction: Technique and outcome. J Dig Endosc 2019;10:XX-XX.

Access this article online

Quick Response Code:



Website: www.jdeonline.in

DOI: 10.4103/jde.JDE_64_18

malignant GOO.^[16-18] Bowel metastases from colon and pelvic malignancies and lymphadenopathy at porta hepatis are less common causes of malignant GOO.^[19]

DIAGNOSIS OF GASTRIC OUTLET OBSTRUCTION

Diagnosis of GOO is based on history, physical examination, imaging, and endoscopy. Symptoms of GOO usually overlap with symptoms of underlying malignancy or adverse effects of different treatments such as chemotherapy and radiotherapy. This may cause a delay in diagnosis of GOO in these settings. Symptoms of GOO include nausea, vomiting, abdominal fullness, reflux, dehydration, anemia, and hypoalbuminemia. Blood gas analysis may show hypochloremic alkalosis. Succussion splash may be heard more than 3 h after meal in about half of the patients.^[20] Barium-contrast studies are helpful not only for confirmation of GOO but also for its localization and to assess the length of stricture. Another cross-sectional imaging such as computerized tomography is extremely helpful for the diagnosis of underlying malignancy itself and site and length of gastroduodenal obstruction. Upper GI endoscopy is the gold standard with additional advantage of direct visualization and tissue sampling.

METHODS OF PALLIATION GASTRIC OUTLET OBSTRUCTION

Conventionally, malignant GOO is treated with open gastrojejunostomy (OGJ). Although this procedure provides effective palliation of GOO symptoms, it results in considerable morbidity and mortality because of fragility of this group of patients.^[21,22] A systematic review of 12 studies demonstrated that endoscopic stent placement is preferable to OGJ in terms of shorter hospital stay and shorter time to oral intake. There was no significant difference in the rate of major complications and length of survival in the two groups.^[23] Laparoscopic gastrojejunostomy (LGJ) is now preferred alternative of surgical management of malignant GOO. Three retrospective studies compared the results of LGJ and endoscopic stent placement.^[6,24,25] Overall results showed shorter hospital stay, lesser postoperative pain and complications but reduced survival (56 vs. 119 days) following endoscopic stent placement. Endoscopic ultrasound-guided gastroenterostomy (EUS-GE) is a novel approach for palliation of malignant GOO. The first EUS-GE was described by Khashab *et al.*^[26] A multicenter retrospective study showed that EUS-GE had comparable effectiveness and safety to endoscopic stent placement while being associated with fewer symptom recurrence and requirements for re-intervention.^[27]

Nasoenteric tube feeding is often a useful mode of palliation in patients with malignant GOO with limited life expectancy. Sometimes, percutaneous gastrostomy is required for gastric decompression (venting gastrostomy) in association with nasoenteric tube feeding. If expected survival is more than a month, effort should be made to place antral stent as lack of comfort is the main issue with prolonged nasoenteric tube feeding.

Total parenteral nutrition (TPN) is an alternative option to nasoenteric tube feeding. TPN is also recommended before surgery to improve the nutritional status of patients.

ANTRODUODENAL STENTS FOR PALLIATION OF MALIGNANT GASTRIC OUTLET OBSTRUCTION History

The first antroduodenal stent was placed by Song *et al.* in 1993.^[28] They placed a Z stent through gastrostomy route. In 1995, the first peroral antroduodenal stent was placed by Strecker *et al.*^[29] Since then, several advancements have been made in the type of stents used and techniques of stent placement.

Indication and contraindication of self-expanding metal stent placement

Palliation for malignant GOO is not only limited to improve symptoms but also to improve QoL and allow starting or resuming oral medication. Antroduodenal stents are preferred mode of palliation in groups of patients who have confirmed malignant obstruction with high surgical risk, limited life expectancy, and significant comorbidity.

The contraindications of stent placement are life expectancy <2 weeks, delayed gastric emptying, and concomitant distal gastrointestinal obstruction.^[30]

TECHNICAL ASPECT

Types of antroduodenal self-expanding metal stents

Table 1 shows different types and the characteristics of antroduodenal stents available in market. Antroduodenal stents are made up of different metal alloy, i.e., Elgiloy (stainless steel) and Nitinol (nickel–titanium) alloy and are available in different length, diameter, and expansile forces. In general, antroduodenal stents are either covered or uncovered types. Each type of stents has its own advantages and disadvantages. The main cause of dysfunction of uncovered stent is tumor ingrowth or overgrowth with a frequency of 10%–30%.^[31,32] Although covered stent can overcome the problem of tumor ingrowth or overgrowth, disadvantage including stent migration with frequency of 16%–25% is common.^[33,34] A few randomized trials have shown comparable stent patency while using covered

Table 1: Characteristics of the different types of self-expandable antroduodenal stents

Type	Manufacturer	Material covered (C)/UC	Stent diameter body/ flared end (mm)	Stent length (cm)	Delivery system diameter/length (cm)
Wallstent	Boston Scientific Inc., Natick, MA, USA	Elgiloy (UC)	20/22	6, 9	10 Fr/135, 230
Wallflex	Boston Scientific Inc., Natick, MA, USA	Nitinol (UC)	22/27	6, 9, 12	10 Fr/230
Evolution	Cook Medical Inc., Winston-Salem, NC, USA	Nitinol (UC)	22/27	6, 9, 12	10 Fr/230
Hanarostent	M.I. Tech, Seoul, South Korea	Nitinol (C/UC)	18/22	6, 8, 11, 14, 17	10.2 Fr/120, 180, 210, 230
Niti-S	Taewoong Medical Inc., Seoul, South Korea	Nitinol (C/UC)	18, 20, 22, 24	6, 8, 10, 12, 14, 15	10 Fr/180
Hontostent	Mitra Industries Pvt. Ltd., Haryana, India	UC	18	8,11,14	10.2 fr/230

UC=Uncovered, C=Covered

or uncovered self-expanding metal stent (SEMS) for palliation of malignant GOO.^[33,35,36] Various modifications have been made to reduce the frequency of stent migration. Example of such type stent is WAVE stent. WAVE stent has been designed to reduce radial force and indentation in the central part of the uncovered flared portions of SEMS at both ends and a lasso at the proximal end that helps in adjustment of the stent position after deployment. A multicenter randomized study compared the safety and efficacy of newly developed WAVE-covered stent (with antimigration properties) with uncovered antroduodenal stent in malignant GOO due to gastric cancer. Results of this study showed comparable migration rate (9.5% vs. 5.4%) and significantly higher long-term stent patency rate (68.6% vs. 41.2%) in WAVE-covered stent group compared with uncovered stent.^[37]

Technique of stent placement

Before undertaking the procedure, gastric lavage is required through nasogastric tube for proper visualization and to prevent aspiration. Stent placement is performed by standard technique (www.spreadhealth.in, video; <https://youtu.be/ZkI0wn7ZxQ8>) using either a forward-viewing therapeutic scope or a side-viewing duodenoscope with a working channel diameter of ≥ 3.7 mm [Figure 1]. One study showed a comparable technical and clinical success rate when SEMS was placed through forward-viewing therapeutic endoscope or side-viewing duodenoscope for palliation of malignant distal duodenal obstruction.^[11] Patients are sedated with midazolam (5–10 mg) and/or propofol during SEMS placement. The endoscope is inserted carefully and the GOO is evaluated endoscopically. Water-soluble contrast medium is injected under fluoroscopic guidance to assess the site and length of the obstruction. The obstruction should be negotiated using a standard biliary guidewire and an endoscopic retrograde cholangiopancreatography catheter. The stent delivery system should be inserted

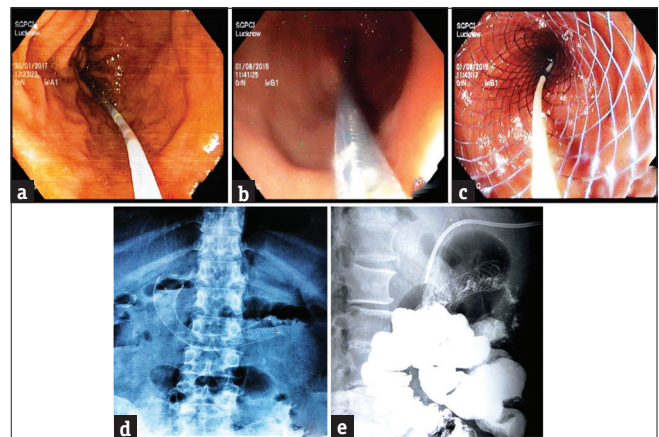


Figure 1: Endoscopic view of guidewire placement and stent deployment (a-c), plane X-ray abdomen showing stent position (d), oral barium contrast study showing passage of contrast through self-expanding metal stent (e)

over the guidewire through the working channel of endoscope and deployed across the stricture with endoscopic as well as fluoroscopic guidance.

Technical success

In various studies, technical success is defined as adequate positioning and deployment of stent across the stricture with relief of obstruction, usually confirmed by performing water-soluble contrast study. Technical success rate in various studies is 92%–100%.^[38–42] Jung *et al.*^[38] evaluated outcomes of endoscopically placed SEMS in 220 patients with malignant GOO, and technical success was achieved in 96.8% (213/220). Causes of technical failure were inability to pass guidewire, acute angulation, and far distal obstruction site. Results of the other studies also showed that common reasons for technical failure include the inability to pass a guidewire across the stricture, failure of the delivery system to release the stent, failure of stent deployment, and stent migration during procedure.^[25,40] Older studies^[43] had

a comparatively less technical success rate, probably because of SEMs used in earlier years were not specifically designed for antral use. A few studies reported balloon dilatation of stent because of inadequate SEMs expansion.^[4] Overall, complete obstruction and inability to pass guidewire across the obstruction remains the major factors behind technical failure.

CLINICAL ASPECT

Clinical success

For objective assessment of level of GOO, a scoring system was created by Adler and Baron.^[13] This GOO scoring system (GOOSS) is considered as a standard scoring system for assessing treatment response in patients with GOO. According to this scoring system, a score of 0 stands for no oral intake, a score of 1 for ability to consume liquids only, a score of 2 for soft solids, and a score of 3 for a low residue or full diet.^[13] In different studies, clinical success is defined as GOOSS >2 or improvement in GOOSS \geq 1 point within a week after procedure.

Clinical success rates in various studies range from 67% to 97%. Shin *et al.*^[44] retrospectively evaluated 122 patients who underwent successful endoscopic SEMs placement for palliation of malignant of GOO. Clinical success was achieved in 99/122 (81.1%) patients. The authors also tried to identify factors associated with clinical failure; results of multivariate analysis revealed that gallbladder cancer ($P = 0.016$, odds ratio [OR]: 6.486, 95% confidence interval [CI], 1.509–59.655), poor performance status (Eastern Cooperative Oncology Group [ECOG] >3) ($P = 0.001$, OR: 10.200, 95% CI, 2.435–42.721), and presence of peritoneal carcinomatosis ($P < 0.001$, OR: 35.71, 95% CI, 5.55–250) were associated with clinical failure of palliative SEMs placement. Proposed theories behind clinical failure in patients with poor performance status are that these patients are usually terminally ill, bedridden, and have low serum albumin level leading to bowel wall edema resulting in decreased intestinal motility. Similarly, patients with malignant ascites also have impaired GI motility causing poor results even after successful SEMs placement. Patients with peritoneal carcinomatosis often have multilevel intestinal obstruction, though not detected accurately in cross-sectional imaging. A systemic review by Dormann *et al.*^[45] included 32 studies and 606 patients with malignant GOO in whom stent placement was attempted. Clinical success was achieved in 89% of 589 patients. Mean time for symptom resolution after stent placement was 4 days. Majority of clinical failures were due to disease-related factors. However, different types of stents were used in different studies cited in this systemic review, and no subgroup analysis was done

between the different types of stents to compare clinical outcomes.

Jung *et al.*^[38] assessed outcomes of endoscopic SEMs placement (fully covered, partially covered, and uncovered) in 220 patients with malignant GOO. Clinical success rates were similar following the placement of fully covered, partially covered, and uncovered SEMs (93.8% vs. 88.3% vs. 84.2%, respectively, $P = 0.476$). Rademacher *et al.*^[46] found that the presence of carcinomatosis was associated with a significantly lower clinical success rate compared to patients with no evidence of peritoneal disease (66.7% vs. 88.6%, $P = 0.036$).

Yamao *et al.*^[47] conducted a multicenter retrospective study in Japan; the rate of clinical failure after stent placement was 11.7% (32/274), and the identified predictive factors for clinical failure were Karnofsky Performance Score (KPS) \leq 50 (OR, 6.63; 95% CI, 2.89–15.20; $P < 0.01$) and stenosis sites \geq 3 in numbers (OR, 6.11; 95% CI, 2.16–17.30; $P < 0.01$).

Survival after stent placement

Results of multiple studies showed that median survival ranges from 49 to 195 days.^[1-4] Oh *et al.*^[39] placed partially covered SEMs in 20 patients to palliate GOO. Five patients died without stent occlusion within 8 weeks. Overall median survival after stent placement was 81 days (IQR: 42.25–153.25)

Rademacher *et al.*^[46] included a larger number of patients (62) with and without evidence of peritoneal carcinomatosis. There was no significant difference in overall survival between patients with or without peritoneal carcinomatosis (median: 48 vs. 70 days, $P = 0.21$), but patients showed significantly longer survival after clinical success of SEMs placement compared to those experiencing clinical failure (median: 14.5 vs. 75 days, $P = 0.0003$). Another study showed a median patient survival of 124 days (IQR: 55.5–224.0 days), being significantly longer in patients with clinical success than in those with failure after stent insertion (188.35 ± 12.93 vs. 80.89 ± 20.19 days, $P = 0.002$).^[38]

Oh *et al.*^[48] studied survival and clinical outcome after stent placement for GOO due to pancreatic cancer compared with nonpancreatic cancer. Overall survival was shorter in patients with pancreatic cancer (13.7 vs. 17.1 months; $P = 0.004$). Chemotherapy after stent placement and the absence of distant metastasis were associated with better survival in both the groups (pancreatic cancer: chemotherapy vs. no chemotherapy, 5.4 vs. 1.5 months, $P = 0.0001$; metastasis vs. no metastasis, 1.8 vs. 4.6, $P = 0.005$; nonpancreatic cancer: chemotherapy vs. no chemotherapy, 9.2 vs. 1.8,

$P = 0.001$; metastasis vs. no metastasis, 2.1 vs. 6.1, $P = 0.009$).

Overall median survival after stent placement for GOO is influenced by underlying comorbidities, patient performance status and clinical success.

Quality of life

There are limited data regarding any improvement in QoL after SEMS placement. In a review of published literature from 2000 to 2007, none of the studies had used standardized questionnaire for objective assessment of QoL before and after SEMS placement. In a review article, 7 out of 41 studies used the Karnofsky Performance Scale before and after stent treatment.^[49] In 2009, Van Hooft *et al.*^[32] studied (DUOFLEX study) the effect in QoL after placement of Wallflex enteral stents in 51 patients with malignant GOO. They found no improvement in global QoL assessed by quality of life questionnaires (European Organisation for Research and Treatment of Cancer [EORTC] QLQ-C30 instrument, EQ-5D including the EuroQol Visual Analog Scale). Schmidt *et al.*^[50] did a prospective observational study to assess QoL in patients with malignant GOO after palliation (both surgical and endoscopic). Endoscopic palliation was done in 24 out of 50 enrolled patients. Overall survival was 94 days (median) in endoscopic stent placement group. EORTC QLQ-C30 instrument was used to assess functional status and cancer-related symptoms. After 3 months of palliation, role functioning, physical functioning, global health status (QOL), and nausea/vomiting improved compared to baseline, but statistically significant difference was seen only in QOL and nausea/vomiting. Cognitive and social functions and other judged parameters assessed by the same instrument such as pain and appetite were not changed after intervention. In the same study, gastric-specific symptoms (assessed using EORTC QOL-STO22 instrument) such as dysphagia, eating restriction, dry mouth, and reflux were significantly improved after stent placement.

Adverse events

Complications of endoscopic SEMS placement can be classified as immediate (within 24 h of procedure), early (from 96 h to 2 weeks of procedure), and late complications, which occur more than 2 weeks after stent placement.^[40,51,52] Immediate and early complications include problems related to sedation, aspiration, bleeding, perforation, stent malposition, and stent migration. Commonly occurring late complications are stent migration, stent occlusion (food impaction and tumor ingrowth and overgrowth), bleeding, perforation, and fistula formation. Complication rate in various studies ranges 0%–30%.^[6,13,53]

In a study by Kim *et al.*,^[54] restenosis occurred in 5/43 (11.6%) patients, mainly within 4 weeks of stent placement, which could be managed successfully by another stent placement. Two patients (3.8%) had distal stent migration, which required another overlapping stent placement. Stent occlusion due to tumor overgrowth occurred in one patient (1.9%) at 331 day and tumor ingrowth in 14 patients (26.4%) at a mean of 78.4 day after stent placement. Median stent patency period was 187 days.

In a systemic review by Dormann *et al.*,^[45] overall complication rate was 28%. Perforation (1.2%), bleeding (0.5%), stent obstruction (17.2%), and stent migration (5.1%) were most commonly occurring major complications. Procedure-related pain occurred in 2.5%.

In a prospective study by Havemann *et al.*,^[55] duodenal perforation occurred in 2 out of 45 patients during guidewire negotiation or biliary stent placement, and both complications were managed surgically.

A systematic review and meta-analysis compared the outcomes after covered and uncovered SEMS placement. Nine trials involving 849 patients were included. Results showed no significant difference in technical success rate (relative risk [RR]: 1.0, 95% CI [0.98, 1.01]), clinical success rate (RR: 1.04, 95% CI [0.98, 1.11]), stent patency (weighted mean difference [WMD]: -0.31 , 95% CI $[-1.73, 1.11]$), overall complications (RR: 1.07, 95% CI [0.87, 1.32]), and re-intervention rate (RR: 1.30, 95% CI [0.92, 1.83]) between covered and uncovered SEMS groups. However, higher migration rate (RR: 3.48, 95% CI [2.16, 5.62], $P < 0.00001$) and lower obstruction rate (RR: 0.42, 95% CI [0.24, 0.73], $P = 0.002$) were seen in covered versus uncovered SEMS groups.^[34]

Yamao *et al.*^[47] conducted a multicenter retrospective study in Japan and assessed the predictors of outcome of SEMS placement in malignant GOO. The early adverse events consisted largely of jaundice ($n = 17$, 6.1%). The early adverse events occurred in 28/277 patients, including hyperamylasemia (1.1%), aspiration pneumonia (1.1%), pancreatitis (0.7%), bleeding (0.7%), and perforation (0.4%). The late adverse events (21/277) included bleeding (3.2%), jaundice (2.5%), and perforation (1.8%). The predictors of adverse events were use of uncovered stents (hazard ratio [HR] for covered stents = 0.27; 95% CI, 0.10–0.69; $P < 0.01$) and lack of chemotherapy after stent placement (HR for chemotherapy after stenting = 0.42; 95% CI, 0.19–0.95; $P = 0.04$). Deployment of two stents in the same session (HR, 854.88; 95% CI, 11.36–64356.6; $P < 0.01$) was associated with perforation. The rate of overall stent dysfunction during follow-up was 16.6% (46/277),

which included tumor ingrowth in 5.8% (16/277), overgrowth in 4.0% (11/277), and stent migration in 4.0% (11/277). The use of covered stent was a predictor of stent migration ($P < 0.01$), while uncovered stent did not predict tumor in-growth. In a recent study from our centre on 114 patients, antral stent could be placed in a shorter time using forward-viewing therapeutic endoscope than a side-viewing endoscope.^[56]

CONCLUSION

Diagnosis of malignant GOO is based on clinical history, examination, imaging, and endoscopy. Endoscopic enteral stent placement is a safe and effective mode of palliation for malignant GOO. Technical success rates of enteral stent placement are very high, and clinical success rates were lower than technical success rates. This discrepancy between technical success and clinical success might be partially explained by underlying GI dysmotility,^[57] distal obstruction secondary to peritoneal carcinomatosis, and anorexia associated with advanced malignancy. Recurrent obstructive symptoms may arise due to tumor ingrowth or overgrowth in a subset of patients, which can be successfully managed with repeat endoscopic stent placement. Finally, enteral stent placement is also associated with improvement in QoL.

Financial support and sponsorship

Nil.

Conflicts of interest

There are no conflicts of interest.

REFERENCES

- Didden P, Spaander MC, de Ridder R, Berk L, van Tilburg AJ, Leeuwenburgh I, *et al.* Efficacy and safety of a partially covered stent in malignant gastric outlet obstruction: A prospective Western series. *Gastrointest Endosc* 2013;77:664-8.
- Tringali A, Didden P, Repici A, Spaander M, Bourke MJ, Williams SJ, *et al.* Endoscopic treatment of malignant gastric and duodenal strictures: A prospective, multicenter study. *Gastrointest Endosc* 2014;79:66-75.
- Kanno Y, Ito K, Fujita N, Noda Y, Kobayashi G, Horaguchi J, *et al.* Efficacy and safety of a WallFlex enteral stent for malignant gastric obstruction. *Dig Endosc* 2013;25:386-91.
- van Hooft JE, Dijkgraaf MG, Timmer R, Siersema PD, Fockens P. Independent predictors of survival in patients with incurable malignant gastric outlet obstruction: A multicenter prospective observational study. *Scand J Gastroenterol* 2010;45:1217-22.
- Cho YK, Kim SW, Hur WH, Nam KW, Chang JH, Park JM, *et al.* Clinical outcomes of self-expandable metal stent and prognostic factors for stent patency in gastric outlet obstruction caused by gastric cancer. *Dig Dis Sci* 2010;55:668-74.
- Mehta S, Hindmarsh A, Cheong E, Cockburn J, Saada J, Tighe R, *et al.* Prospective randomized trial of laparoscopic gastrojejunostomy versus duodenal stenting for malignant gastric outflow obstruction. *Surg Endosc* 2006;20:239-42.
- Weaver DW, Wienczek RG, Bouwman DL, Walt AJ. Gastrojejunostomy: Is it helpful for patients with pancreatic cancer? *Surgery* 1987;102:608-13.
- van Wagenveld BA, Coene PP, van Gulik TM, Rauws EA, Obertop H, Gouma DJ, *et al.* Outcome of palliative biliary and gastric bypass surgery for pancreatic head carcinoma in 126 patients. *Br J Surg* 1997;84:1402-6.
- Nagaraja V, Eslick GD, Cox MR. Endoscopic stenting versus operative gastrojejunostomy for malignant gastric outlet obstruction-a systematic review and meta-analysis of randomized and non-randomized trials. *J Gastrointest Oncol* 2014;5:92-8.
- Telford JJ, Carr-Locke DL, Baron TH, Tringali A, Parsons WG, Gabbriellini A, *et al.* Palliation of patients with malignant gastric outlet obstruction with the enteral wallstent: Outcomes from a multicenter study. *Gastrointest Endosc* 2004;60:916-20.
- Park JM, Min BH, Lee SH, Chung KH, Lee JM, Song BJ, *et al.* Feasibility of self-expandable metal stent placement with side-viewing endoscope for malignant distal duodenal obstruction. *Dig Dis Sci* 2015;60:524-30.
- Sasaki R, Sakai Y, Tsuyuguchi T, Nishikawa T, Fujimoto T, Mikami S, *et al.* Endoscopic management of unresectable malignant gastroduodenal obstruction with a nitinol uncovered metal stent: A prospective Japanese multicenter study. *World J Gastroenterol* 2016;22:3837-44.
- Adler DG, Baron TH. Endoscopic palliation of malignant gastric outlet obstruction using self-expanding metal stents: Experience in 36 patients. *Am J Gastroenterol* 2002;97:72-8.
- Song HY, Shin JH, Yoon CJ, Lee GH, Kim TW, Lee SK, *et al.* A dual expandable nitinol stent: Experience in 102 patients with malignant gastroduodenal strictures. *J Vasc Interv Radiol* 2004;15:1443-9.
- Lye TJ, Goh YC, Eng AK, Ong HS, Wong WK, Chan WH, *et al.* Endoscopic self-expandable metallic stenting for palliation of malignant gastric outlet obstruction in Southeast Asia. *ANZ J Surg* 2016;86:464-8.
- Misra SP, Dwivedi M, Misra V. Malignancy is the most common cause of gastric outlet obstruction even in a developing country. *Endoscopy* 1998;30:484-6.
- Sukumar V, Ravindran C, Prasad RV. Demographic and etiological patterns of gastric outlet obstruction in Kerala, South India. *N Am J Med Sci* 2015;7:403-6.
- Sikora SS, Kapoor R, Pradeep R, Kapoor VK, Saxena R, Kaushik SP, *et al.* Palliative surgical treatment of malignant obstructive jaundice. *Eur J Surg Oncol* 1994;20:580-4.
- Gaidos JK, Draganov PV. Treatment of malignant gastric outlet obstruction with endoscopically placed self-expandable metal stents. *World J Gastroenterol* 2009;15:4365-71.
- Lau JY, Chung SC, Sung JJ, Chan AC, Ng EK, Suen RC, *et al.* Through-the-scope balloon dilation for pyloric stenosis: Long-term results. *Gastrointest Endosc* 1996;43:98-101.
- Del Piano M, Ballarè M, Montino F, Todesco A, Orsello M, Magnani C, *et al.* Endoscopy or surgery for malignant GI outlet obstruction? *Gastrointest Endosc* 2005;61:421-6.
- Bozzetti F, Bonfanti G, Audisio RA, Doci R, Dossena G, Gennari L, *et al.* Prognosis of patients after palliative surgical procedures for carcinoma of the stomach. *Surg Gynecol Obstet* 1987;164:151-4.
- Ly J, O'Grady G, Mittal A, Plank L, Windsor JA. A systematic review of methods to palliate malignant gastric outlet obstruction. *Surg Endosc* 2010;24:290-7.
- Mittal A, Windsor J, Woodfield J, Casey P, Lane M. Matched study of three methods for palliation of malignant pyloroduodenal obstruction. *Br J Surg* 2004;91:205-9.
- Jeurnink SM, van Eijck CH, Steyerberg EW, Kuipers EJ, Siersema PD. Stent versus gastrojejunostomy for the palliation of gastric outlet obstruction: A systematic review. *BMC*

- Gastroenterol 2007;7:18.
26. Khashab MA, Kumbhari V, Grimm IS, Ngamruengphong S, Aguila G, El Zein M, *et al.* EUS-guided gastroenterostomy: The first U.S. Clinical experience (with video). *Gastrointest Endosc* 2015;82:932-8.
 27. Chen YI, Itoi T, Baron TH, Nieto J, Haito-Chavez Y, Grimm IS, *et al.* EUS-guided gastroenterostomy is comparable to enteral stenting with fewer re-interventions in malignant gastric outlet obstruction. *Surg Endosc* 2017;31:2946-52.
 28. Song HY, Yang DH, Kuh JH, Choi KC. Obstructing cancer of the gastric antrum: Palliative treatment with covered metallic stents. *Radiology* 1993;187:357-8.
 29. Strecker EP, Boos I, Husfeldt KJ. Malignant duodenal stenosis: Palliation with peroral implantation of a self-expanding nitinol stent. *Radiology* 1995;196:349-51.
 30. Wai CT, Ho KY, Yeoh KG, Lim SG. Palliation of malignant gastric outlet obstruction caused by gastric cancer with self-expandable metal stents. *Surg Laparosc Endosc Percutan Tech* 2001;11:161-4.
 31. Kim GH, Kang DH, Lee DH, Heo J, Song GA, Cho M, *et al.* Which types of stent, uncovered or covered, should be used in gastric outlet obstructions? *Scand J Gastroenterol* 2004;39:1010-4.
 32. van Hooff JE, Uitdehaag MJ, Bruno MJ, Timmer R, Siersema PD, Dijkgraaf MG, *et al.* Efficacy and safety of the new WallFlex enteral stent in palliative treatment of malignant gastric outlet obstruction (DUOFLEX study): A prospective multicenter study. *Gastrointest Endosc* 2009;69:1059-66.
 33. Kim CG, Choi IJ, Lee JY, Cho SJ, Park SR, Lee JH, *et al.* Covered versus uncovered self-expandable metallic stents for palliation of malignant pyloric obstruction in gastric cancer patients: A randomized, prospective study. *Gastrointest Endosc* 2010;72:25-32.
 34. Pan YM, Pan J, Guo LK, Qiu M, Zhang JJ. Covered versus uncovered self-expandable metallic stents for palliation of malignant gastric outlet obstruction: A systematic review and meta-analysis. *BMC Gastroenterol* 2014;14:170.
 35. Maetani I, Mizumoto Y, Shigoka H, Omuta S, Saito M, Tokuhisa J, *et al.* Placement of a triple-layered covered versus uncovered metallic stent for palliation of malignant gastric outlet obstruction: A multicenter randomized trial. *Dig Endosc* 2014;26:192-9.
 36. Lim SG, Kim JH, Lee KM, Shin SJ, Kim CG, Kim KH, *et al.* Conformable covered versus uncovered self-expandable metallic stents for palliation of malignant gastroduodenal obstruction: A randomized prospective study. *Dig Liver Dis* 2014;46:603-8.
 37. Lee H, Min BH, Lee JH, Shin CM, Kim Y, Chung H, *et al.* Covered metallic stents with an anti-migration design vs. Uncovered stents for the palliation of malignant gastric outlet obstruction: A multicenter, randomized trial. *Am J Gastroenterol* 2015;110:1440-9.
 38. Jung K, Ahn JY, Jung HY, Cho CJ, Na HK, Jung KW, *et al.* Outcomes of endoscopically inserted self-expandable metal stents in malignancy according to the type of stent and the site of obstruction. *Surg Endosc* 2016;30:4001-10.
 39. Oh D, Lee SS, Song TJ, Choi JH, Park DH, Seo DW, *et al.* Efficacy and safety of a partially covered duodenal stent for malignant gastroduodenal obstruction: A pilot study. *Gastrointest Endosc* 2015;82:32-60.
 40. Nassif T, Prat F, Meduri B, Fritsch J, Choury AD, Dumont JL, *et al.* Endoscopic palliation of malignant gastric outlet obstruction using self-expandable metallic stents: Results of a multicenter study. *Endoscopy* 2003;35:483-9.
 41. Maetani I, Ukita T, Tada T, Shigoka H, Omuta S, Endo T. Metallic stents for gastric outlet obstruction: Reintervention rate is lower with uncovered versus covered stents, despite similar outcomes. *Gastrointest Endosc* 2009;69:806-12.
 42. Phillips MS, Gosain S, Bonatti H, Friel CM, Ellen K, Northup PG, *et al.* Enteral stents for malignancy: A report of 46 consecutive cases over 10 years, with critical review of complications. *J Gastrointest Surg* 2008;12:2045-50.
 43. Mosler P, Mergener KD, Brandabur JJ, Schembre DB, Kozarek RA. Palliation of gastric outlet obstruction and proximal small bowel obstruction with self-expandable metal stents: A single center series. *J Clin Gastroenterol* 2005;39:124-8.
 44. Shin YS, Choi CW, Kang DH, Kim HW, Kim SJ, Cho M, *et al.* Factors associated with clinical failure of self-expandable metal stent for malignant gastroduodenal obstruction. *Scand J Gastroenterol* 2016;51:103-10.
 45. Dormann A, Meisner S, Verin N, Wenk Lang A. Self-expanding metal stents for gastroduodenal malignancies: Systematic review of their clinical effectiveness. *Endoscopy* 2004;36:543-50.
 46. Rademacher C, Bechtler M, Schneider S, Hartmann B, Striegel J, Jakobs R. Self-expanding metal stents for the palliation of malignant gastric outlet obstruction in patients with peritoneal carcinomatosis. *World J Gastroenterol* 2016;22:9554-61.
 47. Yamao K, Kitano M, Kayahara T, Ishida E, Yamamoto H, Minaga K, *et al.* Factors predicting through-the-scope gastroduodenal stenting outcomes in patients with gastric outlet obstruction: A large multicenter retrospective study in west japan. *Gastrointest Endosc* 2016;84:757-63. e6.
 48. Oh SY, Edwards A, Mandelson M, Ross A, Irani S, Larsen M, *et al.* Survival and clinical outcome after endoscopic duodenal stent placement for malignant gastric outlet obstruction: Comparison of pancreatic cancer and nonpancreatic cancer. *Gastrointest Endosc* 2015;82:460-800.
 49. Larssen L, Medhus AW, Hauge T. Treatment of malignant gastric outlet obstruction with stents: An evaluation of the reported variables for clinical outcome. *BMC Gastroenterol* 2009;9:45.
 50. Schmidt C, Gerdes H, Hawkins W, Zucker E, Zhou Q, Riedel E, *et al.* A prospective observational study examining quality of life in patients with malignant gastric outlet obstruction. *Am J Surg* 2009;198:92-9.
 51. Masci E, Viale E, Mangiavillano B, Contin G, Lomazzi A, Buffoli F, *et al.* Enteral self-expandable metal stent for malignant luminal obstruction of the upper and lower gastrointestinal tract: A prospective multicentric study. *J Clin Gastroenterol* 2008;42:389-94.
 52. Lopes CV, Pesenti C, Bories E, Caillol F, Giovannini M. Self-expandable metallic stents for palliative treatment of digestive cancer. *J Clin Gastroenterol* 2008;42:991-6.
 53. Espinel J, Vivas S, Muñoz F, Jorquera F, Olcoz JL. Palliative treatment of malignant obstruction of gastric outlet using an endoscopically placed enteral wallstent. *Dig Dis Sci* 2001;46:2322-4.
 54. Kim TO, Kang DH, Kim GH, Heo J, Song GA, Cho M, *et al.* Self-expandable metallic stents for palliation of patients with malignant gastric outlet obstruction caused by stomach cancer. *World J Gastroenterol* 2007;13:916-20.
 55. Havemann MC, Adamsen S, Wøjdemann M. Malignant gastric outlet obstruction managed by endoscopic stenting: A prospective single-centre study. *Scand J Gastroenterol* 2009;44:248-51.
 56. Kumar V, Ghoshal UC, Mohindra S, Saraswat VA. Palliation of malignant gastroduodenal obstruction with self-expandable metal stent using side- and forward-viewing endoscope: Feasibility and outcome. *JGH Open*. 2018;3:65-70.
 57. Sachdeva S, Ghoshal UC, Saraswat VA, Das K, Misra A. Gastroduodenal dysmotility in patients with gallbladder carcinoma: Frequency of occurrence and clinical importance. *Natl Med J India* 2006;19:4-9.