

Original Article

Self-Expanding Metallic Stents in Malignant Biliary Obstruction-Patency and Clinical Efficacy: A Prospective Study from North India Tertiary Center

Ankit Gupta, Gaurav Kumar Gupta, Atul Gawande, Manoj Kumar, Vijyant Tak, Rupesh Kumar Pokharna, Shyam Sundar Sharma, Sandeep Nijhawan

Department of
Gastroenterology, SMS
Hospital, Jaipur, Rajasthan,
India

ABSTRACT **Background and Aims:** Endoscopic insertion of self-expandable metallic stent (SEMS) is now accepted as first line modality of treatment for palliation in unresectable extra-hepatic biliary obstructive jaundice. This study was done to assess the clinical efficacy and duration of patency of endoscopically inserted metallic stent in unresectable malignant biliary obstruction. **Materials and Methods:** Between 2015 to 2017, 101 patients who underwent ERCP and SEMS placement for palliation of malignant biliary obstruction were included prospectively. Main outcome measures were technical success, clinical success, mean duration of SEMS patency, clinical efficacy, rate of biliary re-intervention and survival of patients. **Results:** Overall technical success and clinical success was achieved in 93% and 82.2% respectively. Mean duration of SEMS patency was 109 days. Analysis in subgroup of patients classified according to site of obstruction (Hilar -68, Distal CBD-33) showed that median duration of stent patency was significantly better in distal biliary stricture (135 days vs 95 days), whereas re-intervention rates were higher in higher biliary stricture than distal stricture (41% Vs 6%). Seven patients with hilar biliary stricture suffered post-SEMS insertion cholangitis. **Conclusion:** SEMS placement is feasible palliative method for unresectable malignant biliary obstruction with acceptable technical and clinical success. The duration of SEMS patency and clinical efficacy is significantly better in distal biliary stricture whereas re-intervention rate is higher in hilar biliary stricture.

KEYWORDS: Malignant biliary obstruction, palliation, self-expanding metallic stent

INTRODUCTION

Extrahepatic biliary obstruction is one of the common causes of cholestatic jaundice which can be benign or malignant in nature. Gallbladder carcinoma, pancreatic carcinoma, ampullary carcinoma, cholangiocarcinoma, and metastases to the peripancreatic and hilar lymph nodes are common causes of malignant biliary obstruction. Advances in therapeutic endoscopy and interventional radiology have now made it possible to relieve biliary obstruction without undergoing open surgery. Endoscopic biliary stenting as a palliative measure has become the first-line modality for patients with malignant biliary obstruction.^[1] Endoscopic stent

effectively reestablishes bile flow; alleviates jaundice, cholangitis, and pruritus; and may improve quality of life.^[2,3] Estimated life expectancy of a patient is an important parameter to select the type of stent. In patients with localized disease who are candidates for surgical resection and those having widespread liver metastasis

Address for correspondence: Dr. Gaurav Kumar Gupta,
Department of Gastroenterology, SMS Hospital, Jaipur,
Rajasthan, India.
E-mail: kumarggauravpgi@gmail.com

This is an open access journal, and articles are distributed under the terms of the Creative Commons Attribution-NonCommercial-ShareAlike 4.0 License, which allows others to remix, tweak, and build upon the work non-commercially, as long as appropriate credit is given and the new creations are licensed under the identical terms.

For reprints contact: reprints@medknow.com

How to cite this article: Gupta A, Gupta GK, Gawande A, Kumar M, Tak V, Pokharna RK, et al. Self-expanding metallic stents in malignant biliary obstruction-patency and clinical efficacy: A prospective study from North India tertiary center. J Dig Endosc 2019;10:XX-XX.

Access this article online

Quick Response Code:



Website: www.jdeonline.in

DOI: 10.4103/jde.JDE_52_18

with short life expectancy of <3 months, placement of plastic stent is well accepted; whereas, in unresectable patients and who are likely to live longer than 6 months, self-expanding metallic stents (SEMSs) have demonstrated reduced complications, shorter hospital stay, less reintervention rates, and reduced overall cost as compared to plastic stents.^[4]

Stent occlusion is the primary clinical problem related to the placement of endoprosthesis (plastic stent/SEMS), leading to stagnation of bile with infection causing life-threatening cholangitis. It often requires reintervention with attempts to restore biliary drainage.

Typically, plastic stents become occluded with sludge because of their small diameter (7–11.5 Fr).^[5,6] Enlarging the diameter of plastic stent appears to be a solution; however, diameter is limited by the endoscopic delivery system. In contrast, metal stents have the ability to expand after deployment. SEMSs which are 2–3 mm in diameter can reach a diameter of 8–10 mm in the bile duct.

This study was designed to assess the clinical efficacy and duration of patency of endoscopically inserted metallic stent for unresectable malignant biliary obstruction.

METHODS AND MATERIALS

This study was conducted as a prospective, uncontrolled, single-center study in Sawai Man Singh Hospital, Jaipur, Rajasthan. This study was approved by the institute ethics committee. Patients who underwent biliary SEMS insertion for palliation were included during January 2015–December 2017. Diagnosis of malignancy was based on histological and cytological background. Patients were assessed for surgical resection based on the performance status of the patient and stage of the tumor on computed tomography scan and were found to be unresectable.

All patients required biliary decompression with endoscopic retrograde cholangiopancreatography (ERCP) for intractable pruritus, cholangitis, or as a measure to decrease serum bilirubin before undergoing chemotherapy.

Inclusion criteria

Patients with (1) age of 15 years or older, (2) the presence of unresectable malignant extrahepatic biliary obstruction, (3) clinical symptoms of biliary obstruction, and (4) willingness to comply with study procedure and provide signed informed consent were included in the study.

Exclusion criteria

Patients with (1) the presence of gastric outlet obstruction, (2) a history of previous biliary intervention, and (3) contraindications to endoscopy were excluded from the study.

Biochemical tests of liver functions were obtained at the baseline; 7 days after metal stent placement; and electively at 1, 3, and 6 months or if there is clinical evidence of stent dysfunction.

Patients were followed up prospectively at 1, 3, and 6 months, at any clinical evidence of stent dysfunction or death. Informed consent was obtained from patients for the procedure.

Self-expanding metal stent insertion and deployment

All patients received preprocedural antibiotics. Premedication with midazolam, pentazocine, and hyoscine was permitted. Patients underwent ERCP with a standard duodenoscope (accessory channel diameter 3.2 mm, Olympus 160 series). Standard technique was used to cannulate the biliary tract, and biliary aspiration was done with a syringe to decrease the biliary pressure and risk of cholangitis. Air cholangiogram was obtained to identify the location and length of biliary stricture. Metallic stent (uncovered) was deployed over the guidewire (0.025 inch, VisiGlide) across the stricture. Two types of uncovered metallic stents, Taewoong Niti-S or Boston Scientific WallFlex, were used. The length of the stent was chosen according to the length of the stricture, so that the stent extended at least 2 cm beyond the tumor margins.

Proper stent insertion was confirmed under endoscopic vision and on fluoroscopy.

Outcome

Outcome measures were technical success, clinical success, mean duration of stent patency, clinical efficacy of stent, rate of biliary reintervention, and survival of patients.

Definition of events

A diagnosis of cholangitis was defined as persistent, documented fever (temperature >38.3°C) lasting for more than 24 h together with biochemical evidence of cholestasis, in the absence of another discernible cause.

Technical success was defined as the successful passage of stent across the stricture, with good radiographic positioning, along with flow of bile seen through the stent.

Clinical success was defined as successful biliary drainage after stent deployment with the relief of

jaundice, pruritus, and cholangitis along with a reduction in serum bilirubin by at least 50% of baseline at day 7 after stent placement.

Stent dysfunction was defined as recurrence of jaundice, pruritus, or cholangitis confirmed by deranged cholestatic parameters and sonographic evidence of dilated intrahepatic biliary radicles. Whenever stent dysfunction was confirmed, additional biliary drainage was done with plastic stent, percutaneous transhepatic biliary drainage, or another metallic stent.

Stent patency was defined as the following time periods:

1. Time interval between stent insertion and stent dysfunction
2. Time interval between stent placement and the end of the study period if a patient was alive and experienced no stent dysfunction till the end of the study period
3. Time until death if a patient died during the study period.

Clinical efficacy of a stent was calculated as occlusion rate of the stent; occlusion rate is expressed as the percentage of stent occluded during the study period.

Biliary reintervention was defined as any type of endoscopic or percutaneous procedure that was required to improve biliary drainage after stent insertion.

Follow-up evaluation

Biochemical parameters were obtained at day 7 and 1, 3, and 6 months following stent insertion. Patients were subsequently evaluated at 1, 3, and 6 months after stent placement for reappearance of biliary obstructive symptoms. All patients were advised to contact the hospital if any symptoms suggestive of stent dysfunction were noted by the patient. Additional information regarding death was obtained telephonically. Follow-up continued for 6 months following stent insertion or till death of the patient.

Statistical analysis

All data were coded and entered into the computer using SPSS for Windows, Version 18.0. (SPSS Inc., Chicago, Illinois)

The qualitative data were analyzed using Chi-square test, and the quantitative data were analyzed using *z*-test. The survival data were analyzed by the Kaplan–Meier method. The statistical significance of difference in patient survival between the two groups was tested with log-rank test.

P < 0.05 was considered statistically significant.

RESULTS

A total of 101 patients (66 males and 35 females) with malignant extrahepatic biliary obstruction were included. Their mean age was 61 ± 12 years and their biochemical characteristics are tabulated in Table 1.

Forty-seven patients had gallbladder cancer, twenty-five patients had cholangiocarcinoma, twenty-two had pancreatic cancer, and seven patients had ampullary carcinoma. Histological material was obtained by percutaneous fine-needle aspiration in 57 patients, endosonographic fine-needle aspiration in 26 patients, bile duct brush cytology in 13 patients, and endoscopic biopsy of ampullary mass in 5 patients. Sixty-eight patients had stricture at the biliary bifurcation. The hilar strictures were characterized according to the Bismuth–Corlette classification as hilar Type 1 (*n* = 49) and hilar Type 2 (*n* = 19). Patients with Type 3 and Type 4 underwent imaging-guided percutaneous biliary drainage. Thirty-three patients had a distal biliary stricture [Table 2].

Table 1: Baseline parameters of subjects

Parameter	Range	Mean±SD	Median value
Age (years)	26-87	61.76±12.01	62
Serum Bilirubin (total in mg %)	8.6-22.8	16.10±3.55	16.6
S. Bil (direct fraction in mg %)	4.6-18.8	9.91±2.53	
AST (units/liter)	41-346	137.83±50.79	132
ALT (units/liter)	48-284	138.51±47.49	142
ALP (IU/L)	280-1268	758.19±214.12	782

SD: Standard deviation; S. Bil: Serum bilirubin

Table 2: Patient distribution according to the diagnosis and type of block

Diagnosis	Type of block		Total
	Hilar	Lower CBD	
Gallbladder cancer	47 (46.53)	0 (0.00)	47 (46.53)
Cholangiocarcinoma	21 (20.79)	4 (3.96)	25 (24.75)
Pancreatic cancer	0 (0.00)	22 (21.78)	22 (21.78)
Ampullary cancer	0 (0.00)	7 (6.93)	7 (6.93)
Total, <i>n</i> (%)	68 (67.33)	33 (32.67)	101 (100.00)

CBD: Common bile duct, GB: Gall bladder

Table 3: Technical and clinical success of biliary self-expanding metallic stent

Site of biliary obstruction	Total number of patients (<i>n</i>)	Technical success, <i>n</i> (%)	Clinical success, <i>n</i> (%)
Hilar	68	62 (91.2)	52 (76.5)
Distal	33	32 (97)	31 (94)
<i>P</i>		0.95 (NS)	0.61 (NS)

NS: Not significant

Technical failure was seen in 7 patients (hilar in 6 and distal in 1) due to inability to pass the guidewire across the stricture, and these patients were managed with percutaneous biliary drainage. Clinical success, as defined by a decline in serum bilirubin at day 7 by at least 50% of baseline,^[7] was seen in 82.2% of the patients. There was no significant difference in clinical success between hilar and distal biliary strictures [Table 3].

Seven patients developed cholangitis in immediate post-ERCP period and were managed effectively with percutaneous drainage in the other ductal system. All patients who developed cholangitis had hilar stricture. No other complication related to stent insertion was seen.

Overall, the median duration of stent patency was 109 days ± 58 days. The duration of stent patency was found to be significantly better in distal biliary stricture (135.15 days vs. 95.29 days).

Clinical efficacy of the stent at the end of the study period was 54.5% (55/101), i.e., only 55 patients had patent stent at the end of 6 months. Efficacy was significantly better in the distal location of stricture as compared to hilar stricture (90.9% vs. 36.7%) [Table 4].

A total of thirty patients required biliary reintervention for stent dysfunction. Seventeen patients were drained with plastic stent, eight patients were drained percutaneously, and in five patients another metallic stent

was placed. The rate of reintervention was significantly more in hilar biliary stricture (41.1% vs. 6%) [Table 4].

Overall, 43 of our patients were considered for chemotherapy. The mean duration of SEMS patency was higher in the patients receiving chemotherapy as compared to those who did not receive chemotherapy (127 days vs. 94 days, $P > 0.05$).

In a Kaplan–Meier curve analysis, overall median survival of patients was 129 days. The two survival curves based on the location of stricture did not differ significantly [Figure 1]. Six months after the stent insertion, 43 patients remained alive with a patent stent. Survival at 6 months was significantly better in those who achieved clinical success after stent insertion (48.19% vs. 16.66%, $X^2 = 4.792$, d.f = 1, $P < 0.05$).

DISCUSSION

The endoscopic drainage is now the accepted norm for patients requiring the palliation of malignant extrahepatic biliary obstruction, as it provides a good quality of life to patients in the terminal stage of their lives.^[1]

In our study, the technical and clinical success rates of metallic stent were comparable to previously reported series (93% and 82.2%, respectively).^[8,9]

The mean follow-up period was for 6 months following stent placement.

The difference between hilar and distal location of stricture was not statistically significant ($P > 0.05$). Similar to previously reported series, deployment problems (failure to pass the guidewire through the stricture) were the main cause behind the technical failure in our study.^[10,11] Seven patients with hilar stricture developed post-ERCP cholangitis possibly due to incomplete biliary drainage in these patients.

The mean survival of the patients was around 4 months (129 days) and was independent of the location of biliary stricture. The survival of the patients who achieved clinical success was found to be significantly better than those who had a minimal improvement in cholestatic parameters post-SEMS placement. Thus, failure to achieve clinical success could be used as a prognostic marker to predict poor survival in these patients.

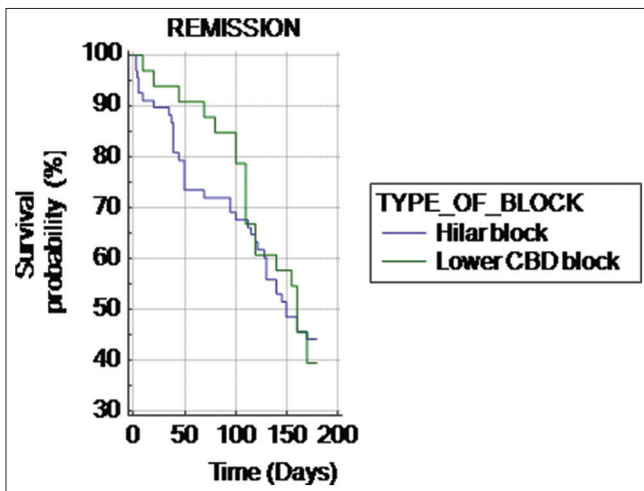


Figure 1: Survival curve of hilar and lower common bile duct block after biliary self-expanding metal stents

Table 4: Duration of stent patency (days), reintervention rate, and clinical efficacy of biliary self-expanding metallic stent

	Location of stricture		P
	Hilar (%)	Distal CBD (%)	
Duration of stent patency (days)	95.29±57.24	135.15±49.69	<0.001
Reintervention rate, n (%)	28/68 (41.2)	2/33 (6)	<0.001
Clinical efficacy (number of patent stent at the end of the study), n (%)	25/68 (36.8)	30/33 (90.9)	<0.0001

CBD: Common bile duct

Although metal stents are expensive, they are preferred over plastic stents due to their inherent characteristic of large diameter and long patency as compared to plastic stents. This indirectly reduces the overall health-care cost as they are less prone to occlusion and thus less number of hospitalization.

The present study revealed the mean age of the patients to be 61 years, with a range of 26–87 years. Although malignancy is considered a rare occurrence in young adults, in this study, the youngest patient was diagnosed with gallbladder malignancy at the age of 26 years, thus emphasizing the need of routinely carrying out the histopathological examination of cholecystectomy specimen even in young adults.

The most striking outcome of this study is the relatively short median stent patency rate, with a median of 109 days. Stent dysfunction occurs in natural course of these patients due to stent migration, tumor ingrowth, or sludge impaction causing stent occlusion. In contrast, previous prospective uncontrolled long-term studies showed median stent patency rate of 23–41 weeks.^[12,13] Another study also found a high patency rate with a median of 68.14 weeks.^[14] The reason for a short duration of patency in our study can partly be explained by the fact that a large number of our patients presented at an advanced stage with short life expectancy. Furthermore, there were a larger proportion of patients with hilar stricture in our study. Most prospective uncontrolled studies showed that the location of biliary stricture did not have any significant effect on the duration of patency of the stent.^[9,15] However, our study showed that the duration of stent patency was more in distal location of stricture (135 days vs. 95 days), and the difference was clinically significant ($P < 0.05$). Consequently, reintervention was more commonly required in patients with hilar biliary stricture as compared to distal stricture (41% vs. 6%). Whereas relatively long patency duration was seen in a patient with distal obstruction, the outcome was much worse for hilar tumors requiring more number of reintervention. Subsequently, clinical efficacy of the stent was better in distal biliary stricture compared to hilar stricture. In this respect, our study is in contrast with Chen *et al.*, who showed better stent patency of SEMS in patients with hilar than with distal biliary stricture (421 days vs. 168 days).^[16]

Although our study was not intended to assess the effects of chemotherapy on SEMS patency, patients who received palliative chemotherapy had long duration of stent patency as compared to those who were not considered for chemotherapy (127 days vs. 94 days). This is in stark contrast to previous studies which reported that chemotherapy might reduce the stent

patency as immunosuppression can result in bacterial colonization of the stent.^[17,18]

The favorable effects of chemotherapy on the duration of stent patency in our study can be explained by slowing of the rate of tumor growth with chemotherapy.

CONCLUSION

SEMS implantation is a feasible mode of palliation in inoperable malignant biliary obstruction with acceptable technical and clinical success. The location of biliary stricture does not have any significant effect on the clinical and technical success of biliary drainage by SEMS. However, patients who achieve clinical success have a better survival.

The median duration of SEMS patency and clinical efficacy is significantly better in distal stricture, and consequently, reintervention rates are lesser than in patients with hilar biliary stricture.

Larger prospective studies to confirm the effects of chemotherapy on the duration of stent patency are recommended.

Limitations

Efficacy and duration of stent patency are difficult to estimate in malignant biliary obstruction due to short survival of these patients, which is 4 months in our series. Real estimation of stent patency can only be obtained in those patients who have life expectancy long enough to have stent occluded during the follow-up. However, we considered the time to death from stent insertion as equivalent to the duration of stent patency in these patients. This could be one of the reasons accounting for a short duration of SEMS patency in our series.

Financial support and sponsorship

Nil.

Conflicts of interest

There are no conflicts of interest.

REFERENCES

1. Smith AC, Dowsett JF, Russell RC, Hatfield AR, Cotton PB. Randomised trial of endoscopic stenting versus surgical bypass in malignant low bileduct obstruction. *Lancet* 1994;344:1655-60.
2. Ballinger AB, McHugh M, Catnach SM, Alstead EM, Clark ML. Symptom relief and quality of life after stenting for malignant bile duct obstruction. *Gut* 1994;35:467-70.
3. Abraham NS, Barkun JS, Barkun AN. Palliation of malignant biliary obstruction: A prospective trial examining impact on quality of life. *Gastrointest Endosc* 2002;56:835-41.
4. Yeoh KG, Zimmerman MJ, Cunningham JT, Cotton PB. Comparative costs of metal versus plastic biliary stent strategies for malignant obstructive jaundice by decision analysis. *Gastrointest Endosc* 1999;49:466-71.

5. Raju RP, Jaganmohan SR, Ross WA, Davila ML, Javle M, Raju GS, *et al.* Optimum palliation of inoperable hilar cholangiocarcinoma: Comparative assessment of the efficacy of plastic and self-expanding metal stents. *Dig Dis Sci* 2011;56:1557-64.
6. Rerknimitr R, Kladcharoen N, Mahachai V, Kullavanijaya P. Result of endoscopic biliary drainage in hilar cholangiocarcinoma. *J Clin Gastroenterol* 2004;38:518-23.
7. Saluja SS, Gulati M, Garg PK, Pal H, Pal S, Sahni P, *et al.* Endoscopic or percutaneous biliary drainage for gallbladder cancer: A randomized trial and quality of life assessment. *Clin Gastroenterol Hepatol* 2008;6:944-50.e3.
8. Davids PH, Groen AK, Rauws EA, Tytgat GN, Huibregtse K. Randomised trial of self-expanding metal stents versus polyethylene stents for distal malignant biliary obstruction. *Lancet* 1992;340:1488-92.
9. Knyrim K, Wagner HJ, Pausch J, Vakil N. A prospective, randomized, controlled trial of metal stents for malignant obstruction of the common bile duct. *Endoscopy* 1993;25:207-12.
10. Rieber A, Brambs HJ. Metallic stents in malignant biliary obstruction. *Cardiovasc Intervent Radiol* 1997;20:43-9.
11. Arguedas MR, Heudebert GH, Stinnett AA, Wilcox CM. Biliary stents in malignant obstructive jaundice due to pancreatic carcinoma: A cost-effectiveness analysis. *Am J Gastroenterol* 2002;97:898-904.
12. Schöfl R, Brownstone E, Reichel W, Fortunat W, Doblhofer F, Samec HJ, *et al.* Malignant bile-duct obstruction: Experience with self-expanding metal endoprostheses (Wallstents) in Austria. *Endoscopy* 1994;26:592-69.
13. O'Brien S, Hatfield AR, Craig PI, Williams SP. A three year follow up of self expanding metal stents in the endoscopic palliation of longterm survivors with malignant biliary obstruction. *Gut* 1995;36:618-21.
14. Ferlitsch A, Oesterreicher C, Dumonceau JM, Deviere J, Leban T, Born P, *et al.* Diamond stents for palliation of malignant bile duct obstruction: A prospective multicenter evaluation. *Endoscopy* 2001;33:645-50.
15. Brountzos EN, Petropoulos E, Kelekis NL, Magoulas D, Alexopoulou E, Kagianni E, *et al.* Malignant biliary obstruction: Management with percutaneous metallic stent placement. *Hepatogastroenterology* 1999;46:2764-71.
16. Chen JH, Sun CK, Liao CS, Chua CS. Self-expandable metallic stents for malignant biliary obstruction: Efficacy on proximal and distal tumors. *World J Gastroenterol* 2006;12:119-22.
17. Aadam AA, Evans DB, Khan A, Oh Y, Dua K. Efficacy and safety of self-expandable metal stents for biliary decompression in patients receiving neoadjuvant therapy for pancreatic cancer: A prospective study. *Gastrointest Endosc* 2012;76:67-75.
18. Lofts FJ, Evans TR, Mansi JL, Glees JP, Knight MJ. Bile duct stents: Is there an increased rate of complications in patients receiving chemotherapy? *Eur J Cancer* 1997;33:209-13.