Published online: 2019-09-24

Case Report

Migration of Pigtail Biliary Stent through Surface of the Left Lobe of Liver

Bhavik Bharat Shah, Usha Goenka[1], Debashish Banerjee[2], Vijay Rai, Mahesh Kumar Goenka

Institute of Gastrosciences and Liver, Apollo Gleneagles Hospital, Departments of [1]Radiology and [2]Surgery, Apollo Gleneagles Hospital, Kolkata, West Bengal, India

Abstract

We report a rare case of a patient of choledocholithiasis who underwent CBD stone removal with pigtail biliary stenting four year back, presenting with proximal migration of stent piercing the left lobe of liver. The stent was removed at laparotomy, by doing hepatotomy. We discuss this unreported case of proximal migration of pigtail biliary stent through surface of left lobe of liver.

Keywords: *Hepatotomy, left lobe of liver, migration, pigtail biliary stent*

Introduction

The complication rate associated with biliary stenting ranges from 8% to 10%,[1] and the documented complications include cholangitis, cholecystitis, duodenal perforation, bleeding, pancreatitis, stent fracture, stent migration, and stent occlusion, resulting in recurrent biliary obstruction.[2] Stents may migrate either proximally or distally usually as a late complication of endoscopic stenting in 5%–10% of patients undergoing biliary stenting.[3] It has been noted that longer duration of stenting may be associated with unusual complications. Here, we present a case of a proximal migration of pigtail biliary stent migration in the perforation of liver capsule.

Case Report

A 57-year-old male patient presented to the hospital with complaints of high-grade intermittent fever accompanied by chills for 10 days. There was no history of cough, abdominal pain, jaundice, or any urinary symptoms. He had a history of gastrojejunostomy for peptic ulcer disease 30 years back and cholecystectomy for symptomatic cholelithiasis 20 years back. Four years back, the patient presented with features of choledocholithiasis and cholangitis. Rendezvous procedure (percutaneous placement of biliary guidewire) was done in view of difficult common bile duct (CBD) cannulation and CBD stones were removed after endoscopic sphincterotomy. A 7 Fr × 10 cm pigtail biliary stent was placed. The stent was not removed during follow-up. The patient was symptom-free thereafter until the presentation with fever this time.

Access this article online

Quick Response Code:

Website: www.jdeonline.in

DOI: 10.4103/jde.JDE_4_18

On admission this time, the patient had temperature of 101.4°F, blood pressure of 130/80 mmHg, respiratory rate of 20/min, and heart rate of 110/min. Routine blood tests including complete blood counts, liver function tests, and renal functions tests were normal. Blood and urine cultures were sterile. The patient was initiated on empirical antibiotics. Ultrasonography and magnetic resonance cholangiopancreatography of the abdomen done showed mild intrahepatic biliary radical dilatation in the left lobe with a periportal hypoechoic lesion measuring 3.5 cm × 2.1 cm. Computed tomography (CT) scan of the abdomen [Figures 1 and 2] was done, and this showed distal pigtail at the porta and the stent crossing the left lobe by piercing the liver surface with proximal pigtail seen in subdiaphragmatic space. There was thrombosis in the branches of portal vein. Considering the CT scan findings and ruling out other cause of fever, it was decided to surgically remove the stent.

At laparotomy, omentum was seen adhered to the subdiaphragmatic surface of the left lobe of the liver. The pigtailed end of the plastic biliary stent was seen protruding into the subdiaphragmatic space from the surface of left lobe of liver [Figure 3]. Adhesiolysis was done to expose the liver surface, the protruded part of the stent was dissected free from the surface of the

Address for correspondence: Dr. Bhavik Bharat Shah, Institute of Gastrosciences and Liver, Apollo Gleneagles Hospital, Kolkata, West Bengal, India.
E-mail: shahbhavik24@gmail.com

This is an open access journal, and articles are distributed under the terms of the Creative Commons Attribution-NonCommercial-ShareAlike 4.0 License, which allows others to remix, tweak, and build upon the work non-commercially, as long as appropriate credit is given and the new creations are licensed under the identical terms.

For reprints contact: reprints@medknow.com

How to cite this article: Shah BB, Goenka U, Banerjee D, Rai V, Goenka MK. Migration of pigtail biliary stent through surface of the left lobe of liver. J Dig Endosc 2018;9:128-30.

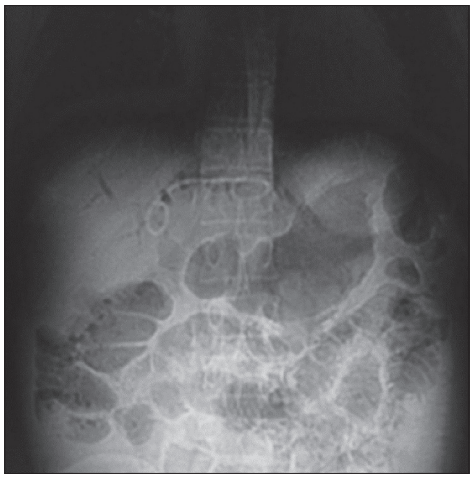

Figure 1: Computed tomography scan of the abdomen showing pigtail catheter

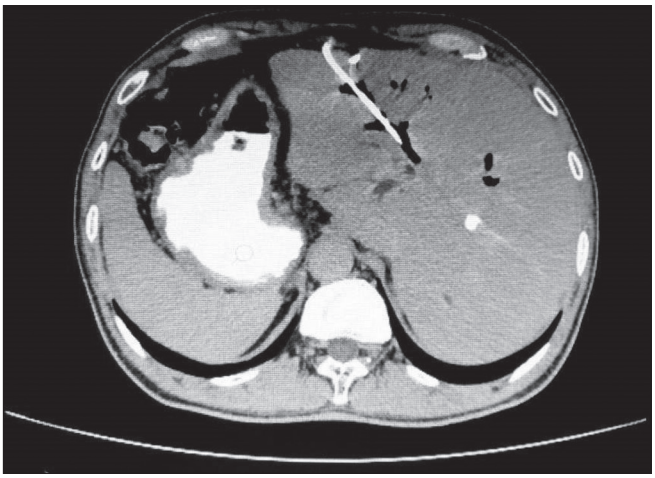

Figure 2: Computed tomography scan of the abdomen showing the stent (arrow) crossing the left lobe by piercing the liver surface with proximal pigtail seen in subdiaphragmatic space

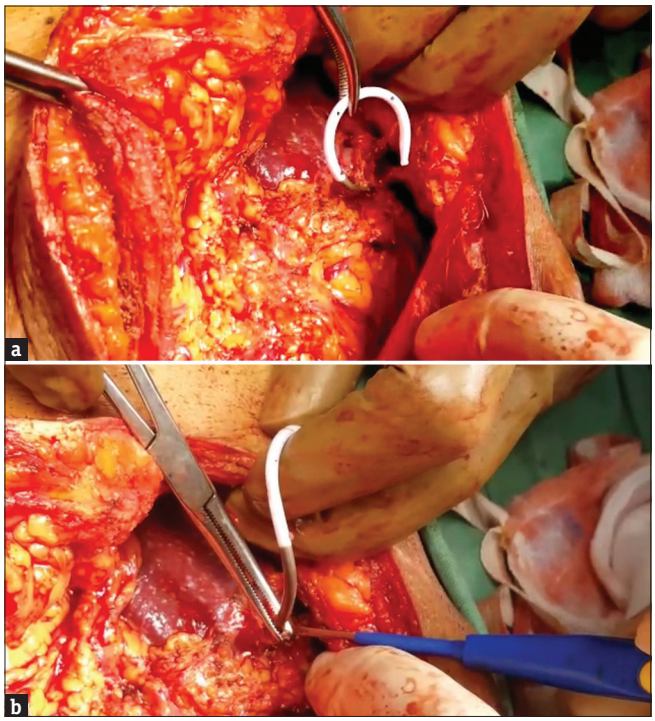

Figure 3: (a) Intraoperative pigtail end of the stent seen protruding into the subdiaphragmatic space from the surface of left lobe of the liver. (b) It is been pulled out

liver by doing hepatotomy, and the stent was pulled out gently. Hepatotomy was closed and omental patch was used to cover the area. Postoperatively, the patient was afebrile and stable. He was discharged without any complications and has been fine during a follow-up period of 3 months.

Discussion

Over the past decade, the biliary stenting has been increasingly used. Despite the overall safety, these stents may occasionally migrate from the biliary tract.[4] Arhan *et al*.[5] reported the rate of migration to be 8.58% (proximal 4.58% and distal 4.00%). The frequency of stent migration increases significantly with straight type stents when compared with pig-tailed stents and also with the longer duration of stenting.[6] Longer duration of stenting is associated with unusual complications. Over 80% of proximally migrated bile duct and pancreatic duct stents may be extracted endoscopically with only few patients requiring surgery.[7]

In the present case, the stent migrated proximally through the left intrahepatic duct, penetrating the surface of left lobe of liver into the subdiaphragmatic space. To the best of our knowledge, there is no such case reported in the literature. Moreover, this case had migration with pigtail stent, which because of its design are likely to migrate, less frequently. Surprisingly, the patient presented only with short duration of fever and no other symptom for 4 years. We did not attempt endoscopic removal of stent because of fear of trauma at liver surface due to suspicion of adhesions with surrounding structures. In fact, adhesions were demonstrated at the time of laparotomy. The presence of portal vein thrombosis could be possibly explained by continuous irritation of the stent, leading to inflammation and subsequent thrombosis. In summary, we present a rare case of proximally migrated biliary stent penetrating the liver surface which required surgery.

Declaration of patient consent

The authors certify that they have obtained all appropriate patient consent forms. In the form, the patient has given his consent for his images and other clinical information to be reported in the journal. The

patient understands that name and initials will not be published and due efforts will be made to conceal identity, but anonymity cannot be guaranteed.

Financial support and sponsorship

Apollo Gleneagles Hospital, Kolkata, India, supported the study.

Conflicts of interest

There are no conflicts of interest.

REFERENCES

1. Blake AM, Monga N, Dunn EM. Biliary stent causing colovaginal fistula: Case report. JSLS 2004;8:73-5.
2. Huibregtse K, Katon RM, Coene PP, Tytgat GN. Endoscopic palliative treatment in pancreatic cancer. Gastrointest Endosc 1986;32:334-8.
3. Huibregtse K. Endoscopic Biliary and Pancreatic Drainage. New York: Georg Thieme; 1988. p. 93-120.
4. Devière J, Devaere S, Baize M, Cremer M. Endoscopic biliary drainage in chronic pancreatitis. Gastrointest Endosc 1990;36:96-100.
5. Arhan M, Odemiş B, Parlak E, Ertuğrul I, Başar O. Migration of biliary plastic stents: Experience of a tertiary center. Surg Endosc 2009;23:769-75.
6. Kawaguchi Y, Ogawa M, Kawashima Y, Mizukami H, Maruno A, Ito H, *et al*. Risk factors for proximal migration of biliary tube stents. World J Gastroenterol 2014;20:1318-24.
7. Lahoti S, Catalano MF, Geenen JE, Schmalz MJ. Endoscopic retrieval of proximally migrated biliary and pancreatic stents: Experience of a large referral center. Gastrointest Endosc 1998;47:486-91.