

## Original Article

## How Frequent does Bow and Arrow Sign Locate Ileocecal Valve during Colonoscopy?

Adegboyega Akere, Edries Ahmad Tejan<sup>1</sup>

Department of Medicine,  
College of Medicine,  
University of Ibadan,  
University College Hospital,  
<sup>1</sup>Department of Medicine,  
University College Hospital,  
Ibadan, Nigeria

## ABSTRACT

**Aim:** Two major ways to locate the ileocecal valve (ICV) are to look for a thickening or bulge on the ileocecal fold, and the other is the “bow and arrow” method or the “appendix trick”. The aim of this study was to determine the accuracy of “bow and arrow” method to locate the ICV during colonoscopy.

**Patients and Methods:** Colonoscopy was performed with the patients in the left lateral position. After cecal intubation had been confirmed, the appendiceal opening was identified, with the curve serving as the bow, an imaginary arrow was placed across the curve toward the appendix lumen. The tip of the imaginary arrow was then followed to confirm if it correlated to the location of the ICV.

**Results:** The “bow and arrow” accurately located the ICV in 105 (76.6%) patients, but failed in 32 (23.4%) patients. The mean age ( $56.2 \pm 13.1$  years) of the patients in whom the “bow and arrow” located the ICV was lower than that ( $62.7 \pm 0.9$  years) of the patients in whom it failed to locate the ICV. Males, 58 (71.6%) had positive “bow and arrow”, while this was observed in 47 (83.9%) females. It correctly located the ICV in 73 (53.3%) of those with thin-lip ICV, 20 (14.6%) of those with volcanic type, and 12 (8.8%) of those with double bulge ICV. **Conclusion:** The bow and arrow sign could not locate the ICV in all cases in our practice and so where it failed, alternative method should be employed to locate the ICV.

**KEYWORDS:** Appendiceal orifice, bow and arrow, colonoscopy, ileocecal valve

## INTRODUCTION

The cecum and the anus are the two identifiable landmarks of the colon, which signify visualization of the entire colon.<sup>[1]</sup> In the cecum, the identifiable landmarks are the ileocecal valve (ICV) and the appendiceal orifice (AO).<sup>[1]</sup> The identification of the ICV during colonoscopy indicates complete visualization of the entire colon.<sup>[1]</sup>

There are two major ways to locate the ileocecal valve. One way is to look for a thickening or bulge on the ileocecal fold which is the first prominent circular haustral fold, about 5 cm distal to the cecal pole. This is achieved by pulling back about 8–10 cm from the cecal pole, so as to view that ileocecal fold.<sup>[1]</sup>

The other and the more commonly employed way of locating the ICV is the “bow and arrow” method, also

called the ‘appendix trick’. This method, in addition, allows easy intubation of the terminal ileum. In this method, the curve of the AO is the bow, while an imaginary arrow drawn in the direction of the appendix lumen tends to point to the ICV.<sup>[1]</sup> [Figure 1].

The aim of this study was to determine the accuracy of “bow and arrow” method to locate the ICV during colonoscopy.

## PATIENTS AND METHODS

All the patients had bowel preparation which consisted of 3 days of liquid diet and oral bisacodyl 30 mg daily, as well as oral normal saline 2 L 12 h apart a day before

**Address for correspondence:** Dr. Adegboyega Akere, Department of Medicine, College of Medicine, University of Ibadan, University College Hospital, PMB 5116, Ibadan, Nigeria. E-mail: adeakere@yahoo.co.uk

This is an open access article distributed under the terms of the Creative Commons Attribution-NonCommercial-ShareAlike 3.0 License, which allows others to remix, tweak, and build upon the work non-commercially, as long as the author is credited and the new creations are licensed under the identical terms.

**For reprints contact:** reprints@medknow.com

**How to cite this article:** Akere A, Tejan EA. How Frequent does Bow and Arrow Sign Locate Ileocecal Valve during Colonoscopy? J Dig Endosc 2018;9:10-3.

## Access this article online

## Quick Response Code:



**Website:** www.jdeonline.in

**DOI:** 10.4103/jde.JDE\_24\_17

the procedure, and 2 L early morning on the day of the procedure.

After taking informed consent, each patient received premedication which consisted of intravenous midazolam 2.5–5 mg and pentazocine 15–30 mg in titrated doses.

Colonoscopy was performed with the patients in the left lateral position using Olympus Exera III video colonoscope (CF 190 L). Cecal intubation was attempted in all the patients. After cecal intubation had been confirmed, the appendiceal opening was identified. Following this, the curve of the appendiceal opening served as the bow, while an imaginary arrow was placed across the curve toward the appendiceal opening. The tip of the imaginary arrow was then followed to confirm if it correlated to the location of the ICV [Figure 1]. If it did not, the ICV was then identified by the other method [Figure 2].

A questionnaire was used to collect demographic and other relevant information from each patient.

In this study, all the procedures were in accordance with the revised Helsinki Declaration (2013) and were approved by the State Research Ethical Review Committee.

## RESULTS

The data of 137 patients, comprising 81 (59.1%) males and 56 (40.9%) females, were analyzed, giving a male-to-female ratio of 1.4:1. The mean age of the patients was  $57.7 \pm 12.9$  years with a range of 12–87 years.

The most common indications for colonoscopy were hematochezia in 52 (38%), altered bowel habits in 33 (24.1%) and abdominal pain in 25 (18.2%) patients [Table 1].

Analysis of the types of ICV showed that, the most commonly observed type was thin-lip in 93 (67.9%) of our patients. Single bulge type was not observed in any of our patients [Figure 3].

The “bow and arrow” method accurately located the ICV in 105 (76.6%) patients but failed in 32 (23.4%) patients. Further analysis of the results showed that, the mean age ( $56.2 \pm 13.1$  years) of the patients in whom the “bow and arrow” located the ICV was lower than the mean age ( $62.7 \pm 0.9$  years) of the patients in whom it failed to locate the ICV. The difference in the means of the age of the two groups was statistically significant ( $P = 0.01$ ) Table 2.

With respect to gender, 58 (71.6%) of the males had “bow and arrow” accurately locating the ICV, while this was

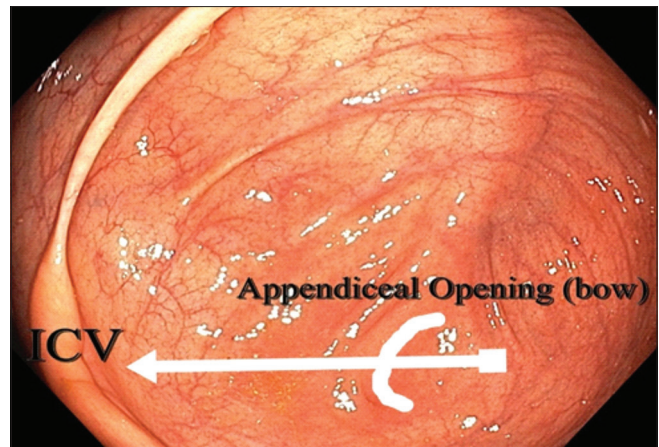


Figure 1: Bow and arrow sign accurately located the ileocecal valve

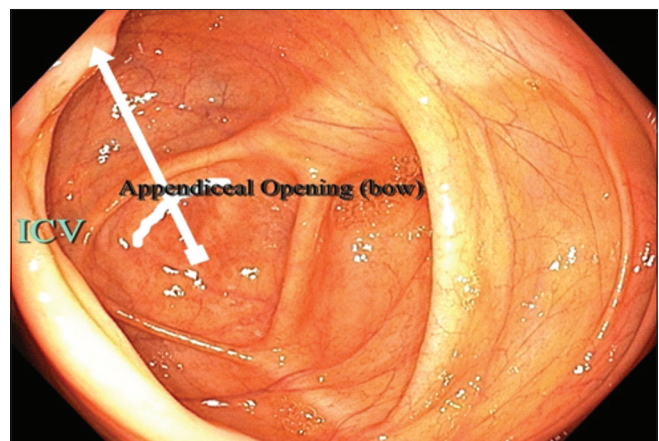


Figure 2: Bow and arrow sign failed to accurately locate the ileocecal valve

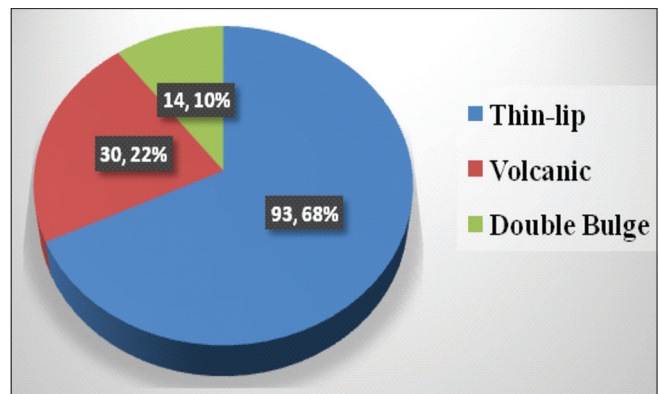


Figure 3: Types of ileocecal valve in the patients

observed in 47 (83.9%) females. However, the gender difference did not attain statistical significance ( $P = 0.07$ ) Table 2.

Analysis of the relationship between the types of ICV and the accuracy of “bow and arrow” showed that, this method correctly located the ICV in 73 (53.3%) of those with thin-lip ICV, 20 (14.6%)

**Table 1: Most important indications for colonoscopy in the patients**

Indication	Frequency (%)
Hematochezia	52 (38.0)
Altered bowel habits	33 (24.1)
Abdominal pain	25 (18.2)
Suspected colonic tumour	11 (8.0)
Screening	5 (3.6)
Anal protrusion	3 (2.2)

**Table 2: Univariate analysis of relationship between certain parameters and “bow and arrow” sign**

Parameter	Bow and arrow sign		P
	Yes (%)	No (%)	
Mean age (years)	56.2±13.1	62.7±10.9	0.01
Gender			
Male	58 (71.6)	23 (28.4)	0.07
Female	47 (83.9)	9 (16.1)	
Type of ICV			
Thin-lip	73 (53.3)	20 (14.6)	0.29
Volcanic	20 (14.6)	10 (7.3)	
Double bulge	12 (8.8)	2 (1.5)	

ICV=Ileocecal valve

of those with volcanic type, and 12 (8.8%) of those with double-bulge ICV. There was, however, no significance difference among the different types of ICV ( $P = 0.29$ ) [Table 2].

## DISCUSSION

This prospective study has demonstrated that the bow and arrow sign or appendix trick was only able to localize the ICV in 76.6% of cases. Although this sign has been described as an ingenious and usually successful method of both identifying the ICV, as well as intubating the terminal ileum,<sup>[2]</sup> it was not 100% accurate in this present study.

The finding of our study could be explained by the fact that, the bow and arrow sign works when the angulated appendix is lying bent toward the center of the abdomen, which is the same direction in which the ileum opens into the cecum. Hence, it could be argued that in those patients in whom the bow and arrow sign did not locate the ICV, the angulated appendix was probably lying away from the center of the abdomen.

It has been observed that the appendix is the most variable intra-abdominal organ with respect to its position, peritoneal, and organ relations.<sup>[3-6]</sup> These variations in the position of the appendix have been described most importantly in relation to variable symptoms and signs of appendicitis.<sup>[7-9]</sup> Its significance in relation to the position of the AO has not been described.

It has also been observed that the bow and arrow sign does not work in patients with previous appendectomy, mobile cecum, and a straight-on appendix.<sup>[2]</sup> Although in this study, history of appendectomy was not taken from the patients, the AO was identified in all of them during cecal intubation.

This study also revealed that the patients with positive bow and arrow were significantly younger than the other group. This could be explained by the fact that, the shape, position, structure, and size of the cecum and appendix have been found to vary in individuals with different age and sex.<sup>[3]</sup> This could also explain the predominance of males with positive bow and arrow compared to females, although this was not significant. The fact that more males were recruited into the study compared to females could also be the reason for the predominance of males with positive bow and arrow sign.

Another finding in this study was the predominance of positive bow and arrow sign in those with thin-lip ICV, although this was also not significant. The predominance of thin-lip ICV compared to other types among the patients could explain this observation.

The findings of our study could not be compared with other studies because we were unable to find any study on this particular subject.

## CONCLUSION

The bow and arrow sign could not locate the ICV in all cases in our practice and so where it failed, alternative method should be employed to locate the ICV. However, in all cases, the medial wall of the cecum must be visualized.

## Financial support and sponsorship

Nil.

## Conflicts of interest

There are no conflicts of interest.

## REFERENCES

1. Cotton PB, Williams CB. Practical Gastrointestinal Endoscopy. London: Blackwell Publishers; 1996. p. 116-60.
2. Williams CB. Insertion technique. In: Waye JD, Rex KD, Williams CB, editors. Colonoscopy: Principles and Practice. 2<sup>nd</sup> ed. USA: Wiley-Blackwell; 2009. p. 537-60.
3. Banerjee A, Kumar IA, Tapadar A, Pranay M. Morphological variations in the anatomy of caecum and appendix - A cadaveric study. Natl J Clin Anat 2012;1:30-5.
4. Delić J, Savković A, Isaković E. Variations in the position and point of origin of the vermiform appendix. Med Arh 2002;56:5-8.
5. Paul UK, Naushaba H, Alam MJ, Begum T, Rahman A, Akhter J. Length of vermiform appendix: A post-mortem study. Bangladesh J Anat 2011;9:10-2.
6. Ahmed I, Asgeirsson KS, Beckingham IJ, Lobo DN. The

- position of the vermiform appendix at laparoscopy. *Surg Radiol Anat* 2007;29:165-8.
7. Ahangar S, Zaz M, Shah M, Wani SN. Perforated subhepatic appendix presenting as gas under diaphragm. *Indian J Surg* 2010;72:273-4.
  8. Pittman-Waller VA, Myers JG, Stewart RM, Dent DL, Page CP, Gray GA, *et al.* Appendicitis: Why so complicated? Analysis of 5755 consecutive appendectomies. *Am Surg* 2000;66:548-54.
  9. Nayak SB, George BM, Mishra S, Surendran S, Shetty P, Shetty SD, *et al.* Sessile ileum, subhepatic cecum, and uncinat appendix that might lead to a diagnostic dilemma. *Anat Cell Biol* 2013;46:296-8.