

Review Article

Corrosive Injuries of the Upper Gastrointestinal Tract

Babu Lal Meena, Kumar Shwetanshu Narayan, Gopal Goyal, Surendar Sultania, Sandeep Nijhawan

Department of
Gastroenterology,
Sawai Man Singh Medical
College and Hospital, Jaipur,
Rajasthan, India

ABSTRACT

Corrosive injury of the upper gastrointestinal tract is a worldwide clinical problem, mostly occurring in children. Alkaline agents produce deeper injuries whereas acidic agents produce superficial injuries usually. Hoarseness, stridor, and respiratory distress indicate airway injury. Dysphagia, odynophagia, and drooling of saliva suggest esophageal injury whereas abdominal pain, nausea, and vomiting are indicative of stomach injury. X-rays should be done to rule out perforation. Endoscopy is usually recommended in the first 12–48 h although it is safe up to 96 h after caustic ingestion. Endoscopy should be performed with caution and gentle insufflation. Initial management includes getting intravenous access and replacement of fluids. Hyperemia and superficial ulcerations have excellent recovery while deeper injuries require total parenteral nutrition or feeding jejunostomy. Patients suspected of perforation should be subjected to laparotomy. Common complications after corrosive injury are esophageal stricture, gastric outlet obstruction, and development of esophageal and gastric carcinoma.

KEYWORDS: Corrosive injury, esophageal perforation, esophageal stricture, upper gastrointestinal tract

EPIDEMIOLOGY

Corrosive injury of the upper gastrointestinal tract is a worldwide clinical problem. Eighty percent of the corrosive injuries occur in children, where it is due to accidental ingestion of the caustic agents.^[1] Adults usually ingest caustic agent with a suicidal intent.^[2] Occasionally, ingestion of caustic agent is seen in psychiatric or alcoholic patients.^[3] In western countries, alkaline agent injuries are more common, whereas acid injury is more common in developing countries due to easy accessibility of agents.^[4]

PATHOPHYSIOLOGY

Various types of alkali agents are available commercially, such as cleaning agent (NaOH), drain opener (sodium hydroxide), bleaches (hydrogen oxide and sodium hypochlorite), and detergent (sodium tripolyphosphates).^[1] The alkalis have a pH of >7, these agents are tasteless and odorless, and therefore, larger amount are ingested. Alkalis lead to liquefactive necrosis leading to deeper injuries. The alkaline agents are also available in solid forms (NaOH) which limits the

quantity ingested, so more oropharyngeal and supraglottic injuries occur. The liquid alkaline agents are ingested in larger amount leading to extensive and circumferential esophageal burn.^[5] Commercially available acids are toilet bowl cleaners (sulfuric acid and hydrochloric acid), antirust compounds (hydrochloric acid, oxalic acid, and hydrofluoric acid), battery fluid (sulfuric acid), and swimming pool cleaner (hydrochloric acid). The acids have a pH of <7 and they have a pungent odor and a noxious taste, which limit the amount ingested. Acids cause coagulation necrosis, which limits the depth of injury. Further acids cause less esophageal injuries with respect to gastric injuries.^[6]

Although alkali ingestion leads to liquefactive necrosis and acid ingestion leads to coagulative necrosis, concentrated acid or alkali ingestion can lead to similar pathological changes. Esophageal injury begins within minutes of caustic ingestion, initial tissue injury is marked

Address for correspondence: Dr. Sandeep Nijhawan,
Department of Gastroenterology, Sawai Man Singh Medical
College and Hospital, Jaipur, Rajasthan, India.
E-mail: dr_nijhawan@yahoo.com

This is an open access article distributed under the terms of the Creative Commons Attribution-NonCommercial-ShareAlike 3.0 License, which allows others to remix, tweak, and build upon the work non-commercially, as long as the author is credited and the new creations are licensed under the identical terms.

For reprints contact: reprints@medknow.com

How to cite this article: Meena BL, Narayan KS, Goyal G, Sultania S, Nijhawan S. Corrosive injuries of the upper gastrointestinal tract. J Dig Endosc 2017;8:165-9.

Access this article online

Quick Response Code:



Website: www.jdeonline.in

DOI: 10.4103/jde.JDE_24_16

by necrosis, within the 2nd day, thrombosis of small vessels occurs, on the 4th–7th-day mucosal sloughing, and bacterial invasion and fibroblastic migration are main findings. After the 2nd week, collagen deposition occurs, and by the 3rd-week, scar retraction starts which leads to stricture formation (occurs within weeks to years).^[6,7] Carcinoma formation occurs after decades of exposure.^[1]

SYMPTOMS AND SIGNS

Acute corrosive injuries lead to severe pain of the lips, mouth, and throat. Hoarseness, stridor, and respiratory distress indicate airway injury. Dysphagia, odynophagia, and drooling suggest esophageal injury. Abdominal pain, nausea, and vomiting are indicative of stomach injury. Varying degree of hematemesis occurs due to mucosal injury, but massive hematemesis is generally due to aorto-esophageal fistula. Severe retrosternal and upper back pain suggests esophageal perforation.^[8,9] Severe abdominal pain with guarding and rigidity of the abdomen with rebound tenderness denotes gastric perforation.^[10-12] The early signs and symptoms may not correlate with severity of tissue injury.^[8]

INVESTIGATIONS

Leukocytosis and raised C-reactive protein indicates a severe acute inflammatory response to caustic injury. Arterial blood gas analysis alteration occurs with airway involvement. Severe electrolyte imbalance seen is due to large amount of fluid loss in the third space. Coagulation profile is important in bleeding patients. Altered renal and liver functions occur in response to hypotension and systemic infection.^[13,14]

Good chest X-ray helps in detection of pneumothorax, pneumomediastinum, and pleural effusion. X-ray abdomen erect and lateral view is helpful in diagnosing intraperitoneal air. If perforation is suspected on clinical ground, water-soluble contrast such as hypaque or gastrografin is to be used to confirm perforation. If there is a high risk of suspicion for perforation and the X-rays are negative, computed tomography (CT) scan of the neck, chest, or abdomen with oral contrast should be considered. On contrast-enhanced CT (CECT) scan of the thorax, grade 1 shows normal esophageal wall, grade 2 has edematous wall, in grade 3, periesophageal soft-tissue infiltration is added to grade 2 with well-demarcated tissue interface, and grade 4 has grade 3 changes along with blurring of tissue interface.^[15] Miniprobe endoscopic ultrasound (EUS) can be used safely. When compared with conventional endoscopy, there was no difference in predicting the development of early complications.^[16] However, a study indicated that strictures were not formed if the muscle layer was seen

intact in EUS.^[17] Radial EUS is indicated if the proper muscle layer is included, treatment response to balloon dilatation decreases, or subsequent repeated procedures are required.

Endoscopy is contraindicated in hemodynamically unstable patients with necrosis around the lip and oral cavity, severe laryngopharyngeal edema, severe respiratory distress, and suspected perforation. Endoscopy is usually recommended in the first 12–48 h although it is safe up to 96 h after caustic ingestion. Endoscopy should be performed with caution and gentle insufflation. Zargar's modified endoscopic classification of corrosive ingestion is useful in grading endoscopic lesions; grade 0 is normal, grade 1 has mucosal edema and hyperemia, grade 2A shows superficial ulcers, grade 2B has deep focal and circumferential ulcers, grade 3A shows focal necrosis, grade 3B has extensive necrosis, and grade 4 shows perforation^[18] [Figure 1].

TREATMENT

Initial management includes getting intravenous access and replacement of fluids. After stabilization, patients should be monitored for identifying acute complications and risk for development of long-term complications. Patients with stridor and respiratory distress require admission in the intensive care unit. Persistent respiratory distress mandates urgent endotracheal intubation. In patients with severe supraglottic edema, urgent cricothyrotomy or tracheostomy should be performed. Patients with clinical and imaging evidence of perforation require immediate laparotomy followed by esophagectomy, cervical esophagostomy, concomitant gastrectomy, and feeding jejunostomy.^[19-22] Patients with injuries up to grade 2A have excellent prognosis and can be discharged after 24–48 h of observation. Patients with grade 2B and 3A injury develop strictures in 70%–100% cases. All patients with grade 2B and 3A injuries can be managed conservatively; they require nutritional support for 6–8 weeks by total parenteral nutrition or feeding jejunostomy [Table 1].

The strictures usually develop within 8 weeks in 80% of patients but can develop as early as after 3 weeks or as late as 1 year after caustic ingestion. Patients with grade 3B and 4 have high early mortality rate up to 65%.^[16,23,24] Patients with grade 4 injury should be subjected to surgery. Corticosteroids and nasogastric tube insertion are not recommended for stricture prevention.^[25-27] However, nasogastric tube can be placed endoscopically and has theoretical advantage of providing patent route for enteral feeding, maintain luminal integrity, and decrease stricture formation.^[28,29] Antibiotics do not affect scar formation.^[30] They are only

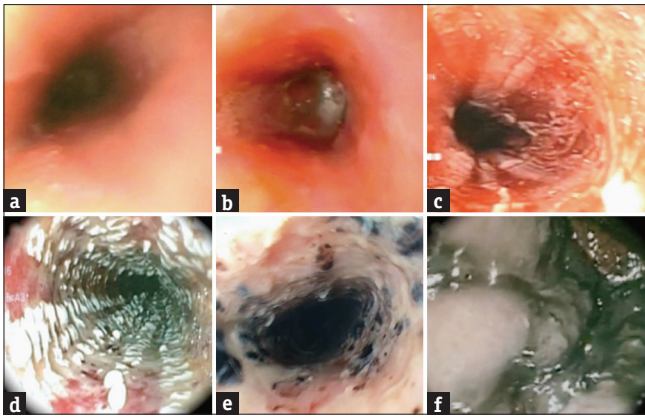


Figure 1: Endoscopic pictures of Zargar’s classification 0 to IIIIB. (a) Zargar Grade 0: Normal mucosa; (b) Zargar Grade I: Edema and erythema of the mucosa; (c) Zargar Grade II: Hemorrhage, erosions, blisters, and superficial ulcers; (d) Zargar Grade IIB: Circumferential bleeding ulcers. Exudates; (e) Zargar Grade III: Focal necrosis, deep gray, or brownish black ulcers; (f) Zargar Grade IIIIB: Extensive necrosis, deep gray, or brownish black ulcers

indicated if there is evidence of infection or as an adjunct to the steroid therapy. Endoscopic topical application of mitomycin-C can decrease the number of dilatations and cause relief of dysphagia.^[31,32] Intraperitoneal 5-fluorouracil, antioxidants, and phosphatidylcholine inhibitor have been tried without success in preventing stricture formation.^[32-34] Intraluminal stents of silicone rubber and polytetrafluoroethylene are positioned by endoscopy or through laparotomy for 4–6 months; they have been found to be efficacious in 52%–72% but have a high migration rate (25%) and require high endoscopy skills for placement.^[35,36]

All patients after 3–4 weeks of conservative treatment for grade 2B injury and above are subjected to barium studies for the esophagus and stomach to evaluate the length, number, degree of esophageal stricture length, shape of gastric outlet stricture, and evaluation of gastric body and fundus [Table 2]

LATE COMPLICATIONS

Esophageal injuries

All patients with esophageal stricture present with dysphagia. The diagnosis is based on barium swallow study; wire-guided endoscopic dilatation with bougies is the first-line treatment.^[37] The dilatation should be started after 4 weeks of caustic injury. Initial dilatation of all strictures is performed under fluoroscopy guidance. Dilatation is performed at 1-week interval; however, tight stricture requires twice weekly dilatation in the early period. The response to dilatation depends on tightness and length of stricture. Recurrence of dysphagia is high in the first 6 months after dilatation and then gradually decrease with time. Esophageal wall thickness on CECT

Table 1: Algorithm of acute and subacute corrosive injury management

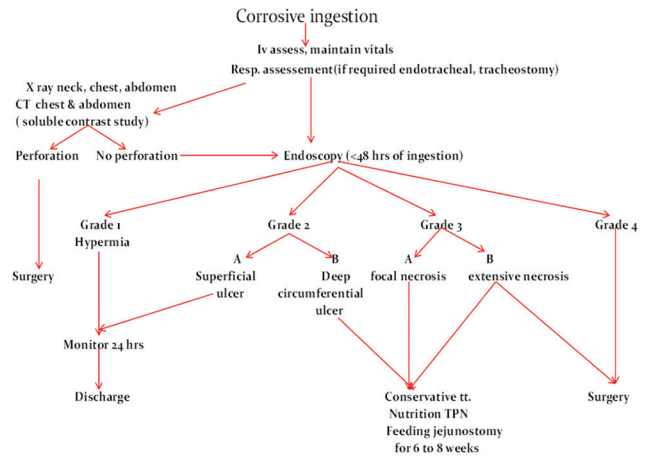
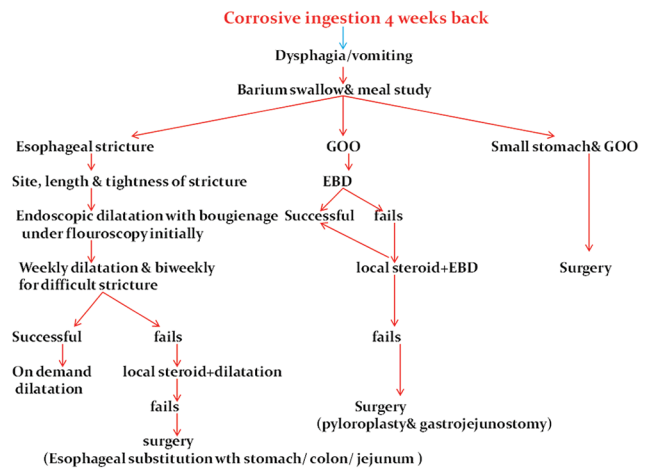


Table 2: Algorithm of chronic corrosive injury management



EBD=Endoscopic balloon dilatation, GOO=Gastric outlet obstruction

chest is the most sensitive predictor of response to dilatation. Intralesional steroid injection inhibits collagen synthesis and fibrosis.^[25,37] A combination of intralesional steroid and dilatation decreases the number of dilatation sessions, but a randomized study did not show its usefulness.^[36,38]

Reconstructive surgery is the last option when the dilatations fail, and some complication such as perforation has occurred after dilatation. Gastric and colon reconstruction are the two most commonly done surgical procedures; however, the choice of procedure is based on anatomic conditions of patient and the surgeon’s experience.^[39]

Newer modalities such as biodegradable stents and fully covered self-expandable metal stents are emerging alternatives for resistant strictures.^[33,34,40]

Esophageal carcinoma

The incidence of esophageal carcinoma is 1000–3000 folds higher after chronic caustic injury as compared to general population. The average time between corrosive injury and development of carcinoma is 40 years. The local and distant spread is unusual due to lack of blood supply in fibrotic area and fibrosis around the esophagus.

Gastric injuries

Severe caustic injury of the stomach causes gastric cicatrization which presents as intractable pain, late-onset achlorhydria, gastric outlet obstruction, mucosal metaplasia, and development of gastric carcinoma.

Gastric outlet obstruction is less common than esophageal stricture; it represents 5% of the overall corrosive injuries. Patients present with early satiety, abdominal distention, recurrent vomiting, and weight loss. Symptomatic patients need hospitalization with fluid replacement and correction of electrolytes. These patients respond to balloon dilatation to different diameters with controlled radial expansion balloon, the size of balloon depends on endoscopist's perception. Patients are monitored for 4–6 h after the procedure for perforation and bleeding. If the perforation is suspected, a contrast study with soluble contrast should be performed. The balloon dilatation is repeated every 1–2 weeks till adequate dilatation is achieved. Addition of balloon dilatation with various procedures such as intralesional steroid,^[41,42] electrosurgical incision with sphincterotome, or needle knife^[43,44] has been reported to have some benefit. Surgery is the final option for patients presenting with refractory gastric outlet obstruction; these patients respond to pyloroplasty or bypass procedure such as gastrojejunostomy.

Majority of esophageal strictures can be managed by endoscopic interventional methods; surgery is the only modality of treatment for gastric complications. Corrosive injuries continue to result in high morbidity and mortality.^[45]

CONCLUSION

Corrosive injury of the upper gastrointestinal tract is a common problem with variable clinical presentations. Acid injury is more common in developing countries like India. The depth of injury is the most important determinant of the outcome. Early endoscopy is helpful in assessing the extent of injury to plan future management of the patient. Nutritional support is given by total parenteral nutrition and feeding jejunostomy in subacute stage in grade 2B and 3A injuries. Intraluminal stents may be effective in the prevention of stricture but require endoscopic experience and are costly. Nasogastric

tube and antibiotics have no role in preventing stricture. Role of steroid remains still uncertain in the prevention of strictures. Endoscopic dilatation is the treatment of choice for esophageal stricture and gastric outlet obstruction. Surgery remains the last option for endoscopic failure and for patients who develop complications on endoscopic dilatation.

Financial support and sponsorship

Nil.

Conflicts of interest

There are no conflicts of interest.

REFERENCES

- Gumaste VV, Dave PB. Ingestion of corrosive substances by adults. *Am J Gastroenterol* 1992;87:1-5.
- Yeom HJ, Shim KN, Kim SE, Lee CB, Lee JS, Cho YK, *et al.* Clinical characteristics and predisposing factors for complication of caustic injury of the upper digestive tract. *Korean J Med* 2006;70: 371-7.
- Yoon KW, Park MH, Park GS, Jung PJ, Joo YE, Kim HS, *et al.* A clinical study on the upper gastrointestinal tract injury caused by corrosive agent. *Korean J Gastrointest Endosc* 2001;23:82-7.
- Zargar SA, Kochhar R, Nagi B, Mehta S, Mehta SK. Ingestion of corrosive acids. Spectrum of injury to upper gastrointestinal tract and natural history. *Gastroenterology* 1989;97:702-7.
- Contini S, Scarpignato C. Caustic injury of the upper gastrointestinal tract: A comprehensive review. *World J Gastroenterol* 2013;19:3918-30.
- Havanond C. Is there a difference between the management of grade 2b and 3 corrosive gastric injuries? *J Med Assoc Thai* 2002;85:340-4.
- Osman M, Russell J, Shukla D, Moghadamfalahi M, Granger DN. Responses of the murine esophageal microcirculation to acute exposure to alkali, acid, or hypochlorite. *J Pediatr Surg* 2008;43:1672-8.
- Browne J, Thompson J. Caustic ingestion. In: Bluestone CD, Stool SE, Kenna MA, editors. *Pediatric Otolaryngology*. 4th ed. Philadelphia, PA: W.B. Saunders Co.; 2003. p. 4330-42.
- Espinola TE, Amedee RG. Caustic ingestion and esophageal injury. *J La State Med Soc* 1993;145:121-5.
- Gaudreault P, Parent M, McGuigan MA, Chicoine L, Lovejoy FH Jr. Predictability of esophageal injury from signs and symptoms: A study of caustic ingestion in 378 children. *Pediatrics* 1983;71:767-70.
- Salzman M, O'Malley RN. Updates on the evaluation and management of caustic exposures. *Emerg Med Clin North Am* 2007;25:459-76.
- Hoffman RS, Howland MA, Kamerow HN, Goldfrank LR. Comparison of titratable acid/alkaline reserve and pH in potentially caustic household products. *J Toxicol Clin Toxicol* 1989;27:241-6.
- Rigo GP, Camellini L, Azzolini F, Guazzetti S, Bedogni G, Merighi A, *et al.* What is the utility of selected clinical and endoscopic parameters in predicting the risk of death after caustic ingestion? *Endoscopy* 2002;34:304-10.
- Cheng YJ, Kao EL. Arterial blood gas analysis in acute caustic ingestion injuries. *Surg Today* 2003;33:483-5.
- Ryu HH, Jeung KW, Lee BK, Uhm JH, Park YH, Shin MH, *et al.* Caustic injury: Can CT grading system enable prediction

- of esophageal stricture? *Clin Toxicol (Phila)* 2010;48:137-42.
16. Chiu HM, Lin JT, Huang SP, Chen CH, Yang CS, Wang HP, *et al.* Prediction of bleeding and stricture formation after corrosive ingestion by EUS concurrent with upper endoscopy. *Gastrointest Endosc* 2004;60:827-33.
 17. Kamijo Y, Kondo I, Kokuto M, Kataoka Y, Soma K. Miniprobe ultrasonography for determining prognosis in corrosive esophagitis. *Am J Gastroenterol* 2004;99:851-4.
 18. Zargar SA, Kochhar R, Mehta S, Mehta SK. The role of fiberoptic endoscopy in the management of corrosive ingestion and modified endoscopic classification of burns. *Gastrointest Endosc* 1991;37:165-9.
 19. Andreoni B, Farina ML, Biffi R, Crosta C. Esophageal perforation and caustic injury: Emergency management of caustic ingestion. *Dis Esophagus* 1997;10:95-100.
 20. Cattan P, Munoz-Bongrand N, Berney T, Halimi B, Sarfati E, Celerier M, *et al.* Extensive abdominal surgery after caustic ingestion. *Ann Surg* 2000;231:519-23.
 21. Wu MH, Lai WW. Surgical management of extensive corrosive injuries of the alimentary tract. *Surg Gynecol Obstet* 1993;177:12-6.
 22. Baskin D, Urganci N, Abbasoğlu L, Alkim C, Yalçın M, Karadağ C, *et al.* A standardised protocol for the acute management of corrosive ingestion in children. *Pediatr Surg Int* 2004;20:824-8.
 23. Kay M, Wyllie R. Caustic ingestions in children. *Curr Opin Pediatr* 2009;21:651-4.
 24. Fulton JA, Hoffman RS. Steroids in second degree caustic burns of the esophagus: A systematic pooled analysis of fifty years of human data: 1956-2006. *Clin Toxicol (Phila)* 2007;45:402-8.
 25. Pelclová D, Navrátil T. Do corticosteroids prevent oesophageal stricture after corrosive ingestion? *Toxicol Rev* 2005;24:125-9.
 26. Ramasamy K, Gumaste VV. Corrosive ingestion in adults. *J Clin Gastroenterol* 2003;37:119-24.
 27. Krey H. On the treatment of corrosive lesions in the oesophagus; an experimental study. *Acta Otolaryngol Suppl* 1952;102:1-49.
 28. Rathnaswami A, Ashwin R. Corrosive Injury of the upper gastrointestinal tract: A review. *Arch Clin Gastroenterol* 2016;2:56-62.
 29. Kluger Y, Ishay OB, Sartelli M, Katz A, Ansaloni L, Gomez CA, *et al.* Caustic ingestion management: World society of emergency surgery preliminary survey of expert opinion. *World J Emerg Surg* 2015;10:48.
 30. Demirbilek S, Aydin G, Yücesan S, Vural H, Bitiren M. Polyunsaturated phosphatidylcholine lowers collagen deposition in a rat model of corrosive esophageal burn. *Eur J Pediatr Surg* 2002;12:8-12.
 31. Günel E, Çağlayan F, Çağlayan O, Canbilen A, Tosun M. Effect of antioxidant therapy on collagen synthesis in corrosive esophageal burns. *Pediatr Surg Int* 2002;18:24-7.
 32. De Peppo F, Zaccara A, Dall'Oglio L, Federici di Abriola G, Ponticelli A, Marchetti P, *et al.* Stenting for caustic strictures: Esophageal replacement replaced. *J Pediatr Surg* 1998;33:54-7.
 33. Atabek C, Surer I, Demirbag S, Caliskan B, Ozturk H, Cetinkursun S, *et al.* Increasing tendency in caustic esophageal burns and long-term polytetrafluoroethylene stenting in severe cases: 10 years experience. *J Pediatr Surg* 2007;42:636-40.
 34. Ashcraft KW, Holder TM. The experimental treatment of esophageal strictures by intralesional steroid injections. *J Thorac Cardiovasc Surg* 1969;58:685-91.
 35. Lee M, Kubik CM, Polhamus CD, Brady CE 3rd, Kadakia SC. Preliminary experience with endoscopic intralesional steroid injection therapy for refractory upper gastrointestinal strictures. *Gastrointest Endosc* 1995;41:598-601.
 36. Kochhar R, Sriram PV, Ray JD, Kumar S, Nagi B, Singh K, *et al.* Intralesional steroid injections for corrosive induced pyloric stenosis. *Endoscopy* 1998;30:734-6.
 37. Katz A, Kluger Y. Caustic material ingestion injuries-paradigm shift in diagnosis and treatment. *Health Care Curr Rev* 2015;3:1-4.
 38. Gupta V, Wig JD, Kochhar R, Sinha SK, Nagi B, Doley RP, *et al.* Surgical management of gastric cicatrization resulting from corrosive ingestion. *Int J Surg* 2009;7:257-61.
 39. Abdelkader B. Esophageal Replacement for Caustic Stricture-A Brief Review. *Adv Res Gastroentero Hepatol* 2017;3:555623. DOI: 10.19080/ARGH.2017.03.555623.
 40. Ham YH, Kim GH. Plastic and biodegradable stents for complex and refractory benign esophageal strictures. *Clin Endosc* 2014;47:295-300.
 41. Zhang C, Yu JM, Fan GP, Shi CR, Yu SY, Wang HP, *et al.* The use of a retrievable self-expanding stent in treating childhood benign esophageal strictures. *J Pediatr Surg* 2005;40:501-4.
 42. Vandenplas Y, Hauser B, Devreker T, Urbain D, Reynaert H. A degradable esophageal stent in the treatment of a corrosive esophageal stenosis in a child. *Endoscopy* 2009;41 Suppl 2:E73.
 43. Boron B, Gross KR. Successful dilatation of pyloric stricture resistant to balloon dilatation with electrocautery using a sphinctertome. *J Clin Gastroenterol* 1996;23:239-41.
 44. Hagiwara A, Sonoyama Y, Togawa T, Yamasaki J, Sakakura C, Yamagishi H, *et al.* Combined use of electrosurgical incisions and balloon dilatation for the treatment of refractory postoperative pyloric stenosis. *Gastrointest Endosc* 2001;53:504-8.
 45. Lingala R, Kota R. Study of corrosive poisoning and its effects on upper gastrointestinal tract and surgical management – A single institution experience. *J Evid Based Med Healthc* 2017;4:2691-5.