

Case Report

Case of Cytomegalovirus Colitis in a Patient with Type 2 Diabetes Mellitus

Ankur Gupta, Priyanka Jain¹

Departments of
Gastroenterology and
¹Pathology, Max Hospital,
Dehradun, Uttarakhand, India

ABSTRACT Cytomegalovirus (CMV) colitis usually affects immunocompromised hosts. We report a patient with type 2 diabetes mellitus who presented with massive lower gastrointestinal bleed due to CMV colitis, which proved to be fatal. Awareness about this life-threatening entity is important in patients who have impaired immune response.

KEYWORDS: *Cytomegalovirus, gastrointestinal bleed, immunity*

INTRODUCTION

Cytomegalovirus (CMV), a common herpes virus is a chronic stressor for the immune system which establishes persistent, lifelong infections, and can get reactivated periodically.^[1] Early CMV infection, in the immunocompetent patient is mild and remains undetected clinically.^[2] We report a patient with type 2 diabetes mellitus who developed CMV colitis presenting as massive lower gastrointestinal bleed, which proved to be fatal. Awareness about this life-threatening entity is important in patients who have impaired immune response.

CASE REPORT

A 50-year-old male was admitted with shock due to hematochezia for 4 days. He denied having fever, painful defecation, abdominal pain, vomiting, hematemesis, pus, or mucus per rectum. He was detected having diabetes 10 years ago; diabetes was poorly controlled and was complicated by nephropathy. 2 months before presentation he developed quadriplegia after a cerebral ischemic event, following which he was bedridden. There was no history of gastrointestinal bleed.

Investigations at admission revealed hemoglobin of 7.1 g/dl (normal: 13.5–17), serum creatinine 2.4 mg/dl (normal: 0.8–1.4), and serum albumin of 1.6 g/dl (normal: 3.5–5.4). Bleeding had settled at presentation. He was resuscitated with blood transfusions and intravenous fluids. Colonoscopy showed diffuse erythema with loss of vascular pattern

in rectum, sigmoid, and distal descending colon, with rest of the large bowel and terminal ileum being normal [Figure 1]. Rectum also had a confluent ulcer approximately 1.5 cm in diameter [Figure 2]. Quantitative CMV DNA polymerase chain reaction (PCR) of biopsy from the ulcer base had 128,013 copies of CMV per ml. Tissue histology did not show inclusion bodies, it showed preserved crypt architecture and acute inflammatory infiltrate in lamina propria. Human immunodeficiency virus enzyme-linked immunosorbent assay was negative, and he did not receive any immune-modulatory drugs in the past. A computed tomography angiography was not done in view of high risk of renal failure and colonoscopic findings. Colectomy was advised but declined by the relatives in view of comorbidities and high-risk surgery.

He was treated with ganciclovir. He had another episode of massive lower gastrointestinal bleeding after which his condition worsened. He developed shock and oliguria following which he died.

DISCUSSION

CMV colitis has been usually described in immunocompromised hosts.^[3] CMV colitis in immunocompetent patients is a rare disease and is not commonly considered in differential

Address for correspondence: Dr. Ankur Gupta,

Department of Gastroenterology, Max Hospital, Mussoorie
Diversion Road, Malsi, Dehradun - 248 001, Uttarakhand, India.
E-mail: dr.ankurgupta@yahoo.com

Access this article online

Quick Response Code:



Website: www.jdeonline.in

DOI: 10.4103/jde.JDE_17_17

This is an open access article distributed under the terms of the Creative Commons Attribution-NonCommercial-ShareAlike 3.0 License, which allows others to remix, tweak, and build upon the work non-commercially, as long as the author is credited and the new creations are licensed under the identical terms.

For reprints contact: reprints@medknow.com

How to cite this article: Gupta A, Jain P. Case of cytomegalovirus colitis in a patient with Type 2 diabetes mellitus. *J Dig Endosc* 2017;8:193-5.

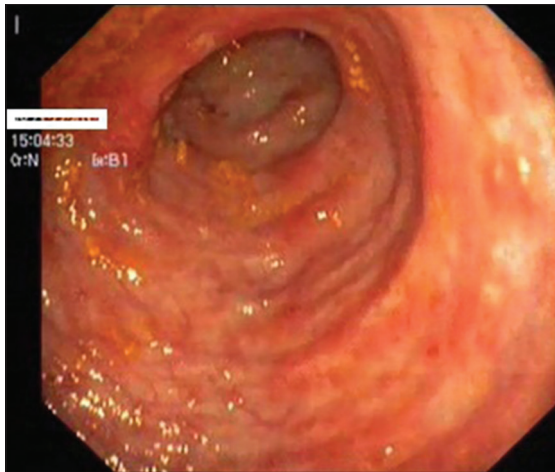


Figure 1: Diffuse erythema with loss of vascular pattern in sigmoid colon

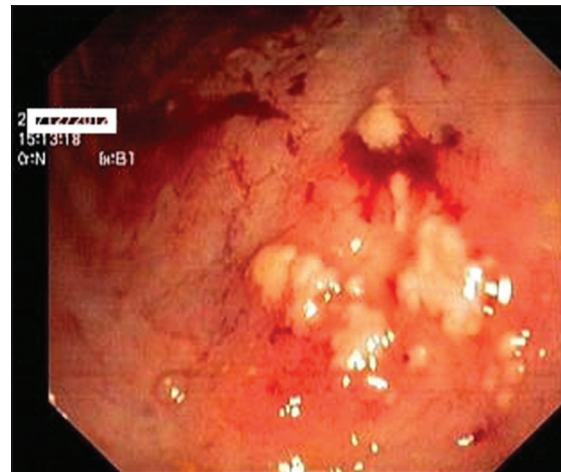


Figure 2: Confluent rectal ulcer

diagnosis in patients who are not overtly immunocompromised.^[4] However, it should be looked for in patients with bloody diarrhea, even in immunocompetent patients in whom other causes are ruled out.^[5]

CMV can cause severe toxicity in immunocompetent patients sporadically. A meta-analysis found only 44 immunocompetent patients with CMV colitis over a period of 23 years, 14 (31.8%) of these patients died.^[6] In yet another study, immunocompetent patients with CMV colitis were critically ill, had higher mortality rate and need prolonged stay in the ICU.^[7] Any part of the gastrointestinal tract, from mouth to anus can be infected by CMV, colon is the most commonly affected while the small bowel is rarely affected.^[8]

Although rare in immunocompetent individuals, CMV colitis should be suspected in individuals with first episode of symptoms of colitis including abdominal pain, fever, diarrhea, or lower gastrointestinal bleeding, during such an episode, presence of a condition causing immune deficiency should be looked for and likelihood of an alternative diagnosis, such as first presentation of inflammatory bowel disease must be excluded.^[9] Diagnosis of CMV colitis is made with serologic and histologic findings. Serologic finding includes positive IgM titer for CMV, CMV antigen in the blood and positive PCR in blood or tissues. Histologic finding consists of intranuclear inclusion bodies, which are pathognomic for CMV disease. In a study, PCR from colonic biopsy was found to be most sensitive (80%) method to diagnose CMV infection followed by IgM antibody (60%). The presence of inclusion bodies was least sensitive (10%).^[10]

Our patient had diabetes and renal dysfunction, both of which are considered to modify immune response and

predispose to infections which are otherwise uncommon. In the absence of inclusion bodies, a postmortem would have been useful to confirm the diagnosis; however, it was not done in our patient.

We conclude that CMV colitis is an uncommon cause of lower gastrointestinal bleed. Awareness about this potentially fatal entity is important while treating patients who have impaired immune response.

Financial support and sponsorship

Nil.

Conflicts of interest

There are no conflicts of interest.

REFERENCES

1. Donath MY, Shoelson SE. Type 2 diabetes as an inflammatory disease. *Nat Rev Immunol* 2011;11:98-107.
2. Zhang LJ, Hanff P, Rutherford C, Churchill WH, Crumpacker CS. Detection of human Cytomegalovirus DNA, RNA, and antibody in normal donor blood. *J Infect Dis* 1995;171:1002-6.
3. Nakase H, Herfarth H. Cytomegalovirus colitis, Cytomegalovirus hepatitis and systemic Cytomegalovirus infection: Common features and differences. *Inflamm Intest Dis* 2016;1:15-23.
4. Rafailidis PI, Mourtoukou EG, Varbobitis IC, Falagas ME. Severe Cytomegalovirus infection in apparently immunocompetent patients: A systematic review. *Virology* 2008;5:47.
5. Ng FH, Chau TN, Cheung TC, Kng C, Wong SY, Ng WF, *et al.* Cytomegalovirus colitis in individuals without apparent cause of immunodeficiency. *Dig Dis Sci* 1999;44:945-52.
6. Galiatsatos P, Shrier I, Lamoureux E, Szilagyi A. Meta-analysis of outcome of Cytomegalovirus colitis in immunocompetent hosts. *Dig Dis Sci* 2005;50:609-16.
7. Heininger A, Jahn G, Engel C, Notheisen T, Unertl K, Hamprecht K. Human Cytomegalovirus infections in nonimmunosuppressed critically ill patients. *Crit Care Med* 2001;29:541-7.
8. Nasa M, Sharma Z, Sud R, Lipi L. Cytomegalovirus

- infection of gastrointestinal tract. *Community Acquir Infect* 2016;3:4-9.
9. Goodman AL, Murray CD, Watkins J, Griffiths PD, Webster DP. CMV in the gut: A critical review of CMV detection in the immunocompetent host with colitis. *Eur J Clin Microbiol Infect Dis* 2015;34:13-8.
10. Kishore J, Ghoshal U, Ghoshal UC, Krishnani N, Kumar S, Singh M, *et al.* Infection with Cytomegalovirus in patients with inflammatory bowel disease: Prevalence, clinical significance and outcome. *J Med Microbiol* 2004;53(Pt 11):1155-60.