

Wilm's tumor presenting with scrotal varicocele in an 11-month-old boy

Bukunmi M Idowu, Adebayo G Tanimola¹

Departments of Radiology, Surgery¹, Obafemi Awolowo University Teaching Hospitals Complex, Ile-Ife, Osun State, Nigeria

Correspondence: Dr. Bukunmi M Idowu, Department of Radiology, Obafemi Awolowo University Teaching Hospitals Complex, Ile-Ife, Osun State, Nigeria. E-mail: ibmcontacts@gmail.com

Abstract

This is a case report of Wilms' tumor which presented with varicocele in an 11-month old infant. The age of the patient and the uncommon mode of presentation are the unique features of this case. This case emphasizes the need to exclude a renal tumor in children with scrotal varicoceles.

Key words: Nephroblastoma; pediatrics; sonography; varicocele; Wilms' tumor

Introduction

Wilms' tumor (WT), also known as Nephroblastoma, is the most common malignant abdominal neoplasm in children.^[1] It usually presents with abdominal mass or pain. Hematuria, hypertension, urinary tract infection, and other gastrointestinal (GI) symptoms are less common presenting complaints.^[2] Furthermore, presentation with varicocele in children is extremely rare – a thorough and exhaustive search yielded only three previously reported cases in English language literature.^[3-5] In addition, those previously reported cases were in much older children than the index case (two to four-and-a-half years old).^[3-5]

Case Report

An 11-month old male infant presented to the Pediatric Emergency Unit on account of painful, left hemiscrotal swelling noticed by the mother 4 days prior to presentation. There was no history of hematuria, crying on micturition, abdominal swelling, abdominal pain, or other GI symptoms. Past medical, family, and social histories were insignificant.

Scrotal examination revealed normal bilateral testicular descent. Multiple, large, visible vessels were seen distending the left hemiscrotum (Grade III). The right hemiscrotum was normal. Abdominal examination revealed left flank/left upper quadrant fullness causing asymmetry of the abdomen. There was also a large, nontender, ballotable left abdominal mass. No evidence of ascites. Both iris were present on ocular examination and the tongue appeared normal in size. (These were examined to exclude any association with Beckwith–Wiedemann syndrome.) An assessment of left-sided varicoceles secondary to a left renal mass was made.

Abdominal ultrasonography (USG) revealed a large, oval, well-circumscribed, solid mass occupying the middle and lower poles of the left kidney. The mass measured approximately 9.2 × 7.3 × 8.2 cm (L × AP × T). The mass was heterogeneous in appearance and contained an amorphous focus of increased echogenicity (possibly due to fat and/or calcium deposition). No cystic or necrotic areas were seen within it. The adjacent normal renal parenchyma appears to claw around the mass, suggesting renal origin

Access this article online

Quick Response Code:



Website:
www.ijri.org

DOI:
10.4103/ijri.IJRI_279_17

This is an open access journal, and articles are distributed under the terms of the Creative Commons Attribution-NonCommercial-ShareAlike 4.0 License, which allows others to remix, tweak, and build upon the work non-commercially, as long as appropriate credit is given and the new creations are licensed under the identical terms.

For reprints contact: reprints@medknow.com

Cite this article as: Idowu BM, Tanimola AG. Wilm's tumor presenting with scrotal varicocele in an 11-month-old boy. Indian J Radiol Imaging 2018;28:247-9.

of the mass. The mass showed moderate vascularization on Doppler sonography. The right kidney was sonographically normal. There were no metastatic deposits in the liver, no sonographic evidence of ascites, no enlarged para-aortic, or periportal lymph nodes. The inferior vena cava was patent and compressible, with adequate intraluminal color filling. The renal veins were not visualized. Other abdominal organs were within normal limits.

Scrotal sonography showed numerous, dilated, tortuous/serpiginous, hypoechoic, tubular structures (>2 mm in diameter) demonstrating florid vascularity on color Doppler insonation within the left hemiscrotum [Figure 1A and B]. Both testes and epididymides and the right hemiscrotum were sonographically normal. No abnormal fluid collection within the scrotal sacs.

On computerized tomography (CT) of the abdomen, the left renal mass was heterogeneous in appearance measuring approximately $9 \times 8 \times 8$ cm [Figure 2A]. It showed minimal contrast enhancement with a claw-like configuration of the adjacent renal tissue, which suggests the mass is of renal origin [Figure 2B]. The left renal vein was patent but appeared markedly compressed by the mass [Figure 2C]. The bowel loops were displaced contralaterally by the mass. No metastatic deposits in the liver. No ascites. Chest radiograph was normal.

At surgery, the mass was confined to the middle and lower poles of the left kidney (stage I). The left renal vein was severely compressed by the mass. The patient underwent a left nephrectomy. Histopathologic analysis confirmed the mass to be WT. Vincristine and dactinomycin were used for adjuvant chemotherapy postop.

Discussion

The worldwide prevalence of WT is 1 case per 10,000 live births.^[1] WT is relatively more common in blacks than in whites and is rare in East Asians.^[1] The peak incidence

occurs between the second and fourth years of life; it is very rare during first year of life.^[1] The index case was diagnosed in an 11-month-old male infant.

Varicoceles are abnormal dilatation, elongation, and tortuosity of the pampiniform plexus (and to a lesser extent, dilatation of the smaller cremasteric plexus) secondary to retrograde flow into internal spermatic vein.^[6] They can be idiopathic/primary/congenital or secondary.^[6] Primary/idiopathic/congenital varicoceles are due to incompetent or absent valve at level of left renal vein or inferior vena cava on right side^[6] and usually do not become clinically obvious until puberty.^[3] Secondary varicoceles develop due to compression of the left renal vein by a tumor, aberrant renal artery, obstructed renal vein, hydronephrosis, and cirrhosis.^[6] Secondary varicoceles do not empty on recumbent position (nondecompressible varicocele).^[6]

The prevalence of idiopathic/primary/congenital varicoceles is about 0.2% in boys from birth to 6 years of age.^[7] Therefore, the presence of varicocele in a boy aged <6 years old should trigger a careful search for a secondary cause. Since varicoceles are almost never seen in children <9 years old,^[8] when seen in this age group, a WT is a strong possibility,^[8] just as it turned out in the index case. Consequently, it is apposite to perform renal and/or retroperitoneal scan in children with varicoceles on scrotal sonography.^[9]

The prognosis and survival rate of WT depends on pathologic pattern, age at the time of diagnosis, and extent

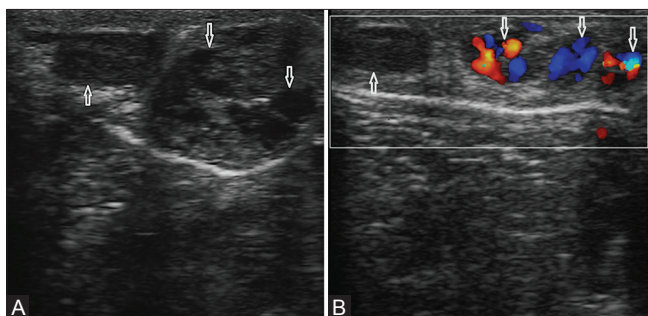


Figure 1 (A and B): (A) Gray-scale sonogram of the left scrotum showing multiple, dilated, tortuous/serpiginous, hypoechoic, tubular structures (downward arrows); the left testis with its mediastinum is sonographically normal (upward arrows). (B) Duplex sonogram of the left scrotum showing florid vascularity of the hypoechoic tubular structures on color Doppler insonation (downward arrows)

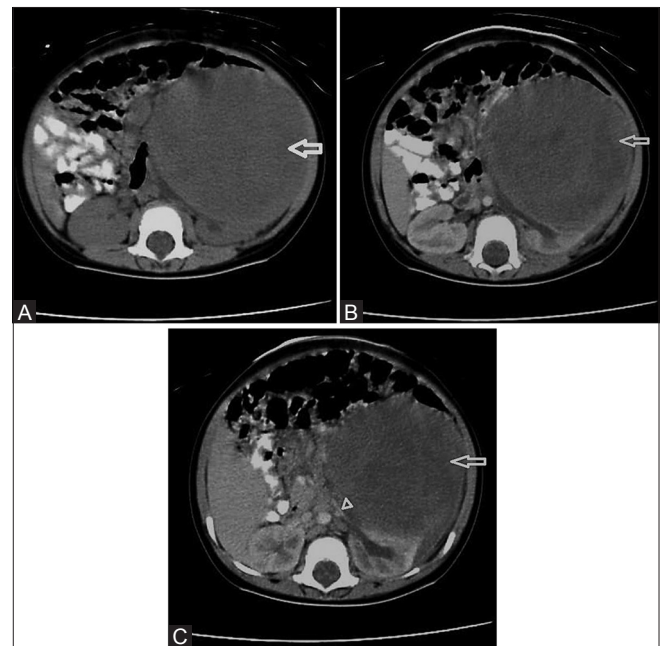


Figure 2 (A-C): (A–C) Plain, arterial, and venous phases of axial abdominal CT showing a heterogeneous mass with minimal contrast enhancement on the left side of the abdomen (arrow) compressing the left renal vein (arrowhead)

of disease.^[1] Four-year relapse-free survival is 91% for stage I, 88% for stage II, 79% for stage III, and 78–84% for stage IV.^[1] The index patient had stage I disease at presentation, and is still alive and relapse-free 3 years after diagnosis.

In conclusion, radiologists, pediatricians, and pediatric surgeons should be aware that testicular varicocele is a rare presentation of WT in children.

Declaration of patient consent

The authors certify that they have obtained all appropriate patient consent forms. In the form the patient(s) has/have given his/her/their consent for his/her/their images and other clinical information to be reported in the journal. The patients understand that their names and initials will not be published and due efforts will be made to conceal their identity, but anonymity cannot be guaranteed.

Financial support and sponsorship

Nil.

Conflicts of interest

There are no conflicts of interest.

References

1. Dahnert W. Wilms tumor. In: Dahnert W, editor. Radiology review manual, 7th ed. Baltimore: Williams & Wilkins; 2011. p. 1010-1.
2. Paulino AC, Coppes MJ, Sakamoto KM, Windle ML, Bergstrom SK, Arceci RJ. Wilms tumor. Updated on: 25th March, 2013. Available from: http://emedicine.medscape.com/article/989398-overview#s_howall. [Accessed on 2014 July 5]
3. Monroe K, Navoy J, Odrezin GT, Nichols MH, Polhill R. Varicocele as a presenting feature of Wilms' tumor. *Pediatr Emerg Care* 1995;11:300-1.
4. Auld AW. Wilms' tumour presenting as a varicocele. *J Pediatr Surg* 1976;11:471-2.
5. Eklöf O, Sandstedt B, Söderlund S, Wikstad I, Ahström L. Paravertebral widening in a case of recurrent Wilms' tumor. *Pediatr Radiol* 1982;12:255-7.
6. Dahnert W. Varicocele. In: Dahnert W, editor. Radiology review manual. 7th ed. Baltimore: Williams & Wilkins; 2011. p. 1009.
7. Saleh RA, Agarwal A, Oder M, Hubaveshki S, Tomova A, Kumanov P. Incidence of varicocele in children and adolescents: A population-based study on 1200 young Bulgarian males. *Fertil Steril* 2002;78 Suppl 1:S68.
8. El-Saeity NS, Sidhu PS. "Scrotal varicocele, exclude a renal tumour." Is this evidence based? *Clin Radiol* 2006;61:593-599
9. Robson J, Wolstenhulme S, Knapp P. Is there a co-association between renal or retroperitoneal tumours and scrotal varicoceles? A systematic review. *Ultrasound* 2012;20:182-191.