

## Original Article

# First two bilateral hand transplantations in India (Part 3): Rehabilitation and immediate outcome

Mohit Sharma<sup>1</sup>, Subramania Iyer<sup>1,2,3</sup>, P. Kishore<sup>1</sup>, Jimmy Mathew<sup>1</sup>, Sundeep Vijayaraghavan<sup>1</sup>, Ravi Sankaran<sup>4</sup>, Arun N. Nair<sup>4</sup>, R. Janarthanan<sup>1</sup>, Abhijeet Wakure<sup>1</sup>, Raghuveer Reddy<sup>1</sup>, S. M. Chetan Mali<sup>1</sup>, Visakh Varma<sup>1</sup>, Ashish Chaudhari<sup>1</sup>, Swapnil Dhake<sup>1</sup>, Akshay Omkumar<sup>1</sup>

Departments of <sup>1</sup>Plastic and Reconstructive Surgery, <sup>2</sup>Head and Neck Surgery, <sup>3</sup>Craniofacial Surgery and <sup>4</sup>Physical Medicine and Rehabilitation, Amrita Institute of Medical Sciences, Kochi, Kerala, India

**Address for correspondence:** Prof. Mohit Sharma, Tower 1, 4<sup>th</sup> Floor, Amrita Institute of Medical Sciences, Ponekkara P. O, Kochi - 682 041, Kerala, India. E-mail: ammasmohit@gmail.com

## ABSTRACT

**Introduction:** This report covers the strategies adopted for rehabilitation for the first and second dual hand transplants performed in India. **Materials and Methods:** The team, under a trained physiatrist, including physiotherapy and occupational therapy personnel, was involved in the management of both these patients. The management protocol was developed considering previous reports as well as our management strategies in the rehabilitation of the replanted hands. The involvement of the team with the patients started in the 1st week itself and continued on a daily basis for the entire year. **Results:** Outcome analysis was performed at 6 months and 1 year using the disability of shoulder and hand evaluation and hand transplant scoring system. Functional magnetic resonance imaging was done at the end of 1 year to assess the cortical integration of the transplanted hand. **Conclusion:** Despite more than 110 hands being transplanted worldwide, hand transplant remains an experimental procedure. It is still not considered the “standard of care” for hand amputees. Outcome analyses performed worldwide do indicate that the procedure can provide a substantial improvement in the quality of life for the hand amputee, especially the bilateral amputees.

## KEY WORDS

Composite tissue allotransplantation; disability of shoulder and hand; hand transplant scoring system; rehabilitation after hand transplantation; vascularised composite allotransplantation

## INTRODUCTION

After transplantation of the hand, the functional results are equal or better when compared to replants.<sup>[1]</sup> The results are more predictable as

the structures can be connected together in a cleaner environment and under adequate tension unlike many replant situations where crushing and loss of tissue is present. Exceptions can occur in transplants too, as

This is an open access article distributed under the terms of the Creative Commons Attribution-NonCommercial-ShareAlike 3.0 License, which allows others to remix, tweak, and build upon the work non-commercially, as long as the author is credited and the new creations are licensed under the identical terms.

**For reprints contact:** reprints@medknow.com

**How to cite this article:** Sharma M, Iyer S, Kishore P, Mathew J, Vijayaraghavan S, Sankaran R, *et al.* First two bilateral hand transplantations in India (Part 3): Rehabilitation and immediate outcome. *Indian J Plast Surg* 2017;50:161-7.

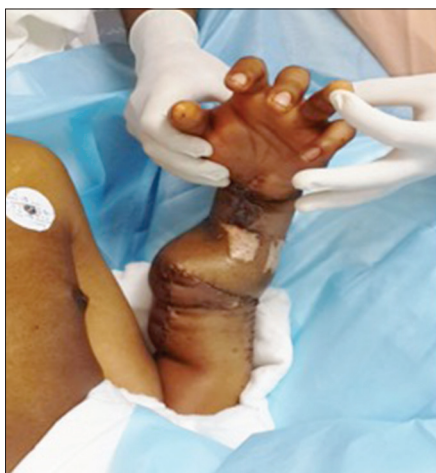Access this article online	
Quick Response Code: 	Website: www.ijps.org
	DOI: 10.4103/ijps.IJPS_95_17

was seen in the first case where the left hand needed primary tendon transfers due to the presence of extensive fibrosis. The results depend on immediate and persistent physiotherapy and occupational therapy as well as splinting. Rehabilitation regimes are well described in the literature<sup>[2-4]</sup> but each programme formulates regimes comfortable for them. This paper deals with the post-operative rehabilitative regime used in the first and second bilateral hand transplants in India. The outcome analysis after hand transplants have been mainly by patient reported scoring systems like the disabilities of the arm, shoulder and hand outcome questionnaire (DASH) scoring.<sup>[5]</sup> Hand Transplant Scoring system (HTSS) is a subjective scoring system developed by the International registry for Hand and composite tissue transplantation which has been used for comparative reporting.<sup>[6]</sup> The outcome at 1 year of both the patients is described based on these scoring systems as well as other parameters.

## MATERIALS AND METHODS

### Rehabilitation protocol

The same protocol was used for both the patients. The patients were given intense physical and occupational therapy for 5 h a day for 1 year. This was done in two sessions of 2½ h each every day. In the first 2 weeks, the aim was to prevent hand swelling and to prevent joint stiffness and to promote tendon gliding. This was achieved by hand elevation and by passively extending the fingers with wrist flexion and by passively flexing the fingers with wrist extension [Figure 1]. Controlled active motion of fingers and wrist was encouraged from the 2<sup>nd</sup> post-operative day onwards. At other times, the hand was immobilised in a wrist extension splint.



**Figure 1:** Passive physiotherapy given from second post-operative day

Third week onwards, in addition to the above, activities of daily living like eating and drinking were begun gradually. The splint was changed to a dynamic splint during the day and a static splint during the night to maintain the hands in a functional position [Figure 2a and b]. The aim to be achieved by the end of the 1<sup>st</sup> month was near normal passive and active range of motion of the wrist and fingers. This was observed in both the patients.

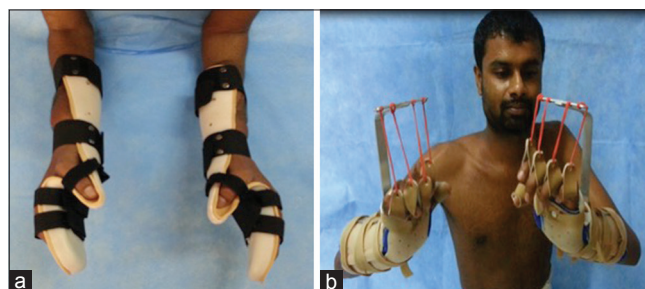
In the second and 3<sup>rd</sup> month, in addition to the above, passive stretching of the joints was started to prevent adhesion formation and joint stiffness. Full non-resistive use of the hands was permitted and care was taken to protect the insensate hand from inadvertent injury. Neuro-muscular stimulation of the small muscles of the hand was started. Fourth month onwards, resistance training was started to improve grip strength of the hands. At 6 months, attention was given to sensory re-education and fine motor coordination. Occupational rehabilitation was started at this time.

During the entire rehabilitation programme, attention was given to functional rehabilitation of the hands. To ensure this, various activities were incorporated starting from simple ones like throwing and catching a ball, tearing bits of paper, opening and closing lids of bottles. Later on this moved over to more complex ones like origami, playing the keyboard, sketching and painting. These helped to make the rehabilitation process more interesting [Figure 3].


### Outcome assessment

This was done at 6 months and 12 months post-transplant in both patients. The hand function was assessed by some definitive measurables as follows.

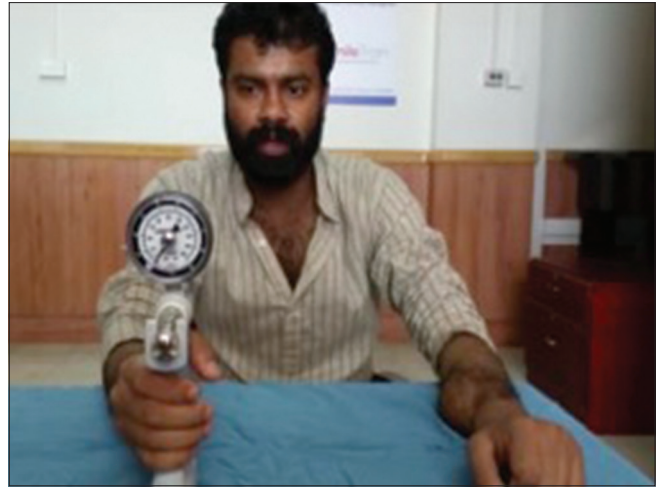1. The passive and active range of motion for the forearm (supination/pronation), wrist and fingers (flexion/extension)
2. Strength and motor outcomes using the Kapandji score<sup>[7]</sup> for opposition (thenar intrinsic muscle



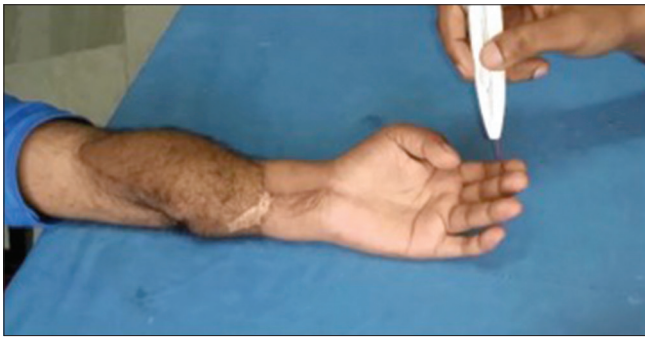**Figure 2:** (a) Static splint. (b) Dynamic splint



**Figure 3:** Functional rehabilitation at 1 year



**Figure 4:** Strength testing with dynamometer at 1 year



**Figure 5:** Monofilament testing



**Figure 6:** Nine hole peg test

recovery), the grip dynamometer and the Medical research council muscle power grading system.<sup>[8]</sup> [Figure 4]

3. Sensory recovery outcomes using the static two point discrimination, Semmes Weinstein monofilament test,<sup>[9]</sup> [Figure 5] presence of pain and temperature sensations and stereognosis
4. Dexterity assessment using the 9-hole peg test [Figure 6]
5. The patient reported outcome measures (PROMs) analysed using the Disability of Arm Shoulder and Hand (DASH) score.<sup>[5]</sup> DASH score was measured before the transplant and at the time of outcome analysis
6. HTSS score<sup>[6]</sup> was measured at the time of outcome analysis at 1 year.

In addition, cortical re-integration of the transplanted hands was assessed by doing functional magnetic resonance imaging (MRI) for both the patients.

Functional outcomes after 1 year.

### Patient 1

The passive and active range of motion achieved by the first patient after 1 year is described in Table 1.

In the right hand, the patient developed a Kapandji score of 10, whereas in the left hand, it was 7. On grip dynamometer, he had grip strength of 20 kg in the right hand and 5 kg in the left hand. The MRC muscle power grades for individual muscles tested are shown in Table 2. In general, the proximal muscle groups gained more power than the distal ones. The electromyography findings for the muscles of the transplanted hands [Table 3a] showed normal configuration and re-innervation of the muscles of the hands. He has achieved a very good recovery of pain and temperature sensation. He achieved stereognosis for both large and small sized objects in both hands. He achieved a mean static 2PD of 11 mm in both hands. He achieved a mean static 2PD of 11 mm in both hands. He could sense the pressure by a Semmes Weinstein monofilament of the red colour in the left hand and purple colour in the right hand [Table 4].

The pre-operative DASH score was 91.7 while the post-operative score at 1 year was 13.3 giving a net difference of 78.4. His HTSS score at after 1 year was 85 (excellent) for the right hand and 70.5 (good) for the left hand. The details

**Table 1: Range of motion**

Level	Normal ROM	Recipient							
		Recipient 1				Recipient 2			
		Left		Right		Left		Right	
		Passive	Active	Passive	Active	Passive	Active	Passive	Active
Forearm	Supination (85°)	Full	Full	Full	Full	20	10	60	60
	Pronation (70°)	Full	Full	Full	Full	Full	80	60	50
Wrist	Flexion (70°)	115	45	110	75	60	50	75	30
	Extension (75°)	96	40	100	60	90	40	75	90
MCP	Flexion (135°)	106	48	104	92	78	65	60	66
PIP	Flexion (100°)	100	57	98	79	78	69	80	80
DIP	Flexion (80°)	47.5	45	105	65	90	90	90	70

ROM: Range of motion, MCP: Metacarpophalangeal joint, PIP: Proximal interphalangeal joint, DIP: Distal interphalangeal joint

**Table 2: MRC Grading and Dynamometer Strength**

Muscles	Recipient 1		Recipient 2	
	Left	Right	Left	Right
PT	5	5	5	5
Supinator	5	5	5	5
FDS/FDP	4	5	4	4
ECRB	4	5	5	5
ADM	3	4	3	3
FDI	3	4	3	3
ABP	3	4	3	3
Dynamometer	5 kg	20 kg	10 kg	18 kg

**Table 3a: Maximum volitional activity – Patient 1**

Intrinsic muscle	Amplitude	Poly	Config	Recruitment	Pattern	Effort
FDI						
Right	629	None	Normal	Reduced	Discrete	Submax
Left	477	None	Normal	Reduced	Discrete	Submax
ADM						
Right	1784	None	Normal	Reduced	Discrete	Submax
Left	410	None	Normal	Reduced	Discrete	Submax
APB						
Right	911	None	Normal	Reduced	Discrete	Submax
Left	1853	None	Normal	Reduced	Discrete	Submax

**Table 3b: Maximum Volitional Activity – Patient 2**

Intrinsic muscle	Amplitude	Poly	Config	Recruitment	Pattern	Effort
FDI						
Right	545-626	None	Normal	Reduced	Discrete	Submax
Left	128	None	Normal	Reduced	Discrete	Submax
ADM						
Right	1456	None	Normal	Reduced	Discrete	Submax
Left	553	None	Normal	Reduced	Discrete	Submax
APB						
Right	253-356	None	Normal	Reduced	Discrete	Submax
Left	220-422	None	Normal	Reduced	Discrete	Submax

of HTSS score of patient 1 are given in Table 5. He was able to complete the nine-hole peg test in 59 s. Functional MRI showed increased blood flow in the contralateral cerebral cortex pre-central gyrus area during the activity of the hand indicating good cortical re-integration.

**Patient 2**

The passive and active range of motion achieved after 1 year was satisfactory and is described in in Table 1. In the right hand, the patient developed a Kapandji score of 4, whereas in the left hand, it was 3. On grip dynamometer, he had grip strength of 18 kg in the right hand and 10 kg in the left hand. The MRC muscle power grades for individual muscles tested are given in Table 2. The proximal muscle groups have gained grade 4–5 power while the distal muscle groups have gained grade 3–4 power. The electromyography findings for the muscles of the transplanted hands [Table 3b] showed re-innervation pattern with normal configuration.

He also achieved complete recovery of pain, cold and hot sensation as well as stereognosis for large- and medium-sized objects in both hands after 1 year. The mean static 2PD was 8 mm in the left hand and 6 mm in the right hand. He could sense the pressure by a Semmes Weinstein monofilament of the purple colour in both hands [Table 4].

The pre-operative DASH score was 86, whereas the post-operative score at 1 year was 9.1 giving a net difference of 76.9. His HTSS score at after 1 year was 80.5 (excellent) for the right hand and 77 (good) for the left hand. The details of his HTSS score are given in Table 6. He was able to complete the 9-hole peg test in 4 min and 35 s. Functional MRI showed increased blood flow in the contralateral cerebral cortex pre-central gyrus area during the activity of the hand indicating good cortical re-integration.

**DISCUSSION**

Considering the objective functional outcomes, both patients did extremely well in the sensory recovery as has been reported in the other hand transplants worldwide. Both the patients have shown a progressive

**Table 4: Monofilament testing**

Recipient 1		Recipient 2	
Left	Right	Left	Right
Red	Purple	Purple	Purple

**Table 5: Hand transplant scoring system scores at 1 year for patient 1**

HTSS - Parameters	Recipient 1	
	Left	Right
Appearance	16	17
Sensibility	15	16
Movement	12.5	17
Psychological and social appearance	14	14
Daily activities and work status	12	15
Satisfaction and general well being	5	10
Total	74.5	89
Grade	Good	Excellent

**Table 6: Hand transplant scoring system score at 1 year for patient 2**

HTSS - Parameters	Recipient 2	
	Left	Right
Appearance	15	15
Sensibility	16	16
Movement	13	13.5
Psychological and social appearance	15	15
Daily activities and work status	12	15
Satisfaction and general well being	10	10
Total	81	84.5
Grade	Excellent	Excellent

improvement in the two point discrimination. Both of them have very good protective sensation and touch localization. Interestingly, regarding the stereognosis, the first recipient is able to identify even small objects like small keys and metal screws.

The motor function of the left hand of the first patient is poorer than that of the other three hands. After the accident which resulted in the amputation, he had undergone multiple debridement in the left stump, which resulted in the loss of many flexor and extensor muscles. The flexor aspect had only Palmaris Longus and Flexor Digitorum Superficialis while the extensor aspect had only the Brachioradialis, Extensor Digitorum Communis and Abductor Pollicis Longus. These muscle units were used to motorise the wrist and finger joints by tendon transfers details of which are discussed elsewhere. This probably resulted in the limitation in flexion of MCP and PIP joints of the left hand. The grip strength in this hand is also less than the other three hands due to the missing motors on flexor aspect. The second recipient had the limitation of supination in his left hand. This was probably due to the impingement

of the slightly misplaced dorsal radial plate upon ulna during attempted supination. Thumb opposition has been measured based on Kapandji score. The first recipient has a markedly greater range of opposition as compared to the second recipient, with the dominant hand already having achieved a complete range of opposition [Figure 7]. The clinical findings are corroborated with the EMG records which show almost four times greater amplitude of the compound muscle action potentials of Abductor Pollicis Brevis of the first recipient compared to the second.

Excellent bone healing has been achieved in the first recipient [Figure 8]. Second recipient's left ulna was lagging behind but is now showing signs of ossification. On functional MRI assessment, both hands of both the recipients show excellent cortical re-integration [Figure 9].

More important than these objective outcomes are PROMs. We used the DASH and the HTSS scores to assess the patient reported outcome. DASH is a validated score which can detect changes in disability of the upper extremity over time.<sup>[10]</sup> The difference of 15 points between pre-operative and post-operative DASH scores is indicative of a significant improvement in the functional status of the hand.<sup>[5]</sup> The DASH score of our first patient improved by 78.4 points while that of our second patient improved by 76.9 points implying a marked reduction in their disability status. HTSS score is a good tool to assess and compare the outcomes. It cannot be measured before the transplant takes place; hence, the change in functional status before and after the transplant cannot be quantified. Using this PROM scale, the outcome was rated as "Good" for the left hand (74.5) and "Excellent" for right hand (89) of recipient 1. For recipient 2, the outcome was rated "Excellent" for both left (81) and right (84) hands.

Although we have not done a formal study comparing outcomes of our patients with those performed in other centres, a glance through the available literature<sup>[11-14]</sup> shows that our outcomes are as good or better than many centres which have reported their outcome. Bernardon *et al.*<sup>[13]</sup> reviewed 5 bilateral hand transplants and reported an average improvement in DASH score of 30 points. Landin *et al.*<sup>[14]</sup> in their systematic review of 28 hand transplant patients included 5 patients with bilateral below elbow transplants. They reported a mean pre-operative DASH score of 64.5 (range 29–98), and mean post-operative DASH score of 44.8 (range 18–71) giving a mean improvement of 20 points for these patients.

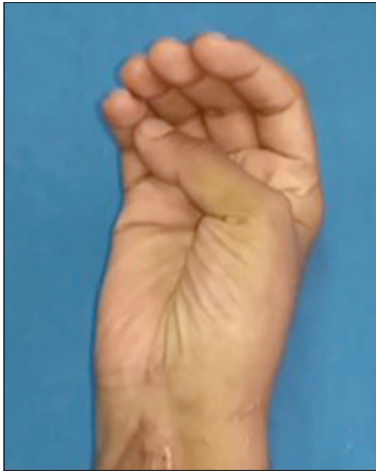

Figure 7: Kapandji score 10 at 1 year

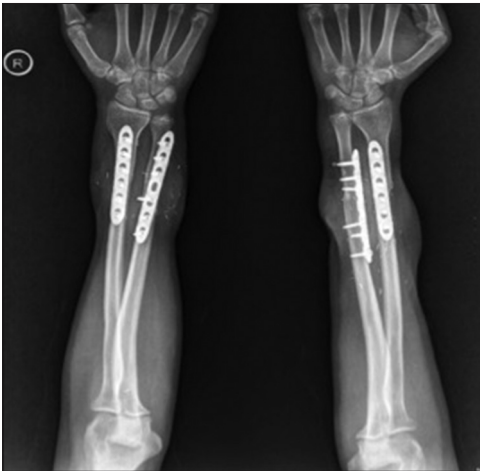

Figure 8: Bone healing 1 year post-transplant

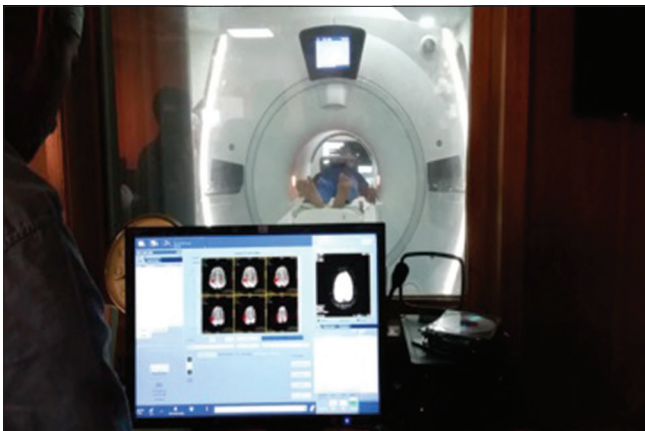

Figure 9: Functional magnetic resonance imaging showing cortical integration at 1 year

## CONCLUSION

Despite more than 110 hands being transplanted worldwide, hand transplant remains an experimental procedure. It is still

not considered the “standard of care” for hand amputees. Outcome analysis performed worldwide does indicate that the procedure can provide a substantial improvement in the quality of life for the hand amputee, especially the bilateral amputees. Concerns about short- and long-term complications of immunosuppression may offset the benefits gained out of hand transplantation.<sup>[15]</sup>

The outcomes of our patients at the end of the 1<sup>st</sup> year are encouraging. Unlike a solid organ transplant, the function of the transplanted hand starts to improve slowly over time, but especially in distal hand transplants the patient satisfaction and improvement in the quality of life have been significant. The first patient has been absorbed into our institution as a transplant counselling assistant and the second one has joined back in his previous post. It is quite possible that the long-term outcomes of our patients remain excellent and if the patients are able to bear the immunosuppression well, more and more people could benefit from the upcoming field of vascularised composite tissue allotransplantation.

## Declaration of patient consent

The authors certify that they have obtained all appropriate patient consent forms. In the form the patient(s) has/have given his/her/their consent for his/her/their images and other clinical information to be reported in the journal. The patients understand that their names and initials will not be published and due efforts will be made to conceal their identity, but anonymity cannot be guaranteed.

## Financial support and sponsorship

Nil.

## Conflicts of interest

There are no conflicts of interest.

## REFERENCES

1. Breidenbach WC, Gonzales NR, Kaufman CL, Klapheke M, Tobin GR, Gorantla VS, *et al.* Outcomes of the first 2 American hand transplants at 8 and 6 years posttransplant. *J Hand Surg Am* 2008;33:1039-47.
2. Ninkovic M, Weissenbacher A, Gabl M, Pierer G, Pratschke J, Margreiter R, *et al.* Functional outcome after hand and forearm transplantation: What can be achieved? *Hand Clin* 2011;27:455-65, viii-ix.
3. Petruzzo P, Dubernard JM. The international registry on hand and composite tissue allotransplantation. *Clin Transpl* 2011:247-53.
4. Bueno E, Benjamin MJ, Sisk G, Sampson CE, Carty M, Pribaz JJ, *et al.* Rehabilitation following hand transplantation. *Hand (N Y)* 2014;9:9-15.

5. Solway S, Beaton DE, McConnell S, Bombardier C. The DASH Outcome Measure User's Manual. Toronto: Institute for Work & Health; 2002.
6. Lanzetta M, Petruzzo P. A comprehensive functional score system in hand transplantation. In: Lanzetta M, Dubernard JM, editors. *Hand Transplantation*. Milan: Springer-Verlag; 2007. p. 355-62.
7. Kapandji A. Clinical test of apposition and counter-apposition of the thumb. *Ann Chir Main* 1986;5:67-73.
8. Medical Research Council. Aids to Examination of the Peripheral Nervous System. Memorandum no. 45. London: Her Majesty's Stationary Office; 1976.
9. Bell-Krotoski J, Weinstein S, Weinstein C. Testing sensibility, including touch-pressure, two-point discrimination, point localization, and vibration. *J Hand Ther* 1993;6:114-23.
10. Gummesson C, Atroshi I, Ekdahl C. The disabilities of the arm, shoulder and hand (DASH) outcome questionnaire: Longitudinal construct validity and measuring self-rated health change after surgery. *BMC Musculoskelet Disord* 2003;4:11.
11. Shores JT, Brandacher G, Lee WP. Hand and upper extremity transplantation: An update of outcomes in the worldwide experience. *Plast Reconstr Surg* 2015;135:351e-60e.
12. Petruzzo P, Dubernard JM. World experience after more than a decade of clinical hand transplantation: Update on the French program. *Hand Clin* 2011;27:411-6, vii.
13. Bernardon L, Gazarian A, Petruzzo P, Packham T, Guillot M, Guigal V, *et al.* Bilateral hand transplantation: Functional benefits assessment in five patients with a mean follow-up of 7.6 years (range 4-13 years). *J Plast Reconstr Aesthet Surg* 2015;68:1171-83.
14. Landin L, Bonastre J, Casado-Sanchez C, Diez J, Ninkovic M, Lanzetta M, *et al.* Outcomes with respect to disabilities of the upper limb after hand allograft transplantation: A systematic review. *Transpl Int* 2012;25:424-32.
15. Iyer S. Vascularised composite allotransplants: Transplant of upper extremities and face. *Indian J Plast Surg* 2015;48:111-8.