

Original Article

Computed tomography angiographic study of internal mammary perforators and their use as recipient vessels for free tissue transfer in breast reconstruction

Aditya V. Kanoi, Karnav B. Panchal, Saugata Sen¹, Gautam Biswas

Departments of Plastic and Reconstructive Surgery and ¹Radiodiagnosis, TATA Medical Center, Kolkata, West Bengal, India

Address for correspondence: Dr. Gautam Biswas, Department of Plastic and Reconstructive Surgery, TATA Medical Center, Kolkata, West Bengal, India. E-mail: dr.biswas@gmail.com

ABSTRACT

Context: The internal mammary artery perforator vessels (IMPV) as a recipient in free flap breast reconstruction offer advantages over the more commonly used thoracodorsal vessels and the internal mammary vessels (IMV). **Aims:** This study was designed to assess the anatomical consistency of the IMPV and the suitability of these vessels for use as recipients in free flap breast reconstruction. **Patients and Methods:** Data from ten randomly selected female patients who did not have any chest wall or breast pathology but had undergone a computed tomography angiography (CTA) for unrelated diagnostic reasons from April 2013 to October 2013 were analysed. Retrospective data of seven patients who had undergone mastectomy for breast cancer and had been primarily reconstructed with a deep inferior epigastric artery perforator free flap transfer using the IMPV as recipient vessels were studied. **Results:** The CTA findings showed that the internal mammary perforator was consistently present in all cases bilaterally. In all cases, the dominant perforator arose from the upper four intercostal spaces (ICS) with the majority (55%) arising from the 2nd ICS. The mean distance of the perforators from the sternal border at the level of pectoralis muscle surface on the right side was 1.86 cm (range: 0.9–2.5 cm) with a mode value of 1.9 cm. On the left side, a mean of 1.77 cm (range: 1.5–2.1 cm) and a mode value of 1.7 cm were observed. Mean perforator artery diameters on the right and left sides were 2.2 mm and 2.4 mm, respectively. **Conclusions:** Though the internal mammary perforators are anatomically consistent, their use as recipients in free tissue transfer for breast reconstruction eventually rests on multiple variables.

KEY WORDS

Computed tomography angiography; free flap breast reconstruction; hand-held Doppler; internal mammary perforators; recipient vessels

Access this article online	
Quick Response Code: 	Website: www.ijps.org
	DOI: 10.4103/ijps.IJPS_168_16

This is an open access article distributed under the terms of the Creative Commons Attribution-NonCommercial-ShareAlike 3.0 License, which allows others to remix, tweak, and build upon the work non-commercially, as long as the author is credited and the new creations are licensed under the identical terms.

For reprints contact: reprints@medknow.com

How to cite this article: Kanoi AV, Panchal KB, Sen S, Biswas G. Computed tomography angiographic study of internal mammary perforators and their use as recipient vessels for free tissue transfer in breast reconstruction. *Indian J Plast Surg* 2017;50:50-5.

INTRODUCTION

The thoracodorsal vessels (TDVs) and the internal mammary vessels (IMVs) are the most commonly used recipient vessels for free tissue transfer in breast reconstruction surgery.^[1-4] Alternative recipient vessels are used, by and large as a second choice.^[1,5] Ever since Taylor and Palmer's description of cutaneous angiosomes and perforator concept,^[6] the armamentarium of clinically applicable perforators has expeditiously expanded. One such perforator, the internal mammary artery perforator vessels (IMPVs) which form the vascular basis of the popular deltopectoral flap as proposed by Bakamjian *et al.*,^[7] was described as a recipient vessel for free tissue transfer by Blondeel^[8] and Guzzetti and Thione.^[9]

The objectives of our study were to determine the anatomical consistency of the IMPV and the suitability of IMPV for use as recipients in free flap breast reconstruction.

PATIENTS AND METHODS

Radio-anatomical study

Following initial success with the use of IMPV as recipients for free tissue breast reconstruction, we carried out a computed tomography angiographic (CTA) study to assess the anatomical consistency of these perforators. Data from ten randomly selected female patients who did not have any chest wall or breast pathology but had undergone a CTA for unrelated diagnostic reasons from April 2013 to October 2013 were analysed.

Helical computed tomography evaluation of internal mammary and perforator vessels was performed from the thoracic inlet to the xiphoid process of sternum. CTA was performed using a Discovery STE 64-slice scanner (GE Medical System, Chicago, Illinois, US). Patients were examined in the supine position. Non-ionic contrast was injected at a rate of 4 ml/s, with a contrast volume of 1.5–2 ml/kg body weight (350 mg of iodine/ml). Images were acquired during breath hold in the arterial phase using bolus tracking method. The region of interest was placed at the arch of the aorta with a threshold value of 100 Hounsfield units. Imaging parameters included a beam pitch of 1:1.35, tube potential of 120 kVp and tube current of 150–320 mA. Multiplanar reconstruction was performed from the raw data with a minimum slice thickness of 1 mm and 50% overlapping. Image

reformation was performed using a volume-rendering technique on an Advantage Window Workstation (version 4.5, GE Medical System, Chicago, Illinois, US). For each patient, both sides were examined. A total of twenty sides were assessed. The evaluation parameters included the intercostal space (ICS) through which the perforators emerged; the distance of these perforators from the sternal border and the artery diameter. When more than one perforator was present, the assessment was done on the dominant (largest) perforator of each side.

Clinical study

Retrospective data from November 2012 to March 2014 of 15 patients who had undergone mastectomy for breast cancer and had been primarily reconstructed with a deep inferior epigastric artery perforator (DIEP) free flap transfer were considered. During this period, all the 15 patients planned for reconstruction with DIEP free flaps were subjected to a pre-operative perforator mapping using a hand-held Doppler (HHD) (model no. MD2; 8 MHz probe; Huntleigh Diagnostics, Cardiff, UK). Those that demonstrated a strong perforator signal in the 2nd or 3rd ICS were selected for free tissue breast reconstruction using the IMPV as recipients. A total of seven non-consecutive patients were identified who had undergone DIEP free flap transfer using the IMPV as recipient vessels. Retrospective data of these patients were studied to determine the clinical suitability of the IMPV for use as recipients in free tissue breast reconstruction.

RESULTS

The CTA findings showed that the internal mammary perforator artery was consistently present in all cases on both sides [Figure 1]. In one patient (case 4), the perforator was attenuated, being reduced in calibre and length. In all cases, the dominant perforator arose from the upper four intercostal spaces (ICS), with the majority (55%) arising from the 2nd ICS followed by the 1st ICS (25%). The mean distance of the perforators from the sternal border at the level of pectoralis muscle surface on the right side was 1.86 cm (range: 0.9–2.5 cm) with a mode value of 1.9 cm. On the left side, a mean of 1.77 cm (range: 1.5–2.1 cm) and a mode value of 1.7 cm were observed. Mean perforator artery diameters on the right and left sides were 2.2 mm and 2.4 mm, respectively [Table 1]. The accompanying perforator veins were not visualised or assessed radiologically during the CTA study.

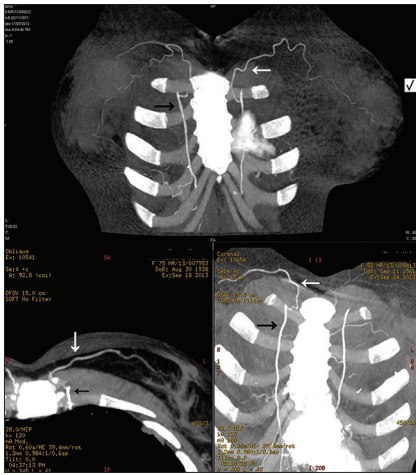


Figure 1: Computed tomography angiographic images showing the internal mammary artery perforator (white arrows) with parent internal mammary artery (black arrows). Note the long, tortuous course of the perforators

Table 1: Computed tomographic angiography data of internal mammary artery perforators

n	Intercostal space		Distance from sternal border (cm)		Diameter (mm)	
	Left	Right	Left	Right	Left	Right
1	First	First	2.5	1.8	2.6	2.3
2	Second upper part	Second lower part	1.5	1.9	2.0	2.8
3	Third upper	Second lower	2.2	2.1	2.7	1.7
4	First attenuated	Second lower	0.9	1.5	1.7	2.8
5	Second	Second	1.6	1.7	2.7	2.7
6	Third upper	First	2.3	1.7	2.6	2.9
7	Third upper	Second upper	1.9	1.5	2.4	2.2
8	Second upper	First lower	1.9	2.1	2.6	2.3
9	Second upper	Fourth	1.9	1.7	3.1	2.2
10	Second lower	Second	1.9	1.8	1.9	2.6

Of the 15 patients undergoing DIEP flap breast reconstruction, the IMPVs were used as recipients in seven (47%) patients. In all the seven patients who had undergone free flap breast reconstruction with IMPV as recipient vessels, pre-operative HHD demonstrated strong Doppler signals in the 2nd or 3rd ICS. This corroborated with the intraoperative findings [Figure 2] with the mapped perforators localised by the HHD in the 2nd and 3rd ICS being successfully identified and dissected out. In all cases where the IMPV was used as a recipient, the perforators were dissected out superficial to the pectoralis without intramuscular dissection. Where required, the mastectomy incisions were extended to allow for comfortable access. Apart from a single instance (5% of the cases), the perforator arteries were >1.5 mm in diameter, as measured by the vascular

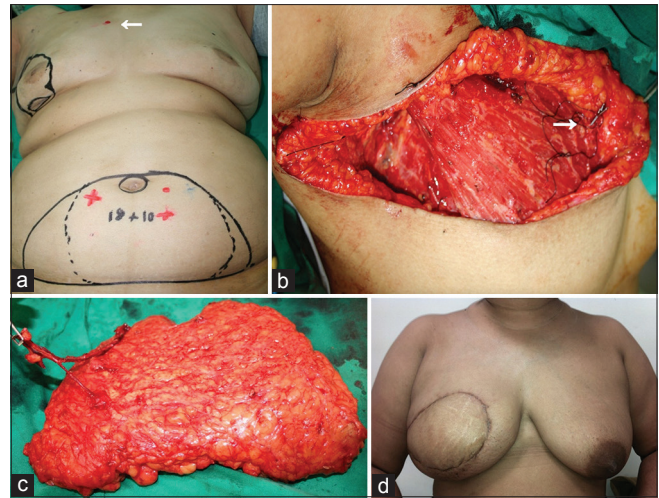


Figure 2: Photograph series of a case where the internal mammary artery perforator was used as recipient. (a) Pre-operative photograph showing the deep inferior epigastric artery perforator flap design and the skin-sparing mastectomy. Note the pre-operative Doppler mapping of the internal mammary artery perforator (arrow). (b) Recipient site following mastectomy showing the dissected perforators on the surface of the pectoralis major (arrow). (c) Harvested deep inferior epigastric artery perforator flap. (d) Six-month post-operative photograph showing a well-settled flap and good size and contour match

clamp markings. The accompanying perforator veins, while being thin walled, were seen to have comparable diameters as the arteries. Though there were issues with vessel size mismatch, vessel size discrepancy of more than 50% was not encountered for either the arterial or venous anastomosis and this could be adjusted for using standard microsurgical techniques. In all cases, a single venous anastomosis was performed. There was no flap loss, partial or complete, in these patients.

DISCUSSION

The thoracodorsal and internal mammary pedicle are a common choice as recipient vessels for free flap breast reconstruction. The TDVs are frequently exposed during the axillary clearance and, as such, is readily available to the reconstructive surgeon. However, the use of TDVs as a recipient has a number of disadvantages, for instance, risk of inadvertent damage during the axillary dissection and long pedicle requirement to place the breast mound more centrally. The anastomosis in the axilla can be uncomfortable for the surgeon and more so for the assistant standing across the operating table. In addition, there is a tendency on the part of the reconstructive surgeon to place the transferred tissue more laterally on the chest to protect the pedicle and avoid any tension across the anastomosis.^[3] With the advent of sentinel lymph node biopsy, the routine exposure of this pedicle

is also on the wane leading to a decline in the use of TDVs as a preferred recipient.^[1]

Conversely, the use of the IMVs offers advantages, such as being nearly always available in delayed and secondary breast reconstruction since it is not affected by adjuvant radiotherapy and axillary dissection. In addition, the medial location of the pedicle on the chest means greater freedom in flap shaping.^[4] Lateral fullness, which is a common occurrence following breast reconstruction, can be easily revised without risk to the anastomosis. Shorter flap pedicle lengths are required to reach the recipient. There is usually no restriction to early shoulder and arm mobilisation, thereby reducing, to a large extent, the morbidity seen when the TDVs are used as recipient. Furthermore, axillary drains can be placed safely without risk to the anastomosis. Finally, the use of the IMV, thereby sparing the TDV, provides the reconstructive surgeon a lifeboat in the form of a pedicled latissimus dorsi myocutaneous flap or a thoracodorsal artery perforator flap in the eventuality that the free flap transfer is unsuccessful.^[10] The IMV, however, is far from being an ideal recipient. The access to the IMVs can be tedious, requiring removal of costal cartilage and transection of intercostal and pectoralis muscles. Sacrifice of the internal mammary artery eliminates the vessel as an option for future coronary bypass and may impair outcomes.^[11] Respiratory chest wall motion can be troublesome, mandating, at times, a change to manual ventilation or stoppage of respiration during suture placement.^[3] Albeit the TDVs and the IMVs provide similar flap survival rates,^[1] the IMV has been recommended as the recipient vessel of choice by many authors based on its numerous benefits.^[2,3]

The IMPV offers many advantages over its parent vessel. The exposure of these vessels is simplified since there is no need to remove the costal cartilage or transect the overlying intercostal and pectoralis muscles. This limited dissection needed for access in turn leads to a reduction in overall operative time. The parent vessel, the internal mammary artery, need not be sacrificed and is available as a coronary conduit should it be required. The anastomosis is comfortable, being performed at the surface of the pectoralis instead of in the depths of the intercostal space. In addition, the respiratory chest wall movements which can be quite troublesome when using the IMV are significantly dampened when using the IMPV as recipient, thereby contributing to the performance of a favourable anastomosis.

This study was designed to address concerns regarding anatomical consistency of these perforators in terms of their presence, location and anatomical variations with the use of IMPV as recipient for free flap breast reconstruction. We found the IMPV to be anatomically dependable, being bilaterally present in all patients examined. The majority of the dominant perforators were seen to arise from the second ICS. This is in agreement with other authors who also report a predilection of the dominant perforator for the second ICS.^[12,13]

An argument can be made for the need of performing a pre-operative CTA to assess the clinical suitability of these perforators as recipients. Although some authors have described the use of CTA for studying the internal mammary artery perforators,^[14] we are unaware of any study that seeks to corroborate internal mammary artery perforator diameters between CTA and intraoperative findings. In addition, few authors specify exact intraoperative perforator diameters.^[15] This is because intraoperatively perforator vessels may demonstrate vasospasm or dilatation, being affected by unavoidable factors such as tissue handling and temperature changes. Hence, diameters measured may not be representative or agree with imaging data. However, an intraoperative perforator diameter of >1.5 mm has been used by many authors as a criterion for selecting the IMPV as recipient vessels.^[11,15,16] Other issues regarding the routine employment of CTA for pre-operative perforator assessment include the increased cost and, more significantly, the risks associated with radiation exposure.

In all the seven patients demonstrating strong Doppler signals in the 2nd and 3rd ICS, the IMPV could be dissected out successfully and were found to be suitable for anastomosis. Those demonstrating dominant perforator signals in the 1st ICS were not considered since this space is usually not accessed during a standard mastectomy, and performing an anastomosis here is difficult. No increase in complication rates were seen with regard to partial or complete flap loss and fat necrosis when the IMPV was used as recipient as compared to DIEP free flap breast reconstructions using TDV and IMV as recipients. The IMPVs were used as recipient vessels in 47% of our patients. Nevertheless, we acknowledge that the limited size of our clinical series may not be representative or consistent with other studies that describe a wide variation in the usability rates of these perforators as recipients.^[17]

Marking the perforator(s) helps caution the resecting oncosurgeon to limit the use of cautery dissection in the region of the perforators, thereby protecting them from being accidentally injured during the mastectomy. In the uncommon instance that these perforator vessels cannot be identified or are unsuitable for use, the reconstructive surgeon has the option to proceed to dissect out the parent IMV for use as recipient.

Multiple authors have now reported their experience with the IMPV as recipient and what is consistent across these reports is the safety and feasibility when using these vessels.^[15,16,18,19]

A concern that has not been adequately addressed in previous studies and that bears vital importance from an oncological safety point of view is the adequacy of oncological clearance when the IMPV are preserved. These perforators pass through the breast substance on their way to supply the skin. Preservation of these perforators for their use as recipients may be associated with incomplete excision of breast tissue, especially perivascularly. Hence, breast cancers involving the upper, inner quadrant preclude the use of these perforators as recipients in free tissue breast reconstructions. While no mention has been made regarding increased rates of cancer recurrence when the IMPVs have been used as recipients, long-term follow-up studies are desired to put this issue to rest.

As a consequence of intraoperative transection during mastectomy or following destruction during adjuvant radiotherapy, these perforators are generally not available as recipient vessels in delayed breast reconstruction. Although both Munhoz *et al.*^[18] and Follmar *et al.*^[11] did not find suitable IMPV in the late reconstruction group, Halim and Alwi were able to use the IMPVs as recipient in 8% of their patients.^[17]

CONCLUSION

The aim of our study was not to compare the IMPVs with standard recipient vessels such as the thoracodorsal pedicle or the IMV. Rather, we attempted to determine the anatomical consistency and reliability of using the IMPVs as a recipient in free flap breast reconstruction. Our study was limited by a small clinical sample size. Nonetheless, based on our CTA findings, we determine that these perforators are anatomically dependable.

While CTA can indicate dominant perforator status, we recommend the use of HHD as a cost-effective, safe, technically simple and widely available tool to map the IMPVs preoperatively. Finally, though these perforators may be anatomically present in a given patient, whether they will be used as recipients for free tissue breast reconstruction will eventually depend on their location, preservation during mastectomy by the resecting surgeon, successful dissection of these vessels, their diameters and the comfort level of the operating surgeon. The IMPV does, however, offer a viable alternative in the choice of recipient vessels for free flap breast reconstruction.

Financial support and sponsorship

Nil.

Conflicts of interest

There are no conflicts of interest.

REFERENCES

1. Saint-Cyr M, Youssef A, Bae HW, Robb GL, Chang DW. Changing trends in recipient vessel selection for microvascular autologous breast reconstruction: An analysis of 1483 consecutive cases. *Plast Reconstr Surg* 2007;119:1993-2000.
2. Moran SL, Nava G, Behnam AB, Serletti JM. An outcome analysis comparing the thoracodorsal and internal mammary vessels as recipient sites for microvascular breast reconstruction: A prospective study of 100 patients. *Plast Reconstr Surg* 2003;111:1876-82.
3. Dupin CL, Allen RJ, Glass CA, Bunch R. The internal mammary artery and vein as a recipient site for free-flap breast reconstruction: A report of 110 consecutive cases. *Plast Reconstr Surg* 1996;98:685-9.
4. Feng LJ. Recipient vessels in free-flap breast reconstruction: A study of the internal mammary and thoracodorsal vessels. *Plast Reconstr Surg* 1997;99:405-16.
5. Lantieri LA, Mitrofanoff M, Rimareix F, Gaston E, Raulo Y, Baruch JP. Use of circumflex scapular vessels as a recipient pedicle for autologous breast reconstruction: A report of 40 consecutive cases. *Plast Reconstr Surg* 1999;104:2049-53.
6. Taylor GI, Palmer JH. The vascular territories (angiosomes) of the body: Experimental study and clinical applications. *Br J Plast Surg* 1987;40:113-41.
7. Bakamjian VY, Long M, Rigg B. Experience with the medially based deltopectoral flap in reconstructive surgery of the head and neck. *Br J Plast Surg* 1971;24:174-83.
8. Blondeel PH. Perforator Flaps in Breast Reconstruction (Panel) Presented at Third International Course on Perforator Flaps in FIZ, Munich, Germany; 12-14 November, 1999.
9. Guzzetti T, Thione A. Successful breast reconstruction with a perforator to deep inferior epigastric perforator flap. *Ann Plast Surg* 2001;46:641-3.
10. Hamdi M, Blondeel P, Van Landuyt K, Monstrey S. Algorithm in choosing recipient vessels for perforator free flap in breast reconstruction: The role of the internal mammary perforators. *Br J Plast Surg* 2004;57:258-65.
11. Follmar KE, Prucz RB, Manahan MA, Magarakis M, Rad AN, Rosson GD. Internal mammary intercostal perforators instead of

- the true internal mammary vessels as the recipient vessels for breast reconstruction. *Plast Reconstr Surg* 2011;127:34-40.
12. Schellekens PP, Paes EC, Hage JJ, van der Wal MB, Bleys RL, Kon M. Anatomy of the vascular pedicle of the internal mammary artery perforator (IMAP) flap as applied for head and neck reconstruction. *J Plast Reconstr Aesthet Surg* 2011;64:53-7.
 13. Schmidt M, Aszmann OC, Beck H, Frey M. The anatomic basis of the internal mammary artery perforator flap: A cadaver study. *J Plast Reconstr Aesthet Surg* 2010;63:191-6.
 14. Kim H, Lim SY, Pyon JK, Bang SI, Oh KS, Mun GH. Preoperative computed tomographic angiography of both donor and recipient sites for microsurgical breast reconstruction. *Plast Reconstr Surg* 2012;130:11e-20.
 15. Saint-Cyr M, Chang DW, Robb GL, Chevray PM. Internal mammary perforator recipient vessels for breast reconstruction using free TRAM, DIEP, and SIEA flaps. *Plast Reconstr Surg* 2007;120:1769-73.
 16. Haywood RM, Raurell A, Perks AG, Sassoon EM, Logan AM, Phillips J. Autologous free tissue breast reconstruction using the internal mammary perforators as recipient vessels. *Br J Plast Surg* 2003;56:689-91.
 17. Halim AS, Alwi AA. Internal mammary perforators as recipient vessels for deep inferior epigastric perforator and muscle-sparing free transverse rectus abdominis musculocutaneous flap breast reconstruction in an Asian population. *Ann Plast Surg* 2014;73:170-3.
 18. Munhoz AM, Ishida LH, Montag E, Sturtz GP, Saito FL, Rodrigues L, *et al.* Perforator flap breast reconstruction using internal mammary perforator branches as a recipient site: An anatomical and clinical analysis. *Plast Reconstr Surg* 2004;114:62-8.
 19. Park MC, Lee JH, Chung J, Lee SH. Use of internal mammary vessel perforator as a recipient vessel for free TRAM breast reconstruction. *Ann Plast Surg* 2003;50:132-7.