

## Ideas and Innovation

# Two new clinical tests for palmaris longus

**Ravindra Mohan Shenoy**

Department of Orthopaedics, Yenepoya Medical College, Mangalore, Karnataka, India

**Address for correspondence:** Dr. Ravindra Mohan Shenoy, Head of the Department of Orthopaedics, Yenepoya Medical College, Mangalore - 575 018, Karnataka, India. E-mail: rmshenoy55@gmail.com

### ABSTRACT

The palmaris longus (PL) tendon can be assessed with clinical tests whose reliability varies. Herewith, two new tests are described – the ‘Bunched Finger’ test and ‘Hooked Finger test’ that are simple and visualise the PL tendon easily and prominently.

### KEY WORDS

Clinical; palmaris longus; tendons; tests

### INTRODUCTION

There is a wide variation in the reported absence of palmaris longus (PL) among different study populations ranging from 0% to 63%.<sup>[1,2]</sup> In addition to its high presence in most populations, its superficial location makes it a favoured donor for tendon and joint reconstructive surgeries.<sup>[3]</sup> PL is also a suitable donor in all age groups because it is completely developed at birth whereas the fascia lata, the other commonly used donor, is not well developed at birth.<sup>[4]</sup> PL is commonly clinically assessed by the Standard test also known as Schaffer’s test which includes opposition of the thumb to the little finger, while flexing the wrist against resistance.<sup>[5]</sup> Other tests include Thompson’s test,<sup>[6]</sup> Mishra’s tests (1 and 2)<sup>[7]</sup> and Pushpakumar’s methods (1 and 2).<sup>[8]</sup>

All the tests are based on making the tendon taut by eliciting its weak flexor action and making it prominent, leading to its identification by vision and/or palpation. It

has been the author’s experience in over three decades of clinical practice that each of the tests has some degree of complexity which affects their performance as well as reproducibility and reliability. Herewith, described are two new tests which are relatively easy to perform with distinct advantages.

### Description of two new tests

#### *Bunched finger test*

The participants are asked to place their hand flat on the table with the palm facing upwards. They are then asked to bunch their fingers (as if preparing them for smothering the forehead) and exert firm pressure at the opposing finger tips. This fixes the distal portion of the PL musculotendinous unit. Next, they are asked to flex the wrist which makes the tendon to stand out prominently [Figure 1a]. At this point of time, if they are asked to pronate the forearm to about 5°–10°, the tendon is seen even more prominently [Figure 1b].

This is an open access journal, and articles are distributed under the terms of the Creative Commons Attribution-NonCommercial-ShareAlike 4.0 License, which allows others to remix, tweak, and build upon the work non-commercially, as long as appropriate credit is given and the new creations are licensed under the identical terms.

**For reprints contact:** reprints@medknow.com

**How to cite this article:** Shenoy RM. Two new clinical tests for palmaris longus. Indian J Plast Surg 2018;51:321-3.

Access this article online	
Quick Response Code: 	Website: www.ijps.org
	DOI: 10.4103/ijps.IJPS_105_18

**Hooked finger test**

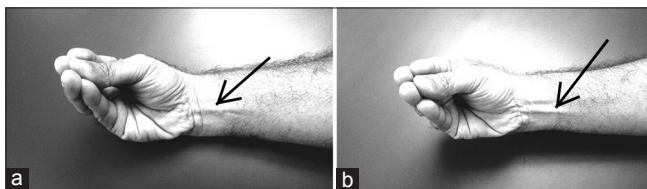
The participants are asked to stretch out their arm and then hook their fingers. The examiner then hooks the fingers of his hand and then locks his fingers into the hooked fingers of the patient. The patients are then asked to flex their wrist while the examiner gives resistance. This makes the PL tendon stand out prominently [Figure 2].

**DISCUSSION**

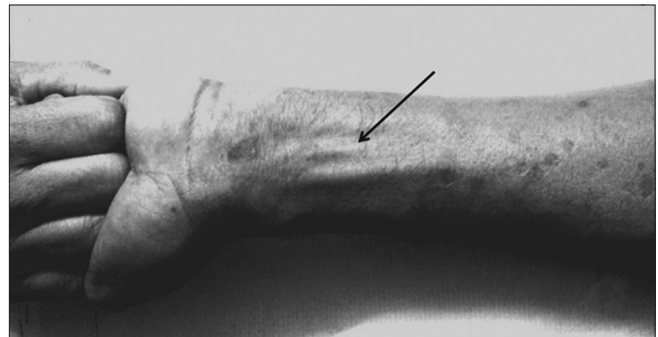
Several tests have been described in the literature for the demonstration of PL. The five common tests/methods that are commonly employed are Schaeffer's test,<sup>[9]</sup>

Thompson's test, Mishra's tests (1 and 2) and Pushpakumar's two-finger sign test [Figures 3-7].

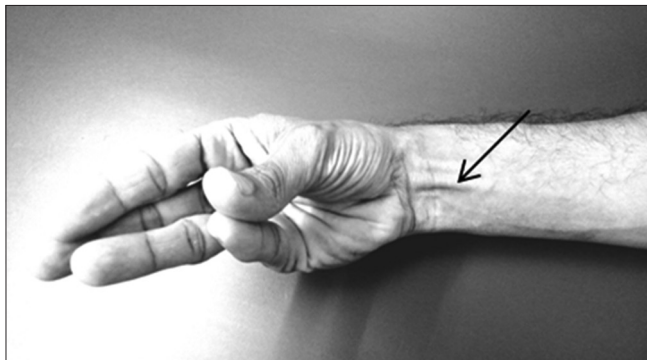
Demonstration of the PL by magnetic resonance imaging (MRI) is an expensive proposition and not practical for routine application. Hence, many surgeons employ clinical tests. All of the previously described clinical tests except Mishra's test 1<sup>[7]</sup> require the patient to flex the fingers and/or the wrist. This commonly leads to a prominence of the flexor carpi radialis in most cases and flexor digitorum superficialis in some cases in addition to



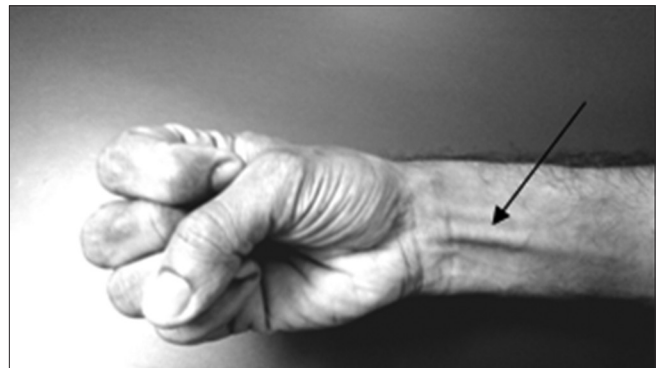
**Figure 1:** (a) Bunched finger test: Prominent tendon of palmaris longus (arrow) when fingers are bunched, opposed to each other, and the wrist is flexed. (b) Increased prominence of the palmaris longus tendon (arrow) when the forearm is pronated by 5° from the former position



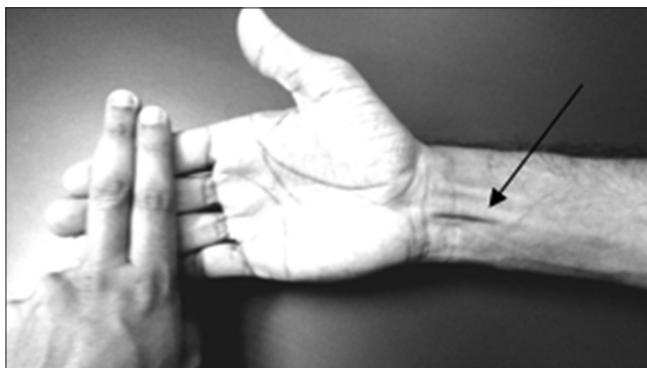
**Figure 2:** Hooked finger test: Prominence of the palmaris longus tendon (arrow) in a patient with lost thumb. The examiner's hooked fingers are locked with the hooked fingers of the patient and giving resistance with the patient attempting wrist flexion



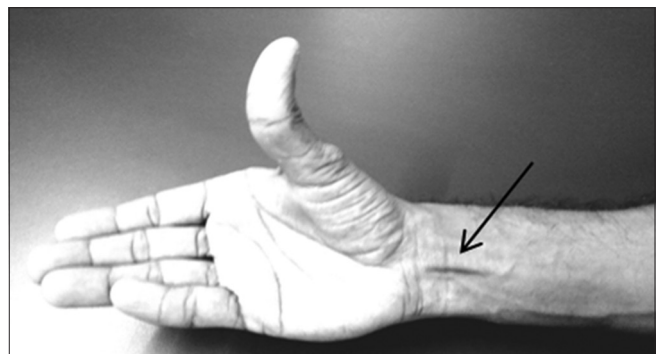
**Figure 3:** Schaeffer's test/Standard test:<sup>[5]</sup> The patient is asked to oppose the thumb to the little finger and then flex the wrist, resulting in palmaris longus prominence (arrow)



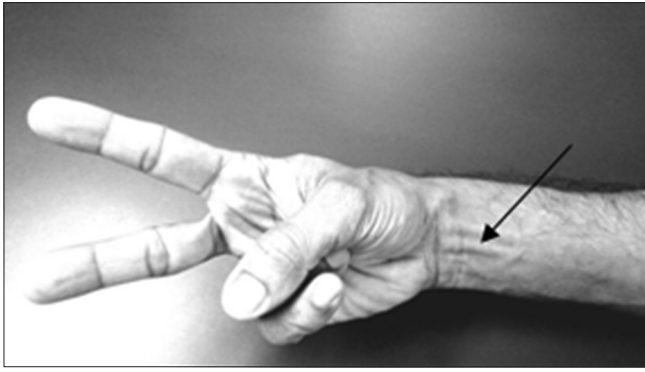
**Figure 4:** Thompson's test<sup>[6]</sup> showing the patient making a fist, flexing the wrist and finally opposing the thumb over the flexed fingers, reaching the little finger to make the tendon of palmaris longus prominent (arrow)



**Figure 5:** Mishra's test-1:<sup>[7]</sup> Passive hyperextension of the metacarpophalangeal joint by the examiner while the patient actively flexes the wrist, which makes the tendon of palmaris longus prominent (arrow)



**Figure 6:** Mishra's test-2:<sup>[7]</sup> The tendon of palmaris longus stands out prominently (arrow) when the thumb is fully abducted with the wrist in slight flexion



**Figure 7:** Pushpakumar's "two-finger sign" method<sup>[8]</sup> showing the prominent palmaris longus tendon (arrow) with extension of lateral two fingers, flexion of medial two fingers, the wrist and opposition of the thumb over flexed fingers

the PL. The prominence of these tendons can be confused with the PL. A disadvantage that is common to all the above tests is that all of them depend on abduction and rolling movement of the thumb for making the PL prominent. These tests are, therefore, of little value if the patient cannot abduct his thumb, for example, median nerve injury and paralysis of the thenar muscles or when the thumb is absent.<sup>[10]</sup> They are also based on somewhat complex movements which patients may find difficult to carry out. Especially in Claw hand where it is difficult to perform all other tests except hooked finger test.

The novel tests that have been described here are designed on the principle of locking the fingers in opposition or by hooking, thereby limiting the action of the long flexors of the fingers. The manoeuvre stabilises the distal anchorage and extension slips of the PL tendon to the palmar fascia and the thenar muscles. The PL tendon is then made to contract by actively flexing the wrist. These tests are also more easily understood by the patients. In my practice, the results have been encouraging and

I wish to share this information with my colleagues through this publication. I do acknowledge that this lacks validation by absolute techniques of PL detection such as ultrasound or MRI which may be performed in the future by an unbiased observer.

#### **Financial support and sponsorship**

Nil.

#### **Conflicts of interest**

There are no conflicts of interest.

#### **REFERENCES**

1. Machado AB, DiDio LJ. Frequency of the Musculus palmaris longus studied *in vivo* in some amazon Indians. *Am J Phys Anthropol* 1967;27:11-20.
2. Reimann AF, Daseler EH, Anson BJ, Beaton LE. The palmaris longus muscle and tendon. A study of 1600 extremities. *Anat Rec* 1944;89:495-505.
3. Lee M. Campbell's Operative Orthopaedics. In: Tendon Injuries. St. Louis: C.V. Mosby; 1987. p. 175.
4. Jordan R, Anderson RL. Obtaining fascia lata. *Arch Ophthalmol* 1987;105:139-40.
5. Wolfe SW, Hotchkiss RN, Pederson WC, Kozin SH. Flexor Tendon Injury. *Greens Operative Hand Surgery*. 6<sup>th</sup> ed. Ch. 7. Philadelphia, PA, USA: Churchill Livingstone; 2011.; P 228.
6. Thompson JW, McBatts J, Danforth CH. Hereditary and racial variations in the *Musculus palmaris longus*. *Am J Phys Anthropol* 1921;4:205-20.
7. Mishra S. Alternative tests in demonstrating the presence of palmaris longus. *Indian J Plast Surg* 2001;34:12.
8. Pushpakumar SB, Hanson RP, Carroll S. The 'two finger' sign. Clinical examination of palmaris longus (PL) tendon. *Br J Plast Surg* 2004;57:184-5.
9. Schaeffer JP. On the variations of the palmaris longus muscle. *Anat Rec* 1909;3:275-8.
10. Sebastin SJ, Lim AY. Clinical assessment of absence of the palmaris longus and its association with other anatomical anomalies- a Chinese population study. *Ann Acad Med Singapore* 2006;35:249-53.