

## An Unusual Site and Presentation of Sarcoma

A 60-year-old woman presented with multiple bilateral cervical lymphadenopathy, unexplained fever, and weight loss. Hemogram revealed normal complete blood count with hemoglobin 12.8 g/dL, leukocytes 7000/mm<sup>3</sup>, and platelets 2 lakhs/mm<sup>3</sup>. Lactate dehydrogenase was 1200 IU/L and uric acid was 8 mg/dL. Contrast-enhanced computed tomography of the head and neck and chest showed no significant abnormality. Ultrasonography of the abdomen was normal. Fine-needle aspiration of the node was done, and smear showed singly scattered cells with scant cytoplasm and irregular nuclear contour and conspicuous nucleoli. The diagnosis of lymphoma was rendered. Excision biopsy of the node was done. Microscopically, lymph node architecture was completely replaced by tumor cells. The cells were small with little cytoplasm and arranged in alveolar spaces. The sheets of cells were separated by fibrous septae and cells adhered to the periphery of alveoli. Mitosis was brisk [Figure 1].

On immunohistochemistry (IHC), tumor cell was positive for desmin and myogenin and negative for CD45 and CD20. The final diagnosis of alveolar rhabdomyosarcoma (RMS)-lymphadenopathic form was given. It is the most common malignant soft-tissue tumor of childhood, but rare in adulthood, occurring in fewer than 5%. The lymphadenopathic form of alveolar RMS shows lymph node involvement as the first clinical manifestation in the absence of recognizable primary tumor. Differential diagnosis of small, round blue cell tumor should be considered and excluded by morphology and IHC.

### Declaration of patient consent

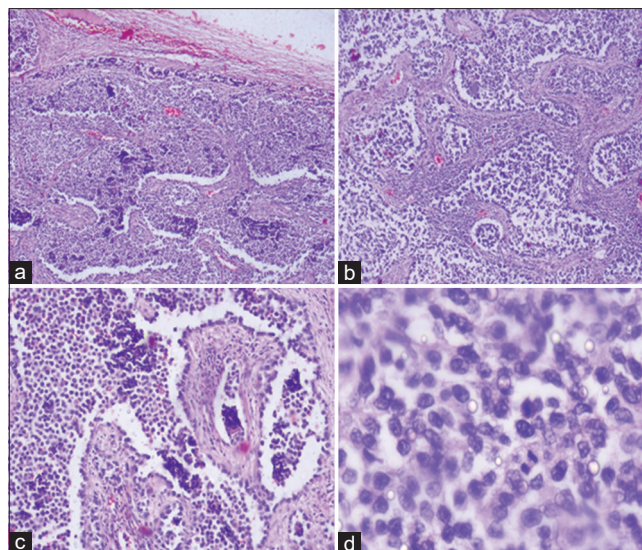
The authors certify that they have obtained all appropriate patient consent forms. In the form the patient(s) has/have given his/her/their consent for his/her/their images and other clinical information to be reported in the journal. The patients understand that their names and initials will not be published and due efforts will be made to conceal their identity, but anonymity cannot be guaranteed.

### Financial support and sponsorship

Nil.

### Conflicts of interest

There are no conflicts of interest.



**Figure 1:** (a-d) Neoplastic cells arranged in alveolar spaces separated by fibrous septae. The cells are small with scant cytoplasm and are adhering to the periphery of alveoli. Mitosis is brisk. (a = H and E,  $\times 4$ ; b = H and E,  $\times 10$ ; c = H and E,  $\times 20$ ; d = H and E,  $\times 40$ )

**Lakshmi Agarwal<sup>1</sup>, Manmohan Agrawal<sup>2</sup>,  
Sanjay Gandhi<sup>3</sup>**

<sup>1</sup>Department of Pathology, Government Medical College, Kota, Rajasthan, India, <sup>2</sup>Department of Oncosurgery, Pushpadi Cancer Care Centre, Kota, Rajasthan, India, <sup>3</sup>Department of Pathology, Vhistoplus Diagnostic Centre, Ahmedabad, Gujarat, India

*Address for correspondence:* Dr. Lakshmi Agarwal, Government Medical College, Kota, Rajasthan, India.  
E-mail: drlaxmiagarwal@gmail.com

**Submitted:** 10-Feb-2020

**Accepted in Revised Form:** 13-Feb-2020

**Published:** 24-Apr-2020

This is an open access journal, and articles are distributed under the terms of the Creative Commons Attribution-NonCommercial-ShareAlike 4.0 License, which allows others to remix, tweak, and build upon the work non-commercially, as long as appropriate credit is given and the new creations are licensed under the identical terms.

### Access this article online

#### Quick Response Code:



#### Website:

www.ijmpo.org

#### DOI:

10.4103/ijmpo.ijmpo\_52\_20

**How to cite this article:** Agarwal L, Agrawal M, Gandhi S. An unusual site and presentation of sarcoma. Indian J Med Paediatr Oncol 2020;41:66.