

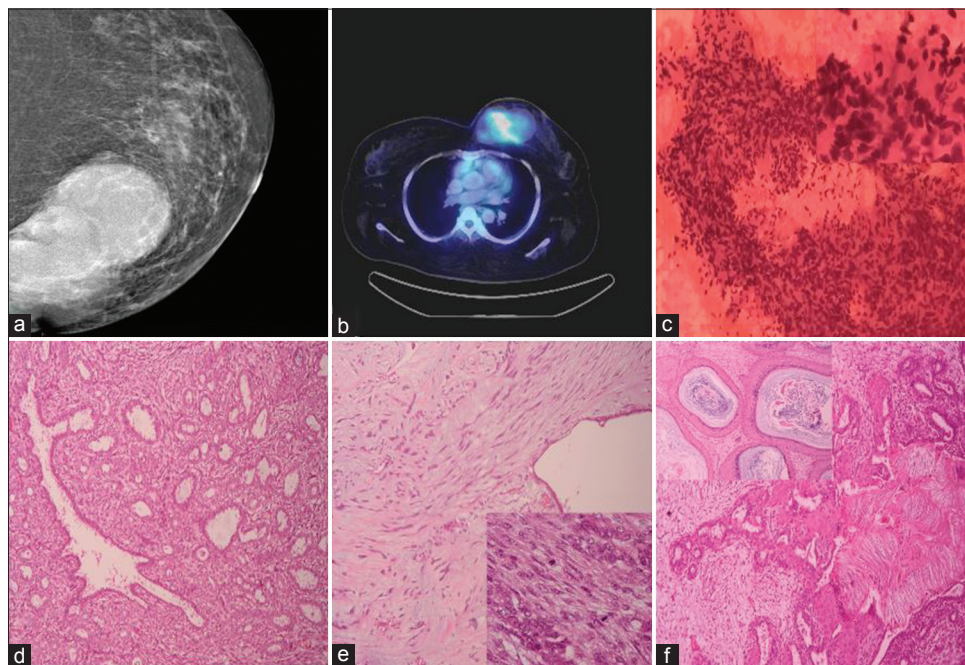
## Borderline Phyllodes Tumor Arising in a Complex Fibroadenoma with Extensive Squamous Metaplasia: A Complex Pathological Presentation

Sir,  
Phyllodes tumor, a biphasic fibroepithelial tumor of the breast, arises *de novo* or rarely from a preexisting fibroadenoma. Progression in phyllodes tumor is due to the crosstalk between epithelium and stroma, through signaling pathways and upregulation of certain genes.<sup>[1]</sup> Metaplasia of the stromal component is commonly seen but of the epithelial component is rare. We report a case of phyllodes tumor with borderline features, arising from a complex fibroadenoma and coexistent metaplastic changes in the duct epithelium with keratin cyst formation.

We present the case of a 38-year-old female with a huge lump in the left breast for 6 years with increase in size for the last 6 months. She was evaluated with mammogram, which showed a hyperdense lesion with macrolobulated margins of size 10 cm × 6.5 cm [Figure 1a]. Positron emission tomography-computed tomography done showed intensely hypermetabolic heterogeneously enhancing mass lesion in the left breast and no evidence of metastasis [Figure 1b]. Fine-needle aspiration cytology from the mass revealed epithelial cell clusters, and stromal fragments [Figure 1c]. The stromal components were cellular with mild cellular atypia, suspicious of fibroepithelial neoplasm. Trucut biopsy was done and revealed prominent stromal component with focal

nuclear atypia, myxoid areas, and hyalinization. Ductal epithelial component was seen with mild hyperplasia. With the provisional diagnosis of phyllodes tumor, simple mastectomy was done. Gross examination of the specimen showed a 10 cm firm whitish mass with whitish granular areas. Histologically, the tumor was heterogeneous with nodular proliferation of ductal component with apocrine change and decapitating secretions, myoepithelial hyperplasia, with fibromyxoid stroma amidst simulating fibroadenoma [Figure 1d], areas with stromal predominance occupying more than a low power field [Figure 1e] with increased mitosis (8/10 High Power Field), atypia, and cellularity [Figure 1e, inset], simulating phyllodes tumor. Extensive squamous metaplasia of the duct epithelium and cystic spaces containing keratin flakes [Figure 1f] were present. Hence, a diagnosis of borderline phyllodes tumor arising in a complex fibroadenoma with extensive squamous metaplasia was made.

Phyllodes tumor, a relatively uncommon fibroepithelial neoplasm, arises from the intralobar stroma of breast.<sup>[1]</sup> Clinically, patients present with large mobile rapidly growing mass and asymmetry. It is classified into benign, borderline, and malignant based on infiltrative margins, stromal overgrowth, cellularity, atypia,



**Figure 1:** (a) Large lobulated mass in mammogram (b) positron emission tomography-computed tomography showing intensely hypermetabolic breast mass (c) aspirate showing cellular stromal fragments (H and E, ×100), inset showing nuclear atypia of the spindle stromal cells (×400) (d) fibroadenoma areas with myoepithelial prominence, dilated duct, and fibromyxoid stroma (H and E, ×100) (e) phyllodes tumor with stromal predominance (H and E, ×100), inset showing cellular areas with two mitosis (H and E, ×400) (f) squamous metaplasia of the duct epithelium, with inset showing keratin cysts (H and E, ×100)

and mitosis.<sup>[1]</sup> Histologically, stromal predominance, periductal condensation, and cleft like glandular spaces are characteristics of phyllodes tumor. Metaplastic changes are known to occur with phyllodes tumor and can occur with both epithelial and stromal components.<sup>[1]</sup> However, extensive squamous metaplasia of the duct epithelium, with the formation of keratin cysts, is uncommon and pose diagnostic challenge in cytology aspirate smears and core biopsy.<sup>[2,3]</sup> It has been suggested that squamous metaplasia begins from the myoepithelial layer and eventually involves the entire acinus. This was supported by immunohistochemical studies, with expression of myoepithelial markers such as actin, cytokeratin 5/6, S-100, and vimentin in the metaplastic squamous cells.<sup>[3,4]</sup>

Further, phyllodes tumor can coexist with fibroadenoma synchronously, or as a progression from fibroadenoma, as supported by clonality studies revealing monoclonality in the areas of stromal expansion indicating stromal progression.<sup>[5]</sup> Clonality studies by Noguchi *et al.* suggested the presence of two types of fibroadenoma, polyclonal and monoclonal. Polyclonal type of fibroadenoma can become monoclonal due to mutation in the stromal cells. Monoclonal fibroadenoma has more tendency to recur and can transform to phyllodes tumor. Further, it was suggested that these tumors are clonally related and allelic loss at TP53 may be implicated in the transformation of fibroadenoma to phyllodes tumor.<sup>[6]</sup> Our case would have had a monoclonal type of fibroadenoma which progressed to phyllodes tumor with borderline features and in addition had extensive squamous metaplasia.

### Financial support and sponsorship

Nil.

### Conflicts of interest

There are no conflicts of interest.

### Rajeshwari K Muthusamy, Sangita S Mehta

Department of Pathology, Kovai Medical Center and Hospital,  
Coimbatore, Tamil Nadu, India

### Address for correspondence:

Dr. Rajeshwari K Muthusamy,  
Department of Pathology, Kovai Medical Center and Hospital,  
Coimbatore - 641 014, Tamil Nadu, India.  
E-mail: drrajipranav@gmail.com

### References

1. Tan PH, Simpson JF, Tse G, Hanby AM, Lee A. Fibroepithelial tumours. In: Lakhani SR, Ellis IO, Schnitt SJ, Tan PH, Vande Vijver MJ, editors. WHO Classification of Tumours of the Breast. 4<sup>th</sup> ed. Lyon: IARC; 2012. p. 142-7.
2. Agarwal J, Kapila K, Verma K. Phyllodes tumor with keratin cysts: A diagnostic problem in fine needle aspiration of the breast. *Acta Cytol* 1991;35:255-6.
3. Devi PM, Singh LR, Gatphoh ED. Fibroadenoma with squamous metaplasia. *Singapore Med J* 2007;48:682-3.
4. Kumar H, Iqbal MB, Buch A, Panicker N. Extensive squamous metaplasia in a benign phyllodes tumor: A rare case report. *Med J DY Patil Univ* 2015;8:404-6.
5. Kuijper A, Buerger H, Simon R, Schaefer KL, Croonen A, Boecker W, *et al.* Analysis of the progression of fibroepithelial tumours of the breast by PCR-based clonality assay. *J Pathol* 2002;197:575-81.
6. Noguchi S, Yokouchi H, Aihara T, Motomura K, Inaji H, Imaoka S, *et al.* Progression of fibroadenoma to phyllodes tumor demonstrated by clonal analysis. *Cancer* 1995;76:1779-85.

This is an open access article distributed under the terms of the Creative Commons Attribution-NonCommercial-ShareAlike 3.0 License, which allows others to remix, tweak, and build upon the work non-commercially, as long as the author is credited and the new creations are licensed under the identical terms.

Access this article online	
<b>Quick Response Code:</b> 	<b>Website:</b> <a href="http://www.ijmpo.org">www.ijmpo.org</a>
	<b>DOI:</b> 10.4103/ijmpo.ijmpo_46_17

**How to cite this article:** Muthusamy RK, Mehta SS. Borderline phyllodes tumor arising in a complex fibroadenoma with extensive squamous metaplasia: A complex pathological presentation. *Indian J Med Paediatr Oncol* 2018;39:266-7.

© 2017 Indian Journal of Medical and Paediatric Oncology | Published by Wolters Kluwer - Medknow